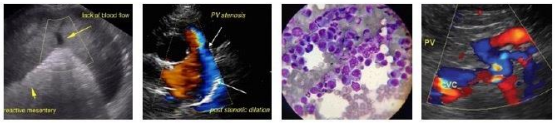

PATIENT
Oliver Connel

SPECIES
Canine

BREED
Cockapoo

SEX
MN

AGE
11 years

WEIGHT
10.7 kg

INTERPRETED BY
R. McKenzie Daniel, DVM, DABVP

IMAGING PERFORMED BY
Kelly Reschny

HOSPITAL NAME
Nelson AH

REFERRING VET
Manjos

INVOICE
14826

DATE
9/7/22

PRESENTING CLINICAL SIGNS

-new gr 4/6 R systolic murmur heard at recent visit, no clinical signs, progressive weight loss since Oct last year.
Abnormal PE/Chem/CBC/UA Results: BW-WNL

ULTRASONOGRAPHIC EXAMINATION OF THE ABDOMEN

Urinary System

The urinary bladder presented uniformly mild thickened urinary bladder wall isoechoic to the adjacent normal urinary bladder wall. The luminal margin of the thickened urinary bladder wall was mildly asymmetrical in contour. Solitary, small, dependent calculus measuring 0.68 cm was present. The urinary bladder, trigone, cystourethral junction, and visible pelvic urethra exhibited normal tone. Anechoic urine was present in the lumen with no uroliths or sediment. The ureteral papillae were normal. The ureters were not visible which is normal. The ventroapical urinary bladder wall measured 0.55 cm width.

The area of the aortic trifurcation was free of pathology.

Normal size and margination were present in the kidneys. A normal 1:3 cortex / medulla ratio was maintained. The medulla and cortices were uniform in texture with some increased echogenicity and mild loss of corticomedullary symmetry and definition expected for the age of the patient. No evidence of pelvic dilation was present. The left kidney measured 4.9 cm in length. The right kidney measured 4.6 cm in length.

Adrenal Glands

The left adrenal gland was uniform in size and contour with a uniformly hypoechoic parenchyma. The left adrenal gland measured 2.0 cm length x 0.48 cm width at the caudal pole. The right adrenal gland was uniform in size and contour with a uniformly hypoechoic parenchyma. The right adrenal gland measured 1.7 cm length x 0.81 cm width at the caudal pole. No evidence of adrenomegaly or adrenal tumors was noted.

Spleen

The spleen exhibited primarily finely textured parenchyma which was hyperechoic to the liver and renal cortical parenchyma. Mild generalized parenchyma heterogeneity was present without evidence of nodular changes. The capsule was smooth and regular without apparent expansion. The splenic vasculature at the hilus was normal in volume with no evidence of congestion or thrombosis. The parenchymal heterogeneity is likely consistent with benign changes such as extramedullary hematopoiesis or age-related remodeling with minor potential for inflammatory or neoplastic disease.

Liver/ Gallbladder

The liver was subjectively normal in size, structure, and contour. The liver parenchyma was mildly nonuniform and hypoechoic to the spleen with a moderate coarse echotexture and subjective mild parenchymal remodeling. The hepatic and portal vasculature were normal in appearance without signs of congestion. The gallbladder was non-distended in size with mild, primarily dependent, mildly

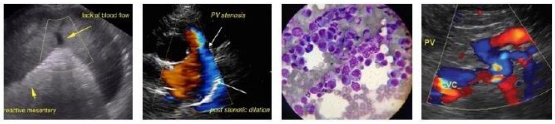

PATIENT
Oliver Connel

SPECIES
Canine

BREED
Cockapoo

SEX
MN

AGE
11 years

WEIGHT
10.7 kg

INTERPRETED BY
R. McKenzie Daniel, DVM, DABVP

IMAGING PERFORMED BY
Kelly Reschny

HOSPITAL NAME
Nelson AH

REFERRING VET
Manjos

INVOICE
14826

DATE
9/7/22

hyperechoic gallbladder debris. No evidence of gallbladder or peripheral gallbladder inflammation was noted. The cystic and common bile ducts were normal.

Gastrointestinal

The stomach presented intact wall layering with a normal wall layer ratio. The lumen of the stomach was empty with no signs of ileus, obstruction, or foreign material.

The small intestine presented intact wall layering with 1:3 muscularis/mucosa ratio. The lumen of the small intestine was empty with no signs of ileus, obstruction, or foreign material.

Normal visible colon wall layers were present with apparent formed feces in lumen.

Pancreas

The parenchyma of the left limb, body, and right limb of the pancreas presented isoechoic to the adjacent omental fat. A normal curvilinear capsule contour of the pancreas was present. The visible pancreatic duct was normal. No signs of active inflammation or neoplastic disease were evident.

Free Abdomen

No overt lymphadenopathy or peritoneal effusion was present.

ULTRASONOGRAPHIC FINDINGS

- Solitary small cystic calculus with mild apical cystitis
- Age-related renal changes
- Mild gallbladder debris (non-mucocele)
- Sonographically unremarkable gastrointestinal tract

INTERPRETATION OF THE FINDINGS & FURTHER RECOMMENDATIONS

Largely mild geriatric abdomen without evidence of significant visceral pathology as a definitive cause of the patient's weight loss.

Urine culture and sensitivity on a sterile urine sample is suggested to rule out underlying infection.

The gallbladder debris is likely incidental given the lack of hepatic enzyme elevation or cholestasis. Ursodiol therapy may be considered going forward if evidence of cholestasis arises.

A GI panel to include PLI/TLI/Cobalamin/Folate as well as three view chest radiographs and neurological / musculoskeletal examination are recommended to assess for or rule out occult disease which may cause weight loss.

SonoPath
Clinical Sonography & Telecytology
EDUCATIONAL TELECONSULTATION SERVICES™
1-800-838-4268 info@sonopath.com SonoPath.com

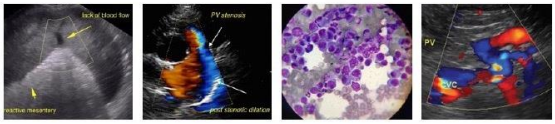

THE FOCAL ZONE
IMAGING PERFORMED BY
289-808-2608 info@thefocalzone.com

PATIENT

Oliver Connel

SPECIES

Canine

BREED

Cockapoo

SEX

MN

AGE

11 years

WEIGHT

10.7 kg

INTERPRETED BY

R. McKenzie Daniel, DVM, DABVP

IMAGING PERFORMED BY

Kelly Reschny

HOSPITAL NAME

Nelson AH

REFERRING VET

Manjos

INVOICE

14826

DATE

9/7/22

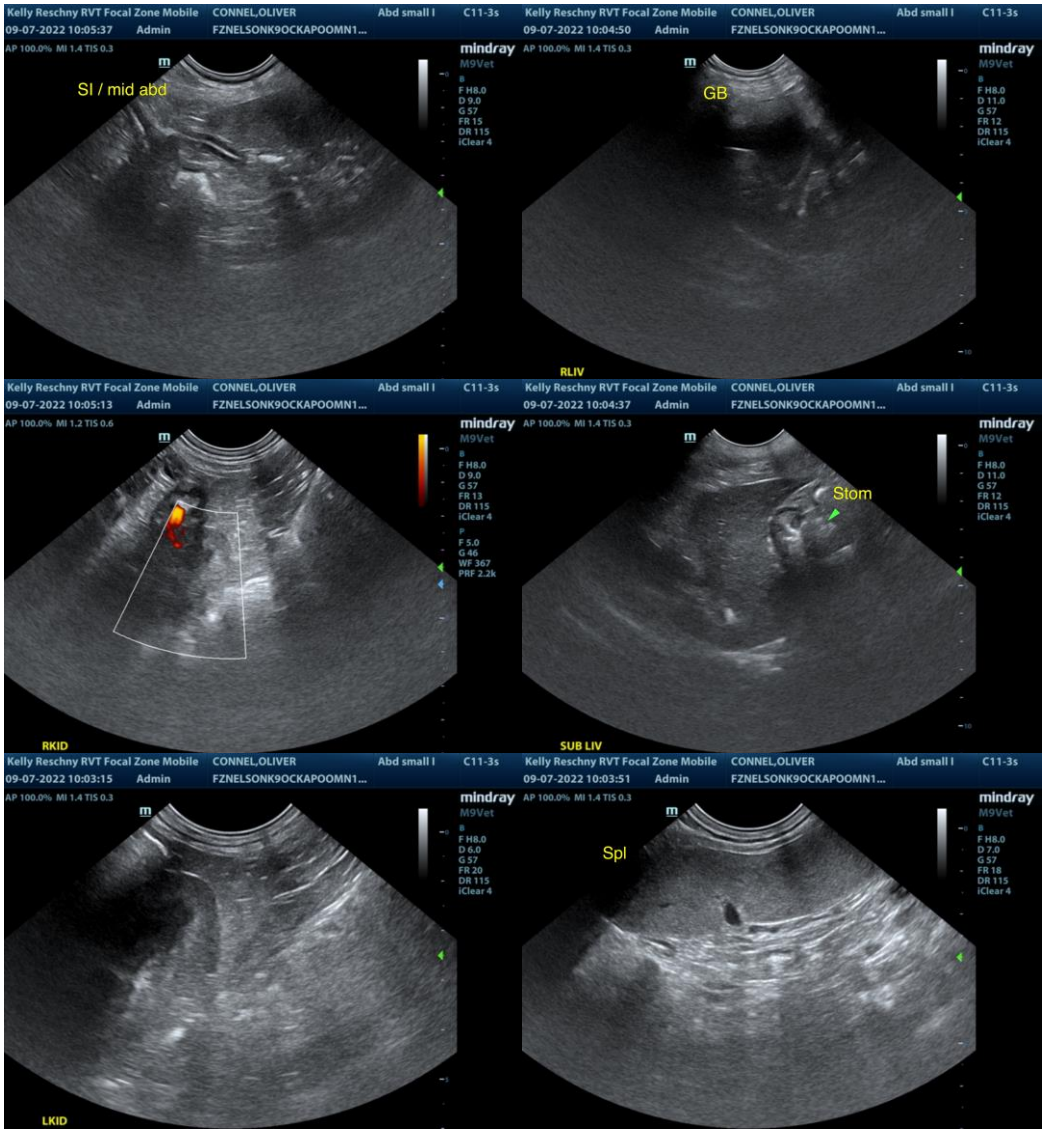

SonoPath
Clinical Sonography & Telecytology
EDUCATIONAL TELECONSULTATION SERVICES™
1-800-838-4268 info@sonopath.com SonoPath.com

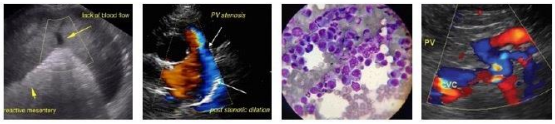

THE FOCAL ZONE
IMAGING PERFORMED BY
289-808-2608 info@thefocalzone.com

PATIENT

Oliver Connel

SPECIES

Canine

BREED

Cockapoo

SEX

MN

AGE

11 years

WEIGHT

10.7 kg

INTERPRETED BY

R. McKenzie Daniel, DVM, DABVP

IMAGING PERFORMED BY

Kelly Reschny

HOSPITAL NAME

Nelson AH

REFERRING VET

Manjos

INVOICE

14826

DATE

9/7/22

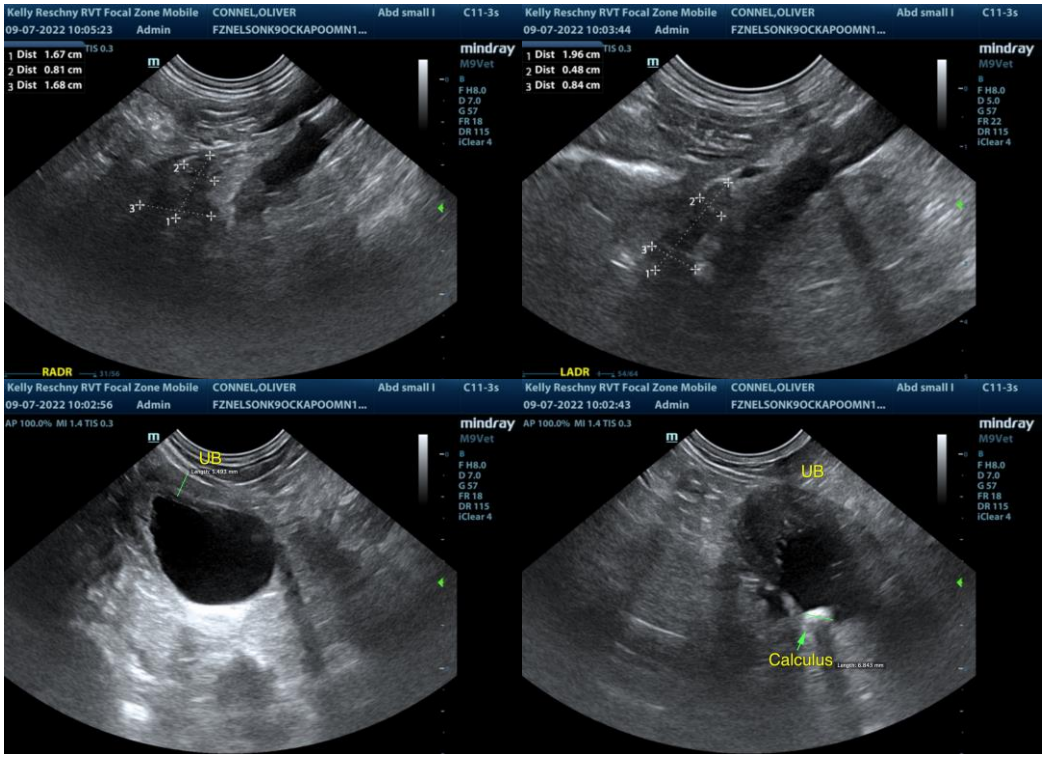

The information and recommendations provided are based on the images presented by the referring veterinarian/sonographer. No evaluation can be communicated regarding pathology that was not visible in the image/video clips provided.

Thank you for this referral. If the clinical or image interpretation does not parallel your findings or if I can be of any further assistance please contact me.

R. McKenzie Daniel, DVM, DABVP (Canine / Feline Practice)
info@SonoPath.com