

**PATIENT**

Nova Andrews

**SPECIES**

Canine

**BREED**

Golden Retriever

**SEX**

FS

**AGE**

3yr

**WEIGHT**

75 lbs.

**INTERPRETED BY**R. McKenzie Daniel,  
DVM, DABVP (Canine  
and Feline)**IMAGING  
PERFORMED BY**

Amy Mayhew LVT

**HOSPITAL NAME**SVS Imaging  
Michigan**REFERRING VET**Oxford Veterinary  
Hospital**INVOICE**

14836

**DATE**

9/7/22

**PRESENTING CLINICAL SIGNS**

-Suspicious areas on abdominal xrays after possible FB ingestion. Concerned for mass effect.  
Abnormal PE/Chem/CBC/UA Results: WNL.

**ULTRASONOGRAPHIC EXAMINATION OF THE ABDOMEN****Urinary System**

The urinary bladder, trigone, cystourethral junction, and visible pelvic urethra to a depth of 3.0 cm exhibited normal thickness and tone. Anechoic urine was present in the lumen with no uroliths or sediment. The ureteral papillae were normal. The ureters were not visible which is normal. No evidence of inflammatory or neoplastic changes was noted.

The area of the aortic trifurcation was free of pathology.

Normal size and margination were present in the kidneys. A normal 1:3 cortex / medulla ratio and normal corticomedullary definition were maintained. The echogenicity of the cortex was similar to or slightly less than normal liver parenchyma while the medulla echogenicity was hypoechoic to the cortex with no evidence of pelvic dilation. The left kidney measured 6.3 cm in length. The right kidney measured 6.9 cm in length.

**Adrenal Glands**

The left adrenal gland was uniform in size and contour with a uniformly hypoechoic parenchyma. The left adrenal gland measured 0.52 cm width at the caudal pole and 0.50 cm width at the cranial pole. The right adrenal gland was uniform in size and contour with a uniformly hypoechoic parenchyma. The right adrenal gland measured 0.46 cm width at the caudal pole and 0.54 cm width at the cranial pole.

**Spleen**

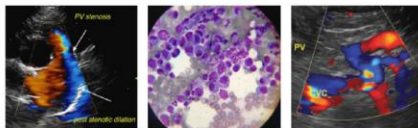
The spleen exhibited a finely textured and homogenous parenchyma which was hyperechoic to the liver and renal cortical parenchyma. The capsule was smooth and regular without apparent expansion. The splenic vasculature at the hilus was normal in volume with no evidence of congestion or thrombosis. Acute to chronic inflammatory, neoplastic, or benign parenchyma changes were not noted.

**Liver/ Gallbladder**

The liver was subjectively normal in size, structure, and contour. The liver parenchyma was uniform and hypoechoic to the spleen with a mild coarse echotexture. The hepatic and portal vasculature were normal in appearance without signs of congestion. The gallbladder was non-distended in size with thin walls and primarily anechoic luminal content. The cystic and common bile ducts were normal.

**Gastrointestinal**

The visualized gastric walls were sonographically normal. The lumen of the stomach contained moderate, ingesta exhibiting progressive distal acoustic shadowing. No obvious evidence of mechanical pyloric outflow obstruction was noted, although visualization in the area of the gastroduodenal junction was somewhat obscured by pyloric and upper duodenal luminal gas and

**PATIENT**

Nova Andrews

**SPECIES**

Canine

**BREED**

Golden Retriever

**SEX**

FS

**AGE**

3yr

**WEIGHT**

75 lbs.

**INTERPRETED BY**R. McKenzie Daniel,  
DVM, DABVP (Canine  
and Feline)**IMAGING  
PERFORMED BY**

Amy Mayhew LVT

**HOSPITAL NAME**SVS Imaging  
Michigan**REFERRING VET**Oxford Veterinary  
Hospital**INVOICE**

14836

**DATE**

9/7/22

artifact. No evidence of gastric neoplastic criteria was noted. The ventral gastric body wall width measured 0.36cm.

The small intestine presented intact wall layering with 1:3 muscularis/mucosa ratio. The lumen of the small intestine was primarily empty with segmental mild hyperechoic nonshadowing ingesta/ chyme. No evidence of an obstructive small intestinal pattern or overt foreign material was noted. The duodenum wall measured 0.56 cm width. The jejunum wall measured 0.35 cm width.

Normal visible colon wall layers were present with apparent formed feces in lumen.

***Pancreas***

The parenchyma of the left limb, body, and right limb of the pancreas presented isoechoic to the adjacent omental fat. A normal curvilinear capsule contour of the pancreas was present. The visible pancreatic duct was normal. No signs of active inflammation or neoplastic disease were evident.

***Free Abdomen***

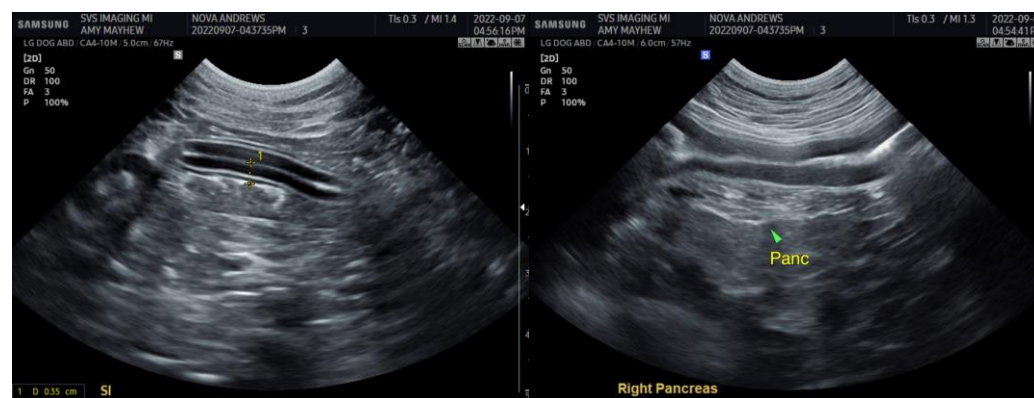
No omental masses, evidence of lymphadenopathy, or peritoneal free fluid were noted.

**ULTRASONOGRAPHIC FINDINGS**

- Moderate progressively shadowing gastric ingesta, sonographically unremarkable small bowel
- Otherwise, unremarkable abdomen

**INTERPRETATION OF THE FINDINGS & FURTHER RECOMMENDATIONS**

No evidence of overt abdominal visceral pathology, specifically no intraabdominal mass, was present. Given the small radiopaque object within the gastric ingesta present on radiographs, considerations for gastric ingesta vs. foreign material may be indicated. Sonographic monitoring of gastric emptying since the time of the ultrasound study or over the next 24 hours following a documented fast may be considered. No overt contraindications to surgery are evident if surgery is indicated or elected.





**PATIENT**

Nova Andrews

**SPECIES**

Canine

**BREED**

Golden Retriever

**SEX**

FS

**AGE**

3yr

**WEIGHT**

75 lbs.

**INTERPRETED BY**

R. McKenzie Daniel,  
DVM, DABVP (Canine  
and Feline)

**IMAGING  
PERFORMED BY**

Amy Mayhew LVT

**HOSPITAL NAME**

SVS Imaging  
Michigan

**REFERRING VET**

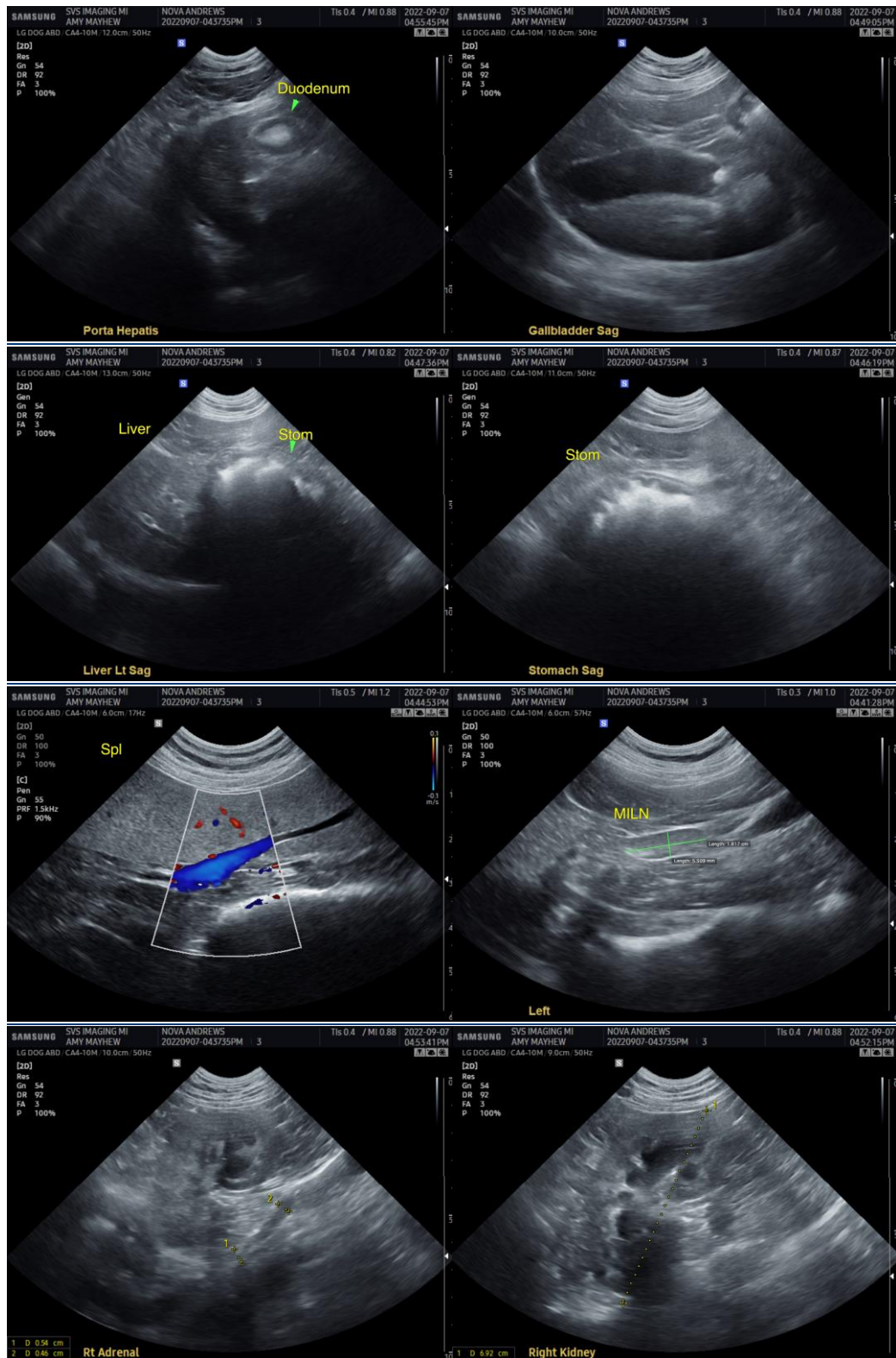
Oxford Veterinary  
Hospital

**INVOICE**

14836

**DATE**

9/7/22



**IMAGING PERFORMED BY**

SVS Mobile Imaging MI 734-637-7711  
svsimagingmi@gmail.com



**PATIENT**

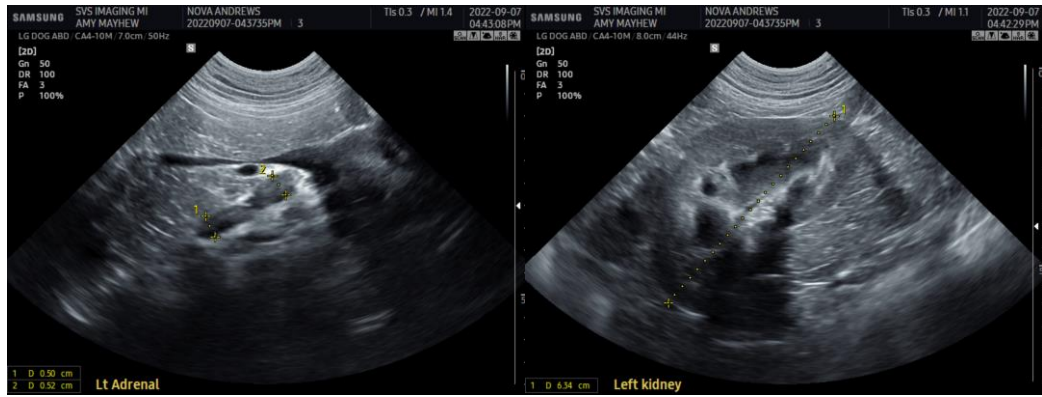
Nova Andrews

**SPECIES**

Canine

**BREED**

Golden Retriever



**SEX**

FS

**AGE**

3yr

**WEIGHT**

75 lbs.

The information and recommendations provided are based on the images presented by the referring veterinarian/sonographer. No evaluation can be communicated regarding pathology that was not visible in the image/video clips provided.

Thank you for this referral. If the clinical or image interpretation does not parallel your findings or if I can be of any further assistance please contact me.

**R. McKenzie Daniel, DVM, DABVP (Canine / Feline Practice)**  
info@SonoPath.com

**INTERPRETED BY**

R. McKenzie Daniel,  
DVM, DABVP (Canine  
and Feline)

**IMAGING PERFORMED BY**

Amy Mayhew LVT

**HOSPITAL NAME**

SVS Imaging  
Michigan

**REFERRING VET**

Oxford Veterinary  
Hospital

**INVOICE**

14836

**DATE**

9/7/22