



<b>PATIENT</b>	<b>PRESENTING CLINICAL SIGNS</b>
Bean Galbraith	-2/9 puppies from this bitch had ectopic ureters. Examine her urogenital tract to make sure no abnormalities prior to any further breedings. Exam - NAF. Only meds Simparica Trio.
<b>SPECIES</b>	Abnormal PE/Chem/CBC/UA Results: NAF
Canine	<b>ULTRASONOGRAPHIC EXAMINATION OF THE ABDOMEN</b>
<b>BREED</b>	<b>Urinary System</b>
Standard Poodle	The urinary bladder, trigone, cystourethral junction, and visible pelvic urethra to a depth of 3.0 cm exhibited normal structure and tone. No evidence of proximal urethral urine retention or dilation was noted. Anechoic urine was present in the lumen with no sediment or calculi. The ureteral papillae were normal. The ureters were not visible which is normal. No evidence of inflammatory mural changes or neoplastic changes was noted. No evidence of congenital abnormalities such as urachal remnant or overt ectopic ureter.
<b>SEX</b>	
FI	
<b>AGE</b>	
2 yr	The uterus was overtly normal for an intact female with previous litter. No evidence of uterine pathology or pyometra was noted. No evidence of pathology associated with the left or right ovary was noted.
<b>WEIGHT</b>	
22.8 kg	The area of the aortic trifurcation was free of pathology.
<b>INTERPRETED BY</b>	
R. McKenzie Daniel, DVM, DABVP	Normal size and margination were present in the kidneys. A normal 1:3 cortex / medulla ratio and normal corticomedullary definition were maintained. The echogenicity of the cortex was similar to or slightly less than normal liver parenchyma while the medulla echogenicity was hypoechoic to the cortex with no evidence of pelvic dilation. The left kidney measured 5.2 cm in length. The right kidney measured 5.4 cm in length.
<b>IMAGING PERFORMED BY</b>	<b>Adrenal Glands</b>
Crystal Hill	The left adrenal gland was uniform in size and contour with a uniformly hypoechoic parenchyma. The left adrenal gland measured 0.39 cm width at the caudal pole and 0.48 cm width at the cranial pole. The right adrenal gland was uniform in size and contour with a uniformly hypoechoic parenchyma. The right adrenal gland measured 0.47 cm width at the caudal pole and 0.72 cm width at the cranial pole.
<b>HOSPITAL NAME</b>	<b>Spleen</b>
Buck AH	The spleen exhibited a finely textured and homogenous parenchyma which was hyperechoic to the liver and renal cortical parenchyma. The capsule was smooth and regular without apparent expansion. The splenic vasculature at the hilus was normal in volume with no evidence of congestion or thrombosis. Acute to chronic inflammatory, neoplastic, or benign parenchyma changes were not noted.
<b>REFERRING VET</b>	<b>Liver/ Gallbladder</b>
Dr. Galbraith	The liver was subjectively normal in size, structure, and contour. The liver parenchyma was uniform and hypoechoic to the spleen with a mild coarse echotexture. The hepatic and portal vasculature were
<b>INVOICE</b>	
14828	
<b>DATE</b>	
9/7/22	



**PATIENT**

Bean Galbraith

normal in appearance without signs of congestion. The gallbladder was non-distended in size with thin walls and primarily anechoic luminal content. The cystic and common bile ducts were normal.

**Gastrointestinal**

**SPECIES**

Canine

The stomach presented intact wall layering with a normal wall layer ratio. The lumen of the stomach was empty with no signs of ileus, obstruction, or foreign material.

**BREED**

Standard Poodle

The small intestine presented intact wall layering with 1:3 muscularis/mucosa ratio. The lumen of the small intestine was empty with no signs of ileus, obstruction, or foreign material.

Normal visible colon wall layers were present with apparent formed feces in lumen.

**SEX**

FI

**Pancreas**

The parenchyma of the left limb, body, and right limb of the pancreas presented isoechoic to the adjacent omental fat. A normal curvilinear capsule contour of the pancreas was present. The visible pancreatic duct was normal. No signs of active inflammation or neoplastic disease were evident.

**AGE**

2 yr

**Free Abdomen**

No overt lymphadenopathy or peritoneal effusion was present.

**WEIGHT**

22.8 kg

**ULTRASONOGRAPHIC FINDINGS**

- Sonographically unremarkable urinary bladder and visible proximal urethra
- Overtly normal uterus
- Normal bilateral kidneys

**INTERPRETED BY**

R. McKenzie Daniel,  
DVM, DABVP

**INTERPRETATION OF THE FINDINGS & FURTHER RECOMMENDATIONS**

No evidence of upper or lower urinary tract pathology including no evidence of overt congenital abnormalities i.e., renal dysplasia, urachal remnant, or overt ectopic ureter. At times, small ectopic ureters may be difficult to visualize with ultrasound alone. If clinical concern for ectopic ureter or prior to further breeding, additional assessment may include contrast urography, cystoscopy, or Gold Standard CT with Contrast.

**IMAGING PERFORMED BY**

Crystal Hill

**HOSPITAL NAME**

Buck AH

**REFERRING VET**

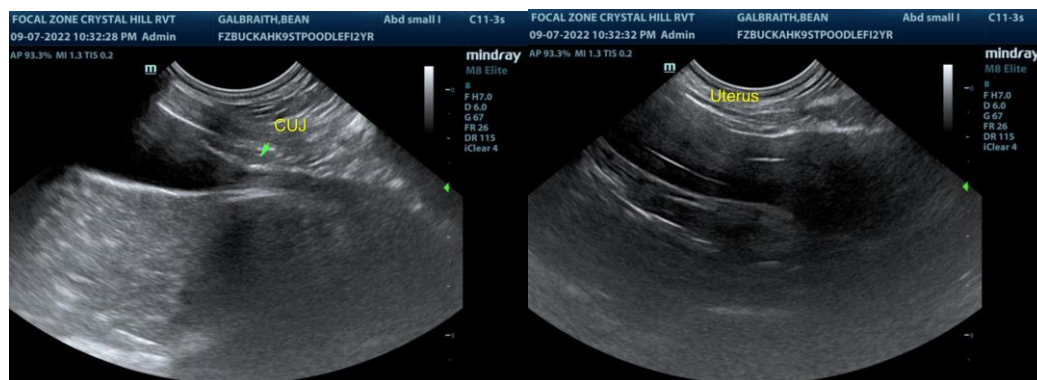
Dr. Galbraith

**INVOICE**

14828

**DATE**

9/7/22





**PATIENT**

Bean Galbraith

**SPECIES**

Canine

**BREED**

Standard Poodle

**SEX**

FI

**AGE**

2 yr

**WEIGHT**

22.8 kg

**INTERPRETED BY**

R. McKenzie Daniel,  
DVM, DABVP

**IMAGING  
PERFORMED BY**

Crystal Hill

**HOSPITAL NAME**

Buck AH

**REFERRING VET**

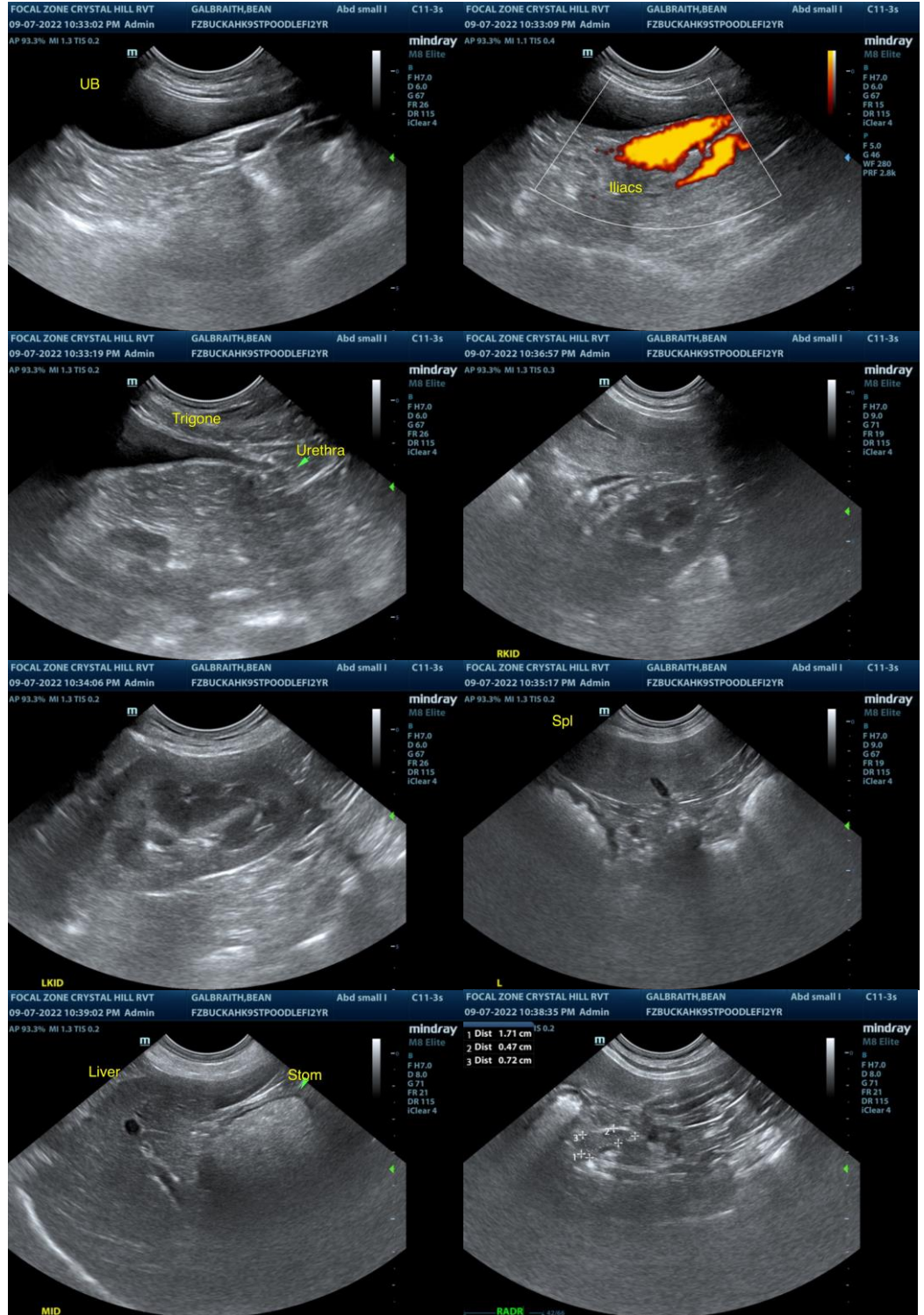
Dr. Galbraith

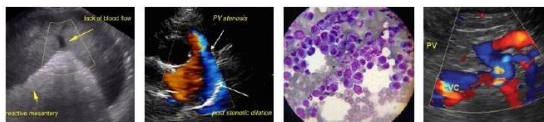
**INVOICE**

14828

**DATE**

9/7/22





**PATIENT**

Bean Galbraith

**SPECIES**

Canine

**BREED**

Standard Poodle

**SEX**

FI

**AGE**

2 yr

**WEIGHT**

22.8 kg

**INTERPRETED BY**

R. McKenzie Daniel,  
DVM, DABVP

**IMAGING  
PERFORMED BY**

Crystal Hill

**HOSPITAL NAME**

Buck AH

**REFERRING VET**

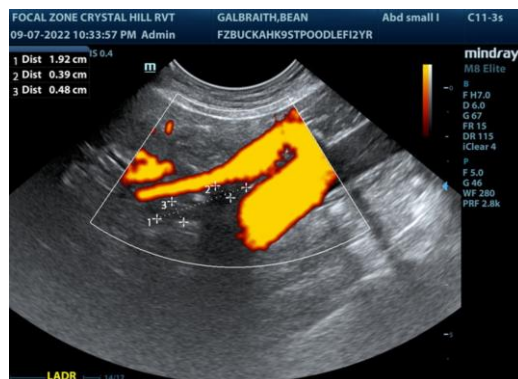Dr. Galbraith

**INVOICE**

14828

**DATE**

9/7/22



The information and recommendations provided are based on the images presented by the referring veterinarian/sonographer. No evaluation can be communicated regarding pathology that was not visible in the image/video clips provided.

Thank you for this referral. If the clinical or image interpretation does not parallel your findings or if I can be of any further assistance please contact me.

**R. McKenzie Daniel, DVM, DABVP (Canine / Feline Practice)**  
info@SonoPath.com