



PATIENT

Kiki True

SPECIES

Canine

BREED

French Bulldog

SEX

Intact Female

AGE

1 year 11 months

WEIGHT

28.6 lbs.

INTERPRETED BY

R. McKenzie Daniel,
DVM, DABVP
(Canine and Feline)

IMAGING PERFORMED BY

Amanda Crook -
SDEP Certified
Clinical Sonographer

HOSPITAL NAME

Rivers Edge Pet
Medical Center

REFERRING VET

Dr. Braat

INVOICE

12186

DATE

9/7/21

PRESENTING CLINICAL SIGNS

Pregnancy Check: AI on 8/11, 8/12, and 8/13 - ultrasound to confirm pregnancy and get rough idea of fetal counts.

ULTRASONOGRAPHIC EXAMINATION OF THE URINARY AND REPRODUCTIVE SYSTEMS

Urinary System

The urinary bladder, trigone, cystourethral junction, and visible pelvic urethra to a depth of 2.0 cm exhibited normal thickness and tone. Anechoic urine was present in the lumen with no uroliths or sediment. The ureteral papillae were normal. The ureters were not visible which is normal. No evidence of inflammatory or neoplastic changes was noted.

The cervix presented as normal. Multiple fetuses within the uterus were present. The uterine appearance was sonographically unremarkable for early pregnancy. Anechoic uterine fluid was noted surrounding the visualized fetuses. Normal fetal heart rate was noted on doppler. An example of a fetus measured 0.79 cm, crown to rump length correlating with an estimated gestational age of approximately 29 days +/- 3 days and consistent with the reported insemination date. The left and right ovaries were sonographically unremarkable. The left ovary measured 1.6 cm in diameter. The right ovary measured 1.8 cm in diameter.

The surrounding peri uterine tissue and the visualized intestinal tract were normal.

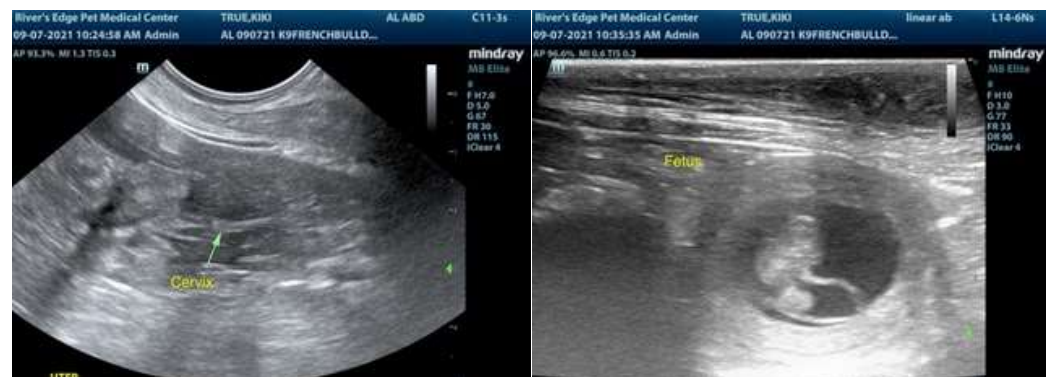ULTRASONOGRAPHIC FINDINGS

Primary Findings

- Confirmed subjectively viable pregnancy - estimate 5-6 fetuses

INTERPRETATION OF THE FINDINGS & FURTHER RECOMMENDATIONS

Radiographic assessment and count of the fetuses closer to parturition is recommended for a more accurate count.





PATIENT

Kiki True

SPECIES

Canine

BREED

French Bulldog

SEX

Intact Female

AGE

1 year 11 months

WEIGHT

28.6 lbs.

INTERPRETED BY

R. McKenzie Daniel,
DVM, DABVP
(Canine and Feline)

IMAGING PERFORMED BY

Amanda Crook -
SDEP Certified
Clinical Sonographer

HOSPITAL NAME

Rivers Edge Pet
Medical Center

REFERRING VET

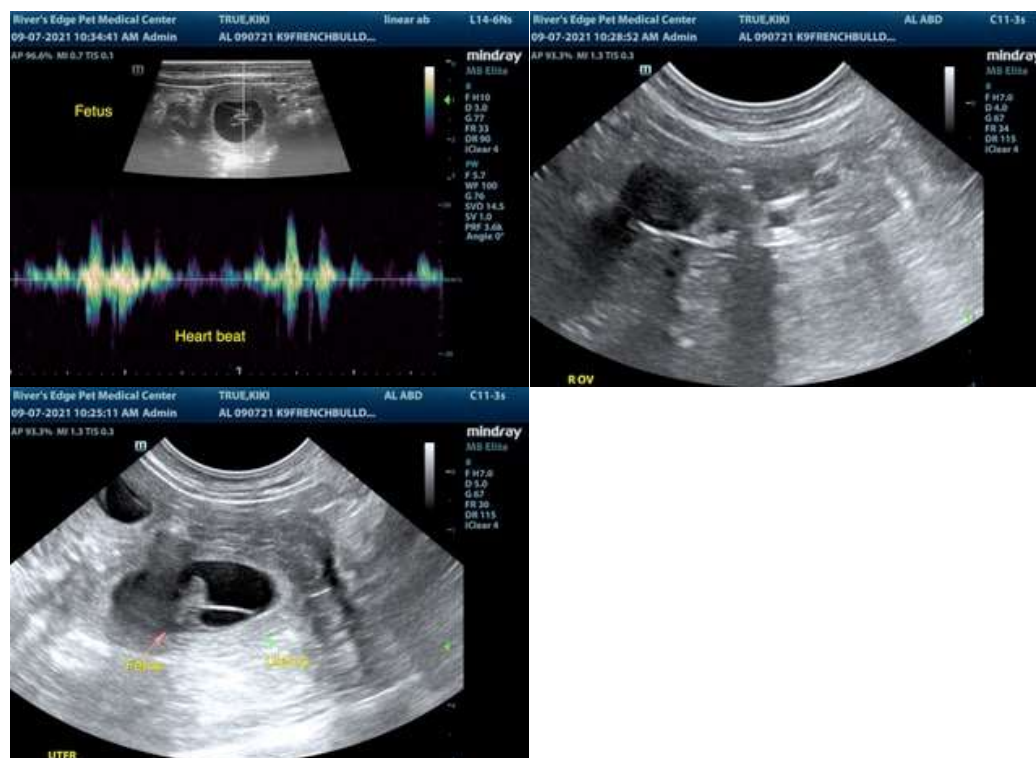
Dr. Braat

INVOICE

12186

DATE

9/7/21



The information and recommendations provided are based on the images presented by the referring veterinarian. No evaluation can be communicated regarding pathology that was not visible in the image/video clips provided.

Thank you for this referral. If the clinical or image interpretation does not parallel your findings or if I can be of any further assistance please contact me.

R. McKenzie Daniel, DVM, DABVP (Canine / Feline Practice)
info@SonoPath.com