

PATIENT	PRESENTING CLINICAL SIGNS
Maggie Jones	lethargic, not eating/drinking, renoliths
SPECIES	ULTRASONOGRAPHIC EXAMINATION OF THE ABDOMEN
Canine	Urinary System
BREED	The urinary bladder, trigone, cystourethral junction, and visible pelvic urethra to a depth of 2 cm exhibited normal thickness and tone. Anechoic urine was present in the lumen with focal small dependent mineral to small calculus. The ureteral papillae were normal. The ureters were not visible which is normal. No evidence of inflammatory or neoplastic changes were noted.
Shih Tzu	Normal size and margination were present in the left kidney. The left kidney exhibited severe hydronephrosis without evidence of renomegaly, the majority of the medullary parenchyma was replaced with anechoic fluid. Intact cortex was observed. No evidence of left hydroureter or left kidney mineral was noted.
SEX	Normal size and margination was present in the right kidney. A normal 1:3 cortex / medulla ratio was maintained. The medulla and cortex was uniform in texture with some increased echogenicity and moderate loss of corticomedullary symmetry and definition expected for the age of the patient. No evidence of pelvic dilation was present. Mild areas of non-obstructive medullary mineral to small renoliths were present in the lateral diverticuli.
FS	
AGE	
17	
WEIGHT	The left kidney measured 3.0 cm in length. The right kidney measured 4.5 cm in length.
8.3	The area of the aortic trifurcation was free of pathology.
INTERPRETED BY	Adrenal Glands
R. McKenzie Daniel, DVM, DABVP (Canine and Feline)	The left adrenal gland was uniform in size and contour with a uniformly hypoechoic parenchyma. The left adrenal gland measured 0.39 cm width at the caudal pole and 1.7 cm length. The right adrenal gland was uniform in size and contour with a uniformly hypoechoic parenchyma. The right adrenal gland measured 0.67 cm width at the caudal pole and 1.5 cm length.
IMAGING PERFORMED BY	Spleen
Jenn	The spleen exhibited a finely textured and homogenous parenchyma which was hyperechoic to the liver and renal cortical parenchyma. The capsule was smooth and regular without apparent expansion. The splenic vasculature at the hilus was normal in volume with no evidence of congestion or thrombosis. Acute to chronic inflammatory, neoplastic, or benign parenchyma changes were not noted. The spleen measured – cm in width at the level of the hilus.
HOSPITAL NAME	Liver
Rockaway Animal Hospital	The liver was subjectively normal in size, structure, and contour. The liver parenchyma was mildly nonuniform and hypoechoic to the spleen with a moderate coarse echotexture and subjective mild to benign parenchymal remodeling. The hepatic and portal vasculature were normal in appearance without signs of congestion.
REFERRING VET	Gastrointestinal
Dr. Bednar	The stomach presented intact wall layering with a normal wall layer ratio. The lumen of the stomach was empty with no signs of ileus, obstruction or foreign material.
INVOICE	
11533ag	
DATE	
09/06/2022	



PATIENT

Maggie Jones

The small intestine presented intact wall layering with 1:3 muscularis/mucosa ratio. Minor segmental mucosal speckling was present. The lumen of the small intestine was empty with no signs of ileus, obstruction or foreign material.

SPECIES

Canine

Normal visible colon wall layers were present with apparent formed feces in lumen.

Pancreas

The parenchyma of the left limb, body and right limb of the pancreas presented isoechoic to the adjacent omental fat. A normal curvilinear capsule contour of the pancreas was present. The visible pancreatic duct was normal. No signs of active inflammation or neoplastic disease was evident.

BREED

Shih Tzu

Free Abdomen

No overt lymphadenopathy or peritoneal effusion was present.

SEX

FS

ULTRASONOGRAPHIC FINDINGS

Primary

AGE

17

- Small dependent urinary bladder mineral/calculus
- Left kidney hydronephrosis
- Non-obstructive right kidney medullary mineral/small renoliths
- Hepatic parenchymal remodeling-subjectively benign
- Mild gallbladder debris (non-mucocele)
- Overtly normal GI tract, possible mild gastroenteritis

WEIGHT

8.3

INTERPRETED BY

R. McKenzie Daniel,
DVM, DABVP
(Canine and Feline)

INTERPRETATION OF THE FINDINGS & FURTHER RECOMMENDATIONS

This patient is likely passing small amounts of mineral from the kidneys into the urinary bladder. It is suspected that passage of mineral from the left kidney into the bladder resulted in left kidney hydronephrosis although current left ureter obstruction owing to mineral/calculus cannot be definitively excluded. Assessment for evidence of discomfort in the area of the left kidney is recommended. Correlation with a full CBC/chem, UA and urine C/S is recommended if not done. As needed GI support would be reasonable.

IMAGING PERFORMED BY

Jenn

HOSPITAL NAME

Rockaway Animal
Hospital

REFERRING VET

Dr. Bednar

INVOICE

11533ag

DATE

09/06/2022



PATIENT

Maggie Jones

SPECIES

Canine

BREED

Shih Tzu

SEX

FS

AGE

17

WEIGHT

8.3

INTERPRETED BY

R. McKenzie Daniel,
DVM, DABVP
(Canine and Feline)

IMAGING PERFORMED BY

Jenn

HOSPITAL NAME

Rockaway Animal
Hospital

REFERRING VET

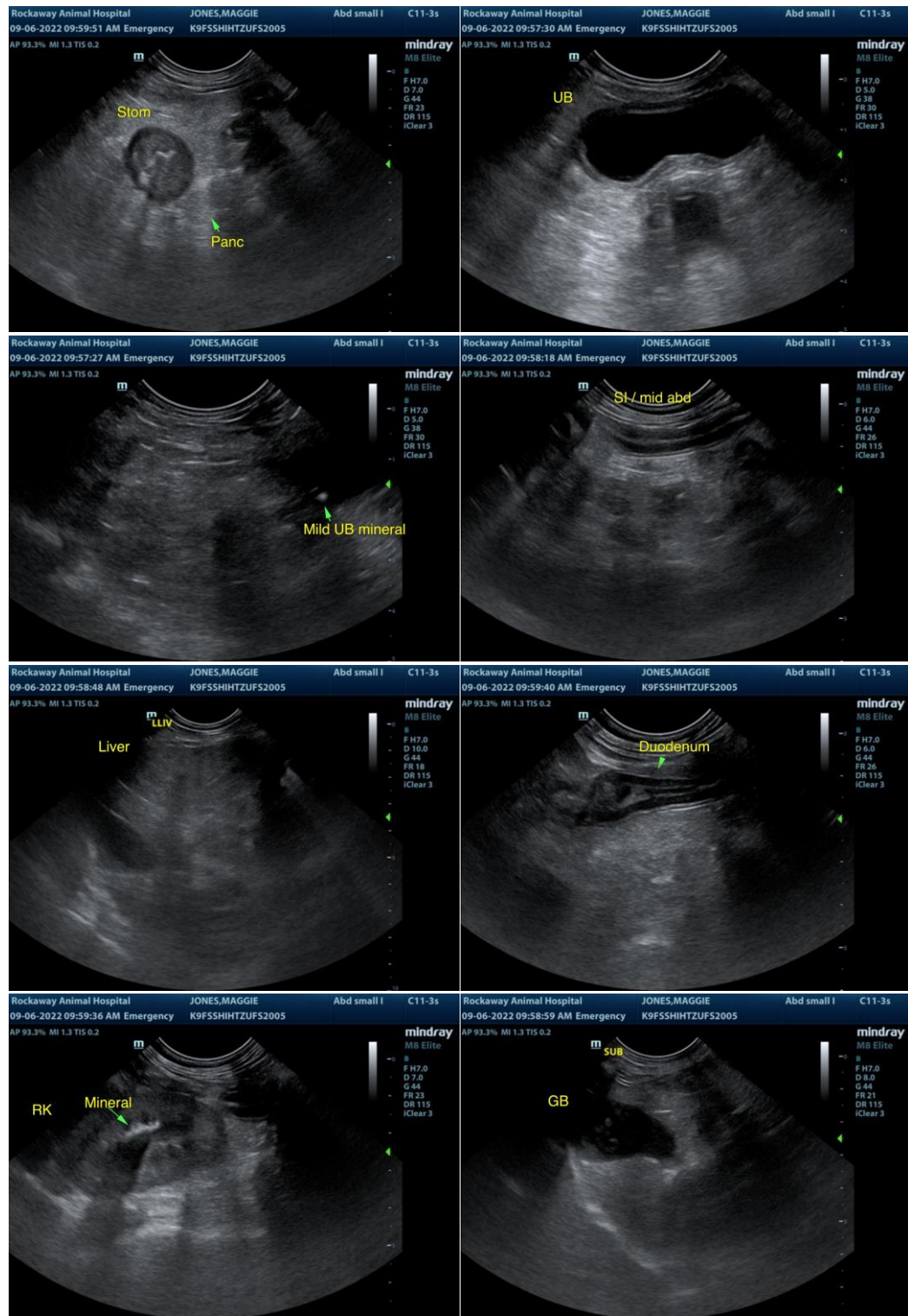
Dr. Bednar

INVOICE

11533ag

DATE

09/06/2022





PATIENT

Maggie Jones

SPECIES

Canine

BREED

Shih Tzu

SEX

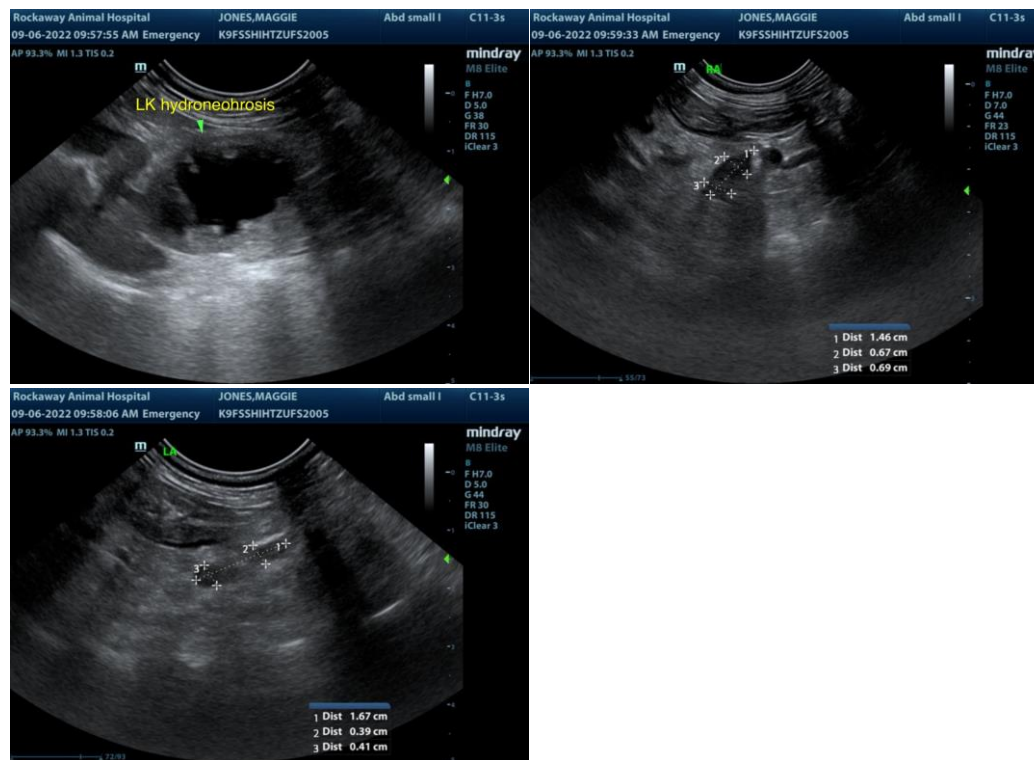
FS

AGE

17

WEIGHT

8.3



INTERPRETED BY

R. McKenzie Daniel,
DVM, DABVP
(Canine and Feline)

IMAGING PERFORMED BY

Jenn

HOSPITAL NAME

Rockway Animal
Hospital

REFERRING VET

Dr. Bednar

INVOICE

11533ag

DATE

09/06/2022

The information and recommendations provided are based on the images presented by the referring veterinarian/sonographer. No evaluation can be communicated regarding pathology that was not visible in the image/video clips provided.

Thank you for this referral. If the clinical or image interpretation does not parallel your findings or if I can be of any further assistance please contact me.

R. McKenzie Daniel, DVM, DABVP (Canine / Feline Practice)

info@SonoPath.com