



**PATIENT**

Ziggy Vivian

**PRESENTING CLINICAL SIGNS**

vomited blood post prandial

**SPECIES**

Canine

**ULTRASONOGRAPHIC EXAMINATION OF THE ABDOMEN**

**Urinary System**

The urinary bladder, trigone, cystourethral junction, and visible pelvic urethra to a depth of – cm exhibited normal thickness and tone. Anechoic urine was present in the lumen with no uroliths or sediment. The ureteral papillae were normal. The ureters were not visible which is normal. No evidence of inflammatory or neoplastic changes were noted.

**BREED**

Shepherd X

The area of the residual prostate and aortic trifurcation were free of pathology.

**SEX**

Neutered Male

Normal size and margination were present in the kidneys. A normal 1:3 cortex / medulla ratio and normal corticomedullary definition were maintained. The echogenicity of the cortex was similar to or slightly less than normal liver parenchyma while the medulla echogenicity was hypoechoic to the cortex with no evidence of pelvic dilation. The left kidney measured 6.2 cm. The right kidney measured 6.3 cm.

**AGE**

2 Years

**Adrenal Glands**

The adrenal glands were uniform in size and contour with a uniformly hypoechoic parenchyma. The left adrenal gland measured 0.47 cm at the cranial pole and 0.52 cm at the caudal pole. The right adrenal gland measured 0.84 cm at the cranial pole and 0.55 cm at the caudal pole.

**WEIGHT**

52

**Spleen**

The spleen exhibited a finely textured and homogenous parenchyma which was hyperechoic to the liver and renal cortical parenchyma. The capsule was smooth and regular without apparent expansion. The splenic vasculature at the hilus was normal in volume with no evidence of congestion or thrombosis. Acute to chronic inflammatory, neoplastic, or benign parenchyma changes were not noted.

**INTERPRETED BY**

R. McKenzie Daniel,  
DVM, DABVP  
(Canine and Feline)

**Liver**

The liver was subjectively normal in size, structure, and contour. The liver parenchyma was uniform and hypoechoic to the spleen with a mild coarse echotexture. The hepatic and portal vasculature were normal in appearance without signs of congestion. The gallbladder was non-distended in size with thin walls and primarily anechoic luminal content. The cystic and common bile ducts were normal.

**IMAGING PERFORMED BY**

Jenn

**HOSPITAL NAME**

Rockaway AH

**Gastrointestinal**

The stomach presented intact wall layering with a normal wall layer ratio. The lumen of the stomach was empty with no signs of ileus, obstruction or foreign material. Gastric body wall measured 0.40 cm.

**REFERRING VET**

Dr. Maniar

The small intestine presented intact wall layering with 1:3 muscularis/mucosa ratio. The lumen of the small intestine was empty with no signs of ileus, obstruction or foreign material. Duodenum wall measured 0.40 cm. Jejunum wall measured 0.40 cm.

**INVOICE**

25954

Normal visible colon wall layers were present with apparent formed feces in lumen.

**Pancreas**

The parenchyma of the left limb, body and right limb of the pancreas presented isoechoic to the adjacent omental fat. A normal curvilinear capsule contour of the pancreas was present. The visible pancreatic duct was normal. No signs of active inflammation or neoplastic disease was evident.

**DATE**

9/30/21



**PATIENT**

Ziggy Vivian

**ULTRASONOGRAPHIC FINDINGS**

- Sonographically unremarkable abdomen

**SPECIES**

Canine

**INTERPRETATION OF THE FINDINGS & FURTHER RECOMMENDATIONS**

No evidence of visceral pathology, specifically no evidence of gastrointestinal pathology such as mechanical/metabolic ileus, masses, foreign material, or obvious ulceration. Potential for microulceration may be possible given the hematemesis. Gastroprotectant protocol is recommended. Screening resting cortisol may be considered to rule out potential for occult Addison's disease. Broad-spectrum deworming is suggested.

**BREED**

Shepherd X

**SEX**

Neutered Male

**AGE**

2 Years

**WEIGHT**

52

**INTERPRETED BY**

R. McKenzie Daniel,  
DVM, DABVP  
(Canine and Feline)

**IMAGING PERFORMED BY**

Jenn

**HOSPITAL NAME**

Rockaway AH

**REFERRING VET**

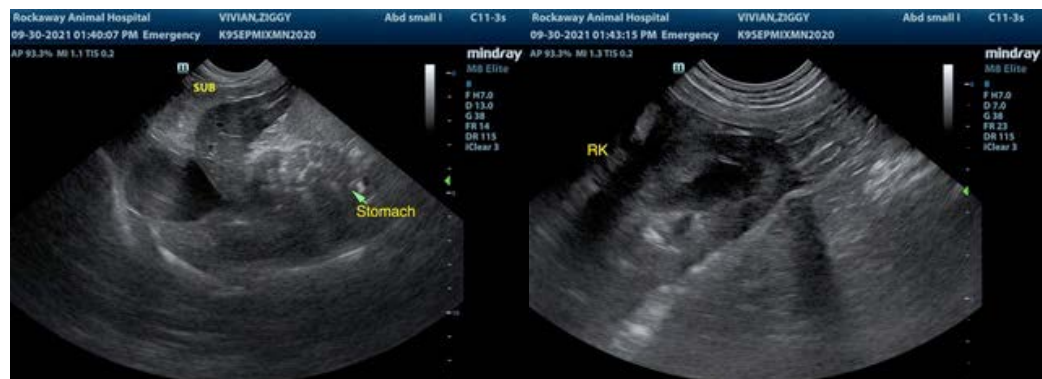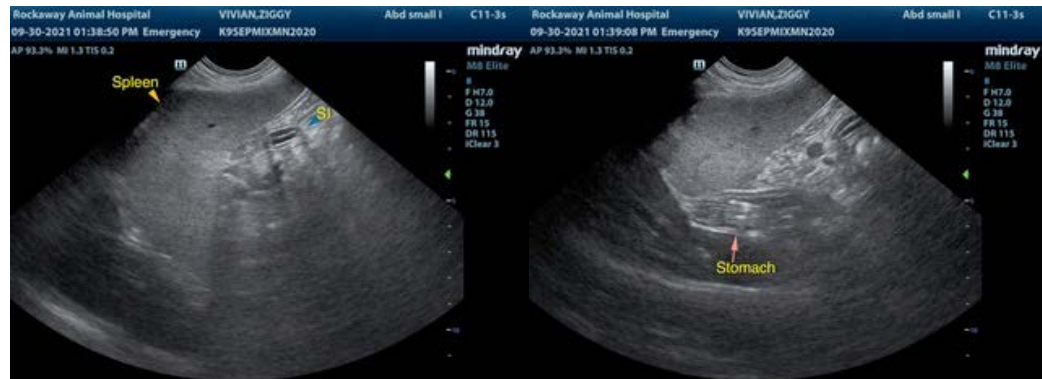
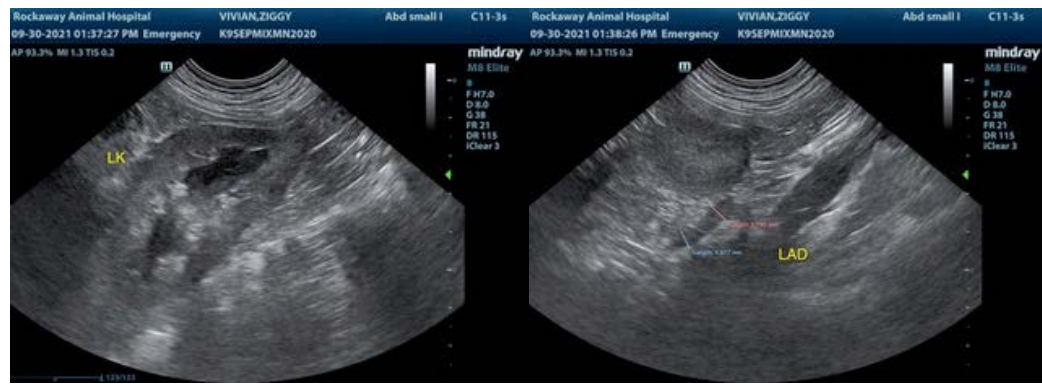
Dr. Maniar

**INVOICE**

25954

**DATE**

9/30/21





**PATIENT**

Ziggy Vivian

**SPECIES**

Canine

**BREED**

Shepherd X

**SEX**

Neutered Male

**AGE**

2 Years

**WEIGHT**

52

**INTERPRETED BY**

R. McKenzie Daniel,  
DVM, DABVP  
(Canine and Feline)

**IMAGING PERFORMED BY**

Jenn

**HOSPITAL NAME**

Rockaway AH

**REFERRING VET**

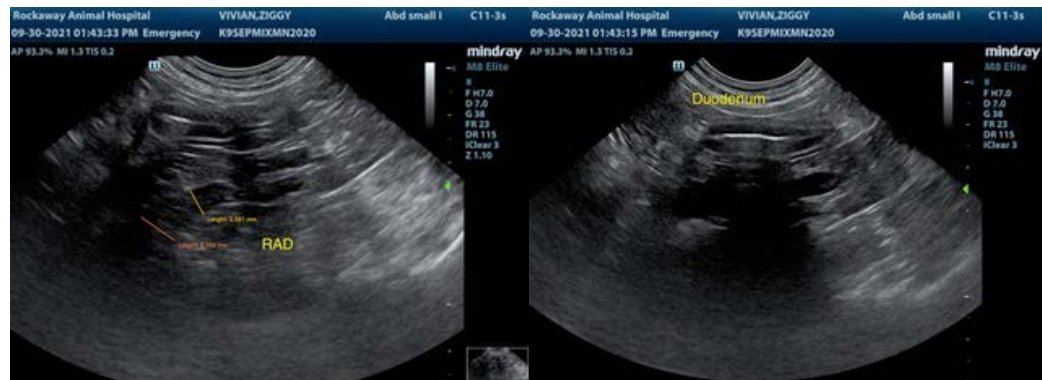
Dr. Maniar

**INVOICE**

25954

**DATE**

9/30/21



The information and recommendations provided are based on the images presented by the referring veterinarian. No evaluation can be communicated regarding pathology that was not visible in the image/video clips provided.

Thank you for this referral. If the clinical or image interpretation does not parallel your findings or if I can be of any further assistance please contact me.

**R. McKenzie Daniel, DVM, DABVP (Canine / Feline Practice)**  
info@SonoPath.com