



PATIENT PRESENTING CLINICAL SIGNS

Tux Barone elevated liver values; icteric
Abnormal PE/Chem/CBC/UA Results: AST 355, ALT 713, ALKP 333, GGT 18, tbili 1.2, BUN 56, chol 226, amylase 1591, HCT 25% with elevated monocytes 890; HGB 8.3, RBC 4.6, platelets elevated 559

SPECIES ULTRASONOGRAPHIC EXAMINATION OF THE ABDOMEN

Feline
Urinary System

BREED The urinary bladder, trigone, cystourethral junction, and visible pelvic urethra to a depth of 2.0 cm exhibited normal thickness and tone. Anechoic urine was present in the lumen with no uroliths or sediment. The ureteral papillae were normal. The ureters were not visible which is normal. No evidence of inflammatory or neoplastic changes were noted.

DSH

SEX

Neutered Male

Normal size and margination were present in the kidneys. A normal 1:3 cortex / medulla ratio was maintained. The medulla and cortices were uniform in texture with some increased echogenicity and loss of corticomedullary symmetry and definition expected for the age of the patient. No evidence of pelvic dilation was present. Probable caudal infarct noted in the left kidney. The right kidney measured 3.1 cm. The left kidney measured 3.2 cm.

AGE

16 Years

The area of the aortic trifurcation was free of pathology.

Adrenal Glands

WEIGHT

9 Pounds

The left adrenal gland was uniform in size and contour with a uniformly hypoechoic parenchyma. The left adrenal gland measured 0.42 cm in width. No overt pathology in the area of the right adrenal gland.

Spleen

INTERPRETED BY

R. McKenzie Daniel,
DVM, DABVP
(Canine and Feline)

The spleen exhibited primarily finely textured parenchyma which was hyperechoic to the liver and renal cortical parenchyma. Mild generalized parenchyma heterogeneity was present without evidence of nodular changes. The capsule was smooth and regular without apparent expansion. The splenic vasculature at the hilus was normal in volume with no evidence of congestion or thrombosis. The parenchymal heterogeneity is likely consistent with benign changes such as extramedullary hematopoiesis or age related remodeling with minor potential for inflammatory or neoplastic disease. The spleen measured 0.8 cm in width.

IMAGING PERFORMED BY

Diane McFadden

Liver

HOSPITAL NAME

Companion AH

The liver was normal in size, yet symmetrical rounded contour noted and moderate coarse echotexture. The liver parenchyma was mildly nonuniform and hypoechoic to the spleen with subjective mild to benign parenchymal remodeling. The hepatic and portal vasculature were normal in appearance without signs of congestion. The gallbladder was non-distended in size with thin walls and primarily anechoic luminal content. The common bile duct was dilated and tortuous approaching the level of the duodenal papilla. The common bile duct dilation measured 0.27 cm in diameter without evidence of ductal calculi or mucus. Overt evidence of obstructive pathology at the level of the duodenal papilla was not evident. This finding may suggest age related changes or secondary to underlying cholangitis / cholangiohepatitis especially if previous or current liver enzymes elevations have been noted.

REFERRING VET

N/A

INVOICE

25962

Gastrointestinal

DATE

9/30/21

The stomach presented intact wall layering with a normal wall layer ratio. The lumen of the stomach was empty with no signs of ileus, obstruction or foreign material.



| | |
|--|--|
| PATIENT | The small intestine presented intact wall layering with primarily maintained 1:3 muscularis/mucosa ratio with subjective propensity for subtly prominent muscularis layer. The lumen of the small intestine was empty with no signs of ileus, obstruction or foreign material. Jejunum wall measured 0.27 cm. Ileocolic wall measured 0.28 cm. |
| Tux Barone | |
| SPECIES | Normal visible colon wall layers were present with apparent formed feces in lumen. |
| Feline | Pancreas |
| BREED | The pancreas was normal in size with mild asymmetrical contour and hypoechoic to heterogeneous parenchyma. Intermittent, mildly hypoechoic nodules were noted. Generalized variable pancreatic dilation was present. |
| DSH | Free Abdomen |
| SEX | Focal to intermittent enlarged mid abdominal mesenteric lymph nodes were present. Example measured 2.1 cm x 0.8 cm. These lymph nodes were homogenous, mildly hypoechoic and smoothly margined. A normal width: length ratio was maintained (<0.5). Evidence of perilymphatic inflammation was evident. |
| Neutered Male | |
| AGE | No effusion. |
| 16 Years | PRIMARY FINDINGS |
| WEIGHT | <ul style="list-style-type: none"> • Hepatopathy – subjectively chronic or acute on chronic • Generalized mild common bile duct dilation – subjectively non-obstructive • Chronic pancreatitis with intermittent nodules and pancreatic duct dilation – nodules suggest of areas of nodular hyperplasia, no overt neoplastic criteria. • Possible chronic enteropathy with associated mesenteric lymphadenopathy – lymph nodes likely consistent with reactive hyperplasia or minor reactive lymphadenitis. |
| 9 Pounds | |
| INTERPRETED BY | SECONDARY FINDINGS |
| R. McKenzie Daniel, DVM, DABVP (Canine and Feline) | <ul style="list-style-type: none"> • Bilateral chronic renal changes with left kidney cortical infarct |
| IMAGING PERFORMED BY | INTERPRETATION OF THE FINDINGS & FURTHER RECOMMENDATIONS |
| Diane McFadden | Overall, hepatobiliary presentation is suggestive of chronic or acute on chronic inflammatory process such as feline cholangitis syndrome/cholangiohepatitis given the primarily elevated ALT/AST combination. Likely non-obstructive cholestasis and/or vacuolar hepatic change given the ALP/GGT combination. The degree of common bile duct dilation was not overtly consistent with post-hepatic obstruction, yet continued monitoring of hepatic enzymes recommended. Potential for chronic triad disease may be a consideration in this patient if decreased body condition, loss of muscle mass, or gastrointestinal signs. |
| HOSPITAL NAME | Further assessment may include GI panel to include PLI, TLI, cobalamin and folate. Empirically, cholangiohepatitis protocol with monitoring of liver parameters and as-needed gastrointestinal support would be reasonable. Recheck sonogram suggested to assess for progressive inflammatory hepatic, pancreatic and gastrointestinal changes if clinical signs continue. |
| Companion AH | |
| REFERRING VET | |
| N/A | |
| INVOICE | |
| 25962 | |
| DATE | |
| 9/30/21 | |



PATIENT

Tux Barone

SPECIES

Feline

BREED

DSH

SEX

Neutered Male

AGE

16 Years

WEIGHT

9 Pounds

INTERPRETED BY

R. McKenzie Daniel,
DVM, DABVP
(Canine and Feline)

IMAGING PERFORMED BY

Diane McFadden

HOSPITAL NAME

Companion AH

REFERRING VET

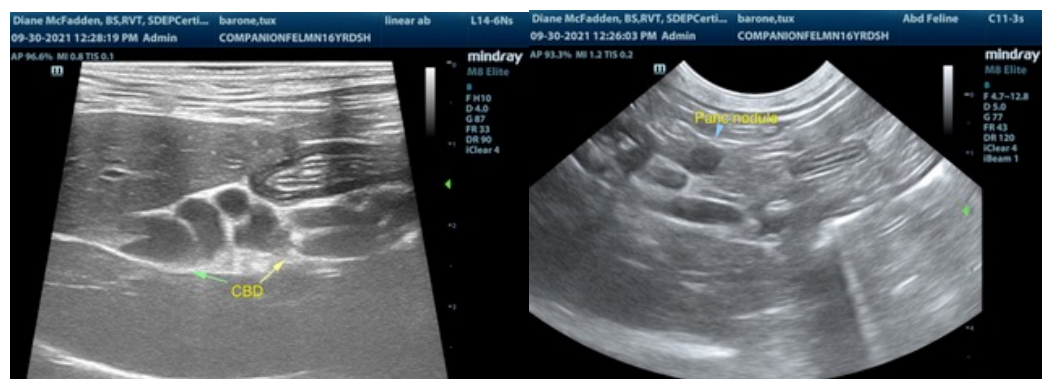
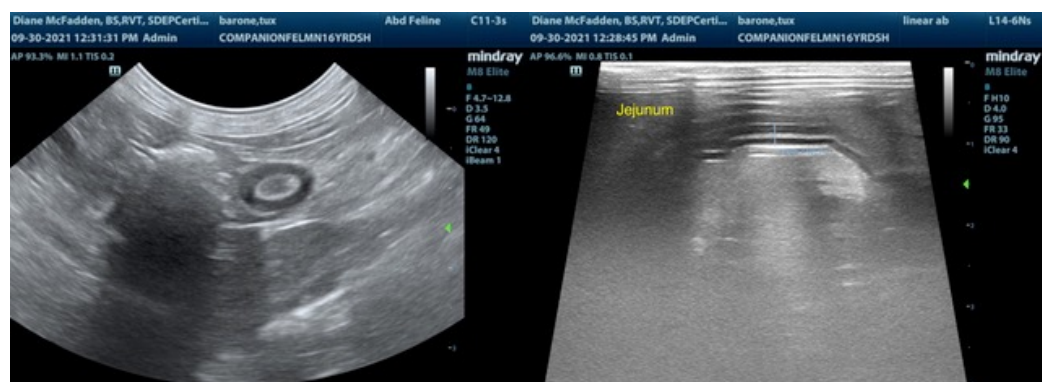
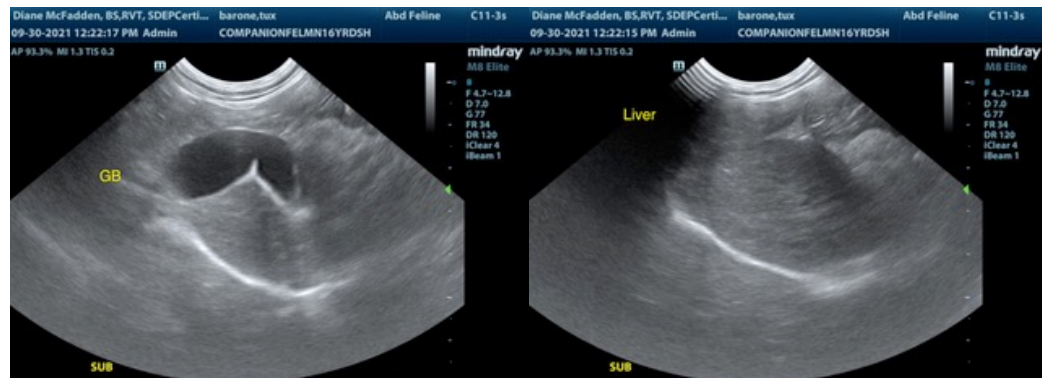
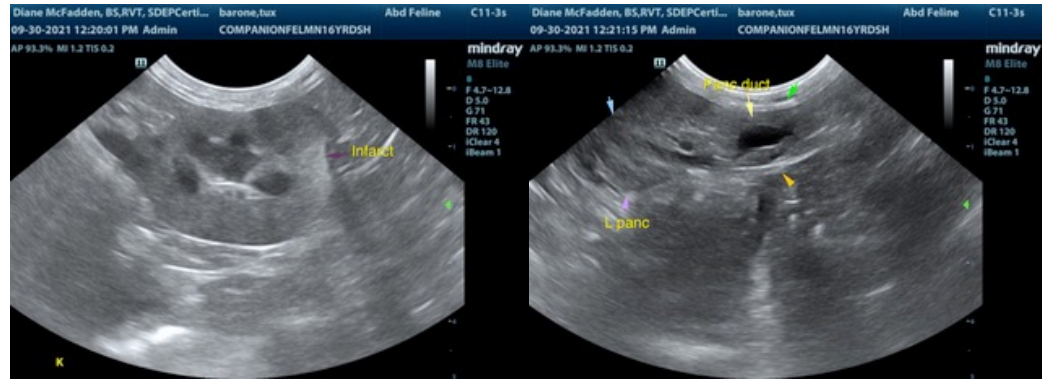
N/A

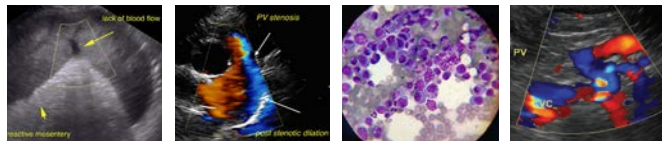
INVOICE

25962

DATE

9/30/21





PATIENT

Tux Barone

SPECIES

Feline

BREED

DSH

SEX

Neutered Male

AGE

16 Years

WEIGHT

9 Pounds

INTERPRETED BY

R. McKenzie Daniel,
DVM, DABVP
(Canine and Feline)

IMAGING PERFORMED BY

Diane McFadden

HOSPITAL NAME

Companion AH

REFERRING VET

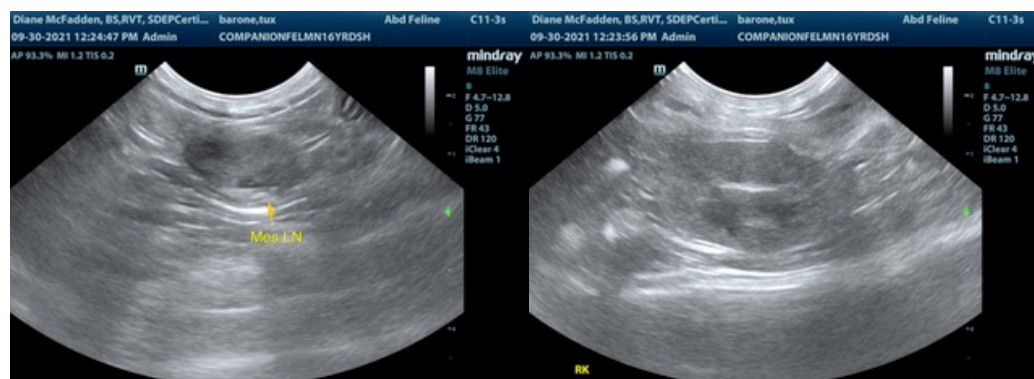
N/A

INVOICE

25962

DATE

9/30/21



The information and recommendations provided are based on the images presented by the referring veterinarian. No evaluation can be communicated regarding pathology that was not visible in the image/video clips provided.

Thank you for this referral. If the clinical or image interpretation does not parallel your findings or if I can be of any further assistance please contact me.

R. McKenzie Daniel, DVM, DABVP (Canine / Feline Practice)
info@SonoPath.com