



**PATIENT**

Pip Richards

**SPECIES**

Canine

**BREED**

Mini/Medium  
Labradoodle

**SEX**

Male

**AGE**

8

**WEIGHT**

26

**INTERPRETED BY**

R. McKenzie Daniel,  
DVM, DABVP  
(Canine and Feline)

**IMAGING PERFORMED BY**

Brian Klug

**HOSPITAL NAME**

Sondel Family  
Veterinary Clinic

**REFERRING VET**

Sondel

**INVOICE**

15044

**DATE**

9/30/22

**PRESENTING CLINICAL SIGNS**

Hx of mildly high hepatic values.

Abnormal PE/Chem/CBC/UA Results: TOTAL PROTEIN 6.3g/dL 25.07.411 ALBUMIN 3.3g/dL 02.74.48 GLOBULIN 3.0g/dL 11.63.610 A/G RATIO 1.1 0.10.82.08 AST (SGOT) 50IU/L 215662500 ALT (SGPT) 165IU/L 2121181500 HIGH Alk Phosphatase 1,210IU/L 251311000 HIGH GGT 2IU/L 5112100 Total Bilirubin 0.2MG/DL 0.10.10.34 BUN 8MG/DL 2631200 Creatinine 0.7MG/DL 0.10.51.615 BUN/CREAT RATIO 11 1427100 PHOSPHORUS 3.9MG/DL 1.02.56.010.0 Glucose 102MG/DL 2570138500 CALCIUM 9.6MG/DL 68.911.416 CORRECTED CALCIUM 9.8 MAGNESIUM 1.9mEq/L. 0.751.52.54.0 SODIUM 143MEQ/L 125139154175 POTASSIUM 4.5MEQ/L 2.03.65.510.0 NA/K RATIO 32 15273875 CHLORIDE 104MEQ/L 75102120160 CHOLESTEROL 236MG/DL 1092324750 TRIGLYCERIDE 387mg/dL 2292911000 HIGH AMYLASE 942IU/L 2529011257500 PrecisionPSL 44U/L 24140 Pancreatitis is unlikely, but a normal PrecisionPSL result does not completely exclude pancreatitis as a cause for gastrointestinal signs. CPK 101IU/L 40598955000 Sample Conditions Hemolysis 4+ No significant interference

**ULTRASONOGRAPHIC EXAMINATION OF THE ABDOMEN**

**Urinary System**

The urinary bladder, trigone, cystourethral junction, and visible pelvic urethra to a depth of 3.0 cm exhibited normal thickness and tone. Anechoic urine was present in the lumen with no uroliths or sediment. The ureteral papillae were normal. The ureters were not visible which is normal. No evidence of inflammatory or neoplastic changes was noted.

The area of the aortic trifurcation was free of pathology.

Normal size and margination were present in the kidneys. A normal 1:3 cortex / medulla ratio was maintained. The medulla and cortices were uniform in texture with some increased echogenicity and minor loss of corticomedullary symmetry and definition expected for the age of the patient. No evidence of pelvic dilation was present. The left kidney measured 4.9 cm in length. The right kidney measured 4.5 cm in length.

**Adrenal Glands**

The left adrenal gland was uniform in size and contour with a uniformly hypoechoic parenchyma. The left adrenal gland measured 0.56 cm width at the caudal pole and 0.44 cm width at the cranial pole. The right adrenal gland was indistinctly visualized yet overtly normal in size, position and shape. The right adrenal gland subjectively measured 0.36 cm width at the caudal pole. No evidence of adrenomegaly or tumors.

**Spleen**

The spleen was normal in size and contour with subtle splenic parenchyma heterogeneity including intermittent discrete isoechoic nondisruptive nodule. The nodules are likely consistent with discrete areas of hyperplasia, hematopoiesis, or similar without evidence of splenic neoplastic criteria. The splenic hilus was free of pathology including no evidence of thrombosis with normal splenic vascularity.



**PATIENT**

***Liver/ Gallbladder***

Pip Richards

**SPECIES**

Canine

**BREED**

Mini/Medium  
Labradoodle

**SEX**

Male

**AGE**

8

**WEIGHT**

26

The liver presented enlarged in size. The parenchyma of the liver was subjectively normal in echogenicity compared to the spleen and renal cortices. The liver parenchyma was uniform with a mildly coarse echotexture. The capsule of the liver was symmetrically rounded to mildly swollen in margination. The hepatic and portal vasculature were normal in appearance without signs of congestion. The gallbladder was non-distended in size with mild, non-dependent, mildly echogenic, mobile gallbladder debris. No evidence of gallbladder or peripheral gallbladder inflammatory criteria was noted. The cystic and common bile ducts were normal.

***Gastrointestinal***

The stomach presented intact wall layering with a normal wall layer ratio. The lumen of the stomach contained mild, nonshadowing ingesta most consistent with food without signs of ileus, obstruction or foreign material.

The small intestine presented intact wall layering with 1:3 muscularis/mucosa ratio. The lumen of the small intestine was empty with no signs of ileus, obstruction, or foreign material.

Normal visible colon wall layers were present with subjective semi-formed fecal matter.

***Pancreas***

The parenchyma of the left limb, body, and right limb of the pancreas presented isoechoic to the adjacent omental fat. A normal curvilinear capsule contour of the pancreas was present. The visible pancreatic duct was normal. No signs of active inflammation or neoplastic disease were evident.

***Free Abdomen***

No overt lymphadenopathy or peritoneal effusion was present.

**INTERPRETED BY**

R. McKenzie Daniel,  
DVM, DABVP  
(Canine and Feline)

**IMAGING  
PERFORMED BY**

Brian Klug

**HOSPITAL NAME**

Sondel Family  
Veterinary Clinic

**REFERRING VET**

Sondel

**INVOICE**

15044

**DATE**

9/30/22

**ULTRASONOGRAPHIC FINDINGS**

- Benign hepatopathy
- Minor gallbladder debris (non-mucocele)
- Early to minor age-related renal changes
- Sonographically unremarkable bilateral adrenal glands
- Gastric ingesta

**INTERPRETATION OF THE FINDINGS & FURTHER RECOMMENDATIONS**

The overall appearance of the liver was nonspecific yet consistent with benign hepatopathy. Potential considerations may include vacuolar hepatopathy, nonobstructive hepatic cholestasis, inflammatory / immune-mediated disease, toxic hepatopathy i.e., copper, or other hepatopathy without sonographic evidence of infiltrative neoplasia which is considered unlikely.

Further assessment of the liver may include screening FNA cytology primary to assess for evidence of inflammatory cells or anagenic stimulation +/- Leptospirosis titers / PCR if clinically indicated. Hepatic core surgical biopsy is likely required for a definitive diagnosis.



**PATIENT**

Pip Richards

Empirically, Hepatosupportive medications including Denamarin and Ursodiol, as well as hydrolyzed diet trial, especially if evidence of anagenic stimulation i.e., lymphoplasmacytic infiltrates on-screen cytology may prove beneficial.

**SPECIES**

Canine

**BREED**

Mini/Medium  
Labradoodle

**SEX**

Male

**AGE**

8

**WEIGHT**

26

**INTERPRETED BY**

R. McKenzie Daniel,  
DVM, DABVP  
(Canine and Feline)

**IMAGING PERFORMED BY**

Brian Klug

**HOSPITAL NAME**

Sondel Family  
Veterinary Clinic

**REFERRING VET**

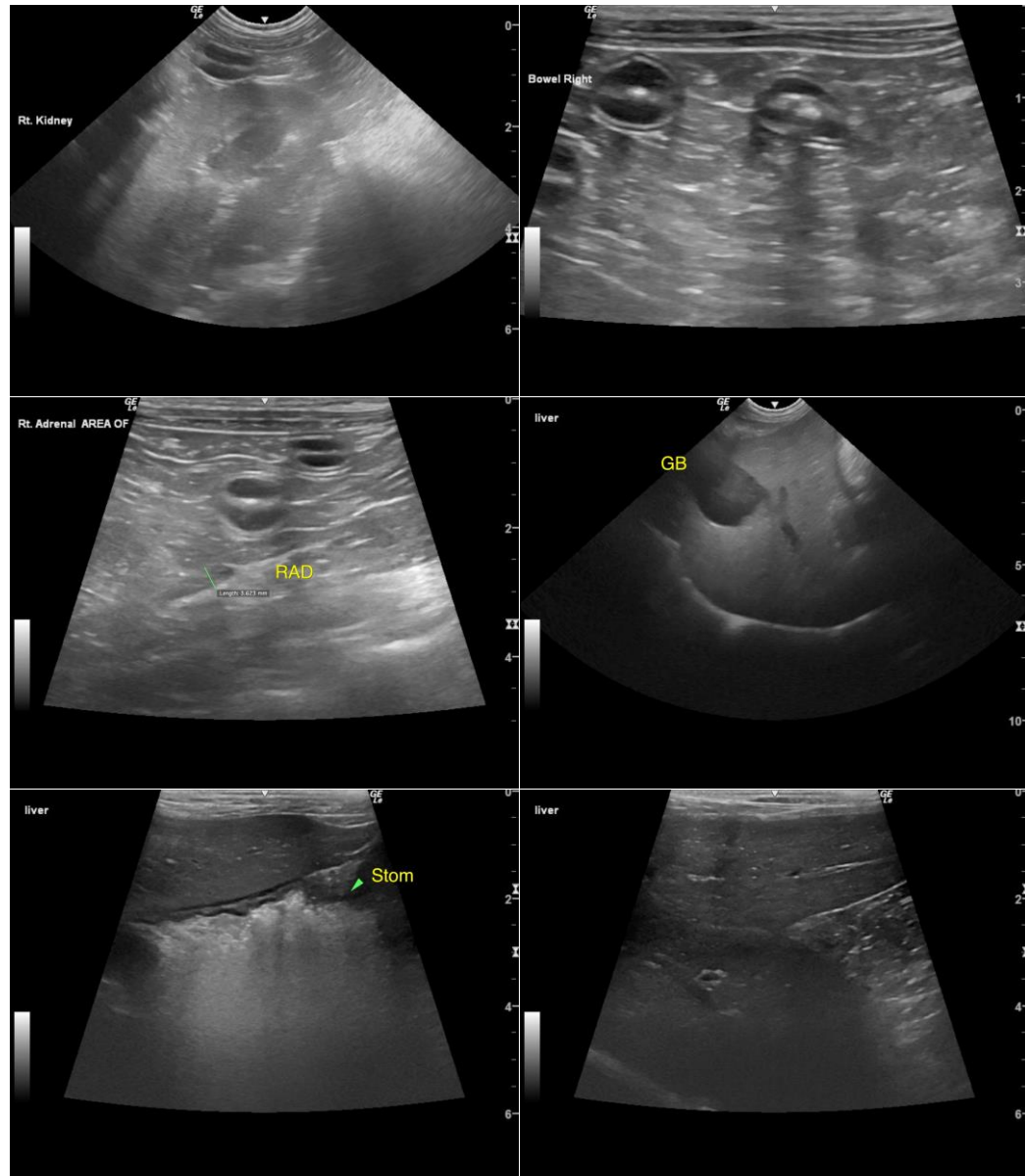
Sondel

**INVOICE**

15044

**DATE**

9/30/22





**PATIENT**

Pip Richards

**SPECIES**

Canine

**BREED**

Mini/Medium  
Labradoodle

**SEX**

Male

**AGE**

8

**WEIGHT**

26

**INTERPRETED BY**

R. McKenzie Daniel,  
DVM, DABVP  
(Canine and Feline)

**IMAGING PERFORMED BY**

Brian Klug

**HOSPITAL NAME**

Sondel Family  
Veterinary Clinic

**REFERRING VET**

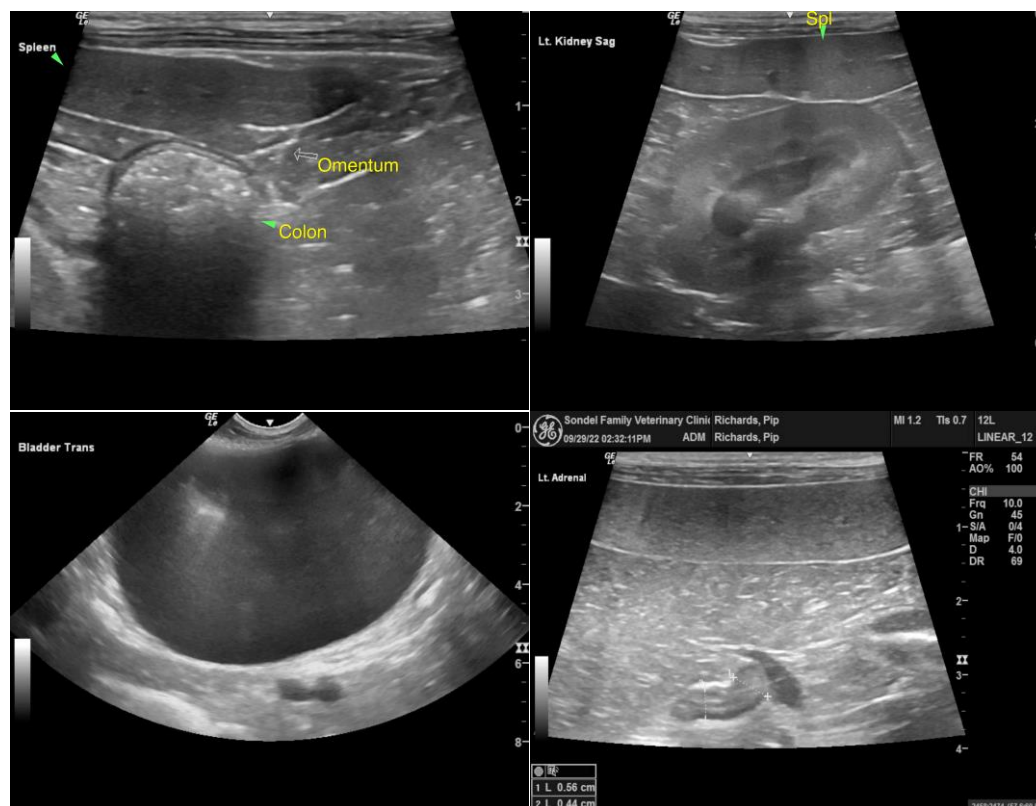
Sondel

**INVOICE**

15044

**DATE**

9/30/22



The information and recommendations provided are based on the images presented by the referring veterinarian/sonographer. No evaluation can be communicated regarding pathology that was not visible in the image/video clips provided.

Thank you for this referral. If the clinical or image interpretation does not parallel your findings or if I can be of any further assistance please contact me.

**R. McKenzie Daniel, DVM, DABVP (Canine / Feline Practice)**  
info@SonoPath.com