# SonoPath
Clinical Sonography & Telecytology

EDUCATIONAL TELECONSULTATION SERVICES™

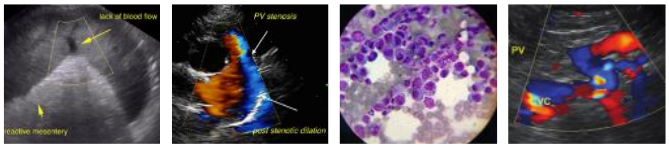

SonoPath.com™
1-800-838-4268 info@sonopath.com

**PATIENT**

Jasper Wentz

**SPECIES**

Canine

**BREED**

Labrador X

**SEX**

Neutered Male

**AGE**

6 Years

**WEIGHT**

35.5 kg

**INTERPRETED BY**

R. McKenzie Daniel, DVM, DABVP (Canine and Feline)

**IMAGING PERFORMED BY**

Dr. Sarah Barthelemy

**HOSPITAL NAME**

Healing Traditions Holistic Vet

**REFERRING VET**

Dr. Balc

**INVOICE**

17483

**DATE**

9/29/22

## PRESENTING CLINICAL SIGNS

History: Presented this week for vomiting, lethargy, hyporexia. Responded onto cerenia. On IVF today. Abnormal PE/Chem/CBC/UA Results: ALT over 7000, AST over 1200, ALP 745, GGT 35, bilirubin elevated 36.2, cholesterol elevated 17.

## ULTRASONOGRAPHIC EXAMINATION OF THE ABDOMEN

### *Urinary System*

The urinary bladder, trigone, cystourethral junction, and visible pelvic urethra to a depth of 3.0 cm exhibited normal thickness and tone. Anechoic urine was present in the lumen with no uroliths or sediment. The ureteral papillae were normal. The ureters were not visible which is normal. No evidence of inflammatory or neoplastic changes were noted. Aortic trifurcation was normal.

No overt pathology in the area of the residual prostate.

Normal size and margination was present in the kidneys. A normal 1:3 cortex / medulla ratio and normal corticomedullary definition were maintained. The echogenicity of the cortex was similar to or slightly less than normal liver parenchyma while the medulla echogenicity was hypoechoic to the cortex with no evidence of pelvic dilation. The left kidney measured 6.4 cm in length. The right kidney measured 6.6 cm in length.

### *Adrenal Glands*

The left adrenal gland was uniform in size and contour with a uniformly hypoechoic parenchyma. The left adrenal gland measured 0.73 cm width at the caudal pole and 0.50 cm width at the cranial pole.

The right adrenal gland was uniform in size and contour with a uniformly hypoechoic parenchyma. The right adrenal gland measured 0.57 cm width at the caudal pole and 0.53 cm width at the cranial pole.

### *Spleen*

The spleen exhibited a finely textured and homogenous parenchyma which was hyperechoic to the liver and renal cortical parenchyma. The capsule was smooth and regular without apparent expansion. The splenic vasculature at the hilus was normal in volume with no evidence of congestion or thrombosis. Acute to chronic inflammatory, neoplastic, or benign parenchyma changes were not noted.

### *Liver*

The liver exhibited subjective mild to possible moderate generalized enlargement and maintained symmetrical capsular contour. Uniform decreased hepatic parenchyma echogenicity was noted with mild increased yet indistinct portal vascular borders. No evidence of hepatic masses or nodules noted.

The gallbladder was non-distended with evidence of very scant gallbladder wall edema with mild increased wall echogenicity. Primarily anechoic content was noted with mild dependent yet nonorganized mildly echogenic luminal debris primarily in the caudal lumen, in the area of the gallbladder neck. No evidence of peripheral gallbladder inflammation. The common bile duct was not definitively visualized without evidence of common bile duct dilation, stasis or obstructive criteria.

### *Gastrointestinal*

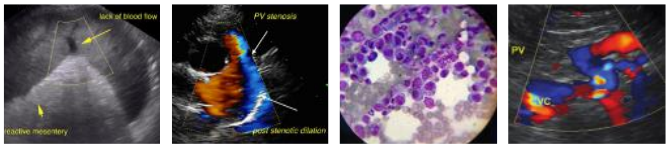

SonoPath.com™
1-800-838-4268 info@sonopath.com

**PATIENT**

Jasper Wentz

**SPECIES**

Canine

**BREED**

Labrador X

**SEX**

Neutered Male

**AGE**

6 Years

**WEIGHT**

35.5 kg

**INTERPRETED BY**

R. McKenzie Daniel, DVM, DABVP (Canine and Feline)

**IMAGING PERFORMED BY**

Dr. Sarah Barthelemy

**HOSPITAL NAME**

Healing Traditions Holistic Vet

**REFERRING VET**

Dr. Balc

**INVOICE**

17483

**DATE**

9/29/22

The stomach presented intact wall layering with a normal wall layer ratio. The lumen of the stomach contained a mild to moderate amount of retained anechoic fluid. No evidence of mechanical pyloric outflow obstruction.

The small intestine presented intact wall layering with 1:3 muscularis/mucosa ratio. The lumen of the small intestine was empty with no evidence of mechanical/metabolic ileus.

Normal visible colon wall layers were present with apparent formed feces in lumen.

### *Pancreas*

The parenchyma of the left limb, body and right limb of the pancreas presented isoechoic to the adjacent omental fat. A normal curvilinear capsule contour of the pancreas was present. The visible pancreatic duct was normal. No signs of active inflammation or neoplastic disease was evident.

### *Free Abdomen*

No overt lymphadenopathy or peritoneal effusion was present.

## ULTRASONOGRAPHIC FINDINGS

- Hepatopathy- subjectively acute
- Mild congealed gallbladder debris with evidence of scant gallbladder wall edema, sonographically unremarkable common bile duct
- Hypomotile stomach, sonographically unremarkable small bowel- probable metabolic gastric hypomotility without evidence of pyloric outflow obstruction

## INTERPRETATION OF THE FINDINGS & FURTHER RECOMMENDATIONS

Although nonspecific, the most likely etiology for the hepatopathy and subjective scant gallbladder wall edema, is suspected acute hepatitis (viral, bacterial, leptospirosis, toxin, etc.) and in line with a history of severely ALT/AST combination. Potential for concurrent primary vacuolar hepatic changes and hepatic cholestasis given the elevated ALP/GGT combination without overt evidence of posthepatic obstruction. Occult hepatic neoplasia cannot be definitively excluded yet considered a less likely differential diagnosis.

Further assessment may include FNA cytology of the liver, assuming normal clotting status, as well as leptospirosis titers/PCR. Empirical therapy may include as needed GI support, hepatosupportive medications, antibiotic trial to cover for leptospirosis /cholangiohepatitis if clinically indicated with assessment of clinical and hepatic response.

# SonoPath

*Clinical Sonography & Telecytology*

EDUCATIONAL TELECONSULTATION SERVICES™

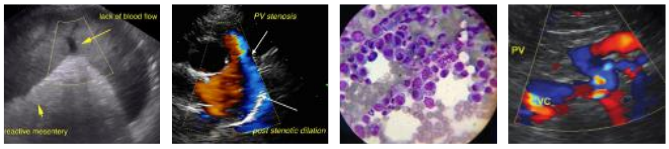


SonoPath.com™
1-800-838-4268 info@sonopath.com

**PATIENT**

Jasper Wentz

**SPECIES**

Canine

**BREED**

Labrador X

**SEX**

Neutered Male

**AGE**

6 Years

**WEIGHT**

35.5 kg

**INTERPRETED BY**

R. McKenzie Daniel, DVM, DABVP (Canine and Feline)

**IMAGING PERFORMED BY**

Dr. Sarah Barthelemy

**HOSPITAL NAME**

Healing Traditions Holistic Vet

**REFERRING VET**

Dr. Balc

**INVOICE**

17483

**DATE**

9/29/22

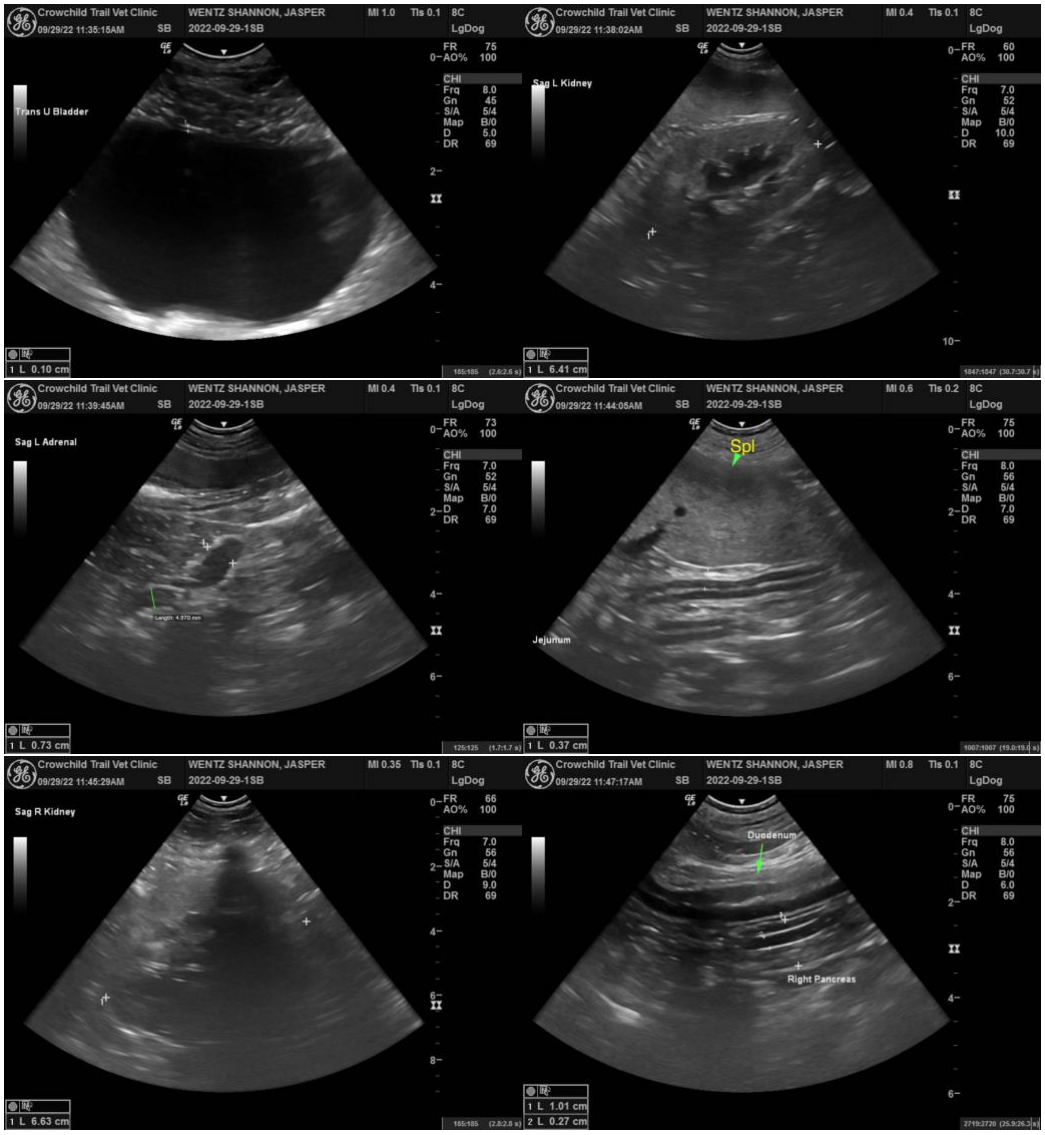

# SonoPath

*Clinical Sonography & Telecytology*

EDUCATIONAL TELECONSULTATION SERVICES™

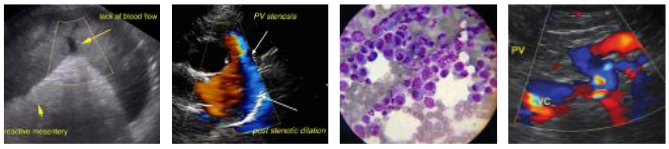

SonoPath.com™
1-800-838-4268 info@sonopath.com

**PATIENT**

Jasper Wentz

**SPECIES**

Canine

**BREED**

Labrador X

**SEX**

Neutered Male

**AGE**

6 Years

**WEIGHT**

35.5 kg

**INTERPRETED BY**

R. McKenzie Daniel, DVM, DABVP (Canine and Feline)

**IMAGING PERFORMED BY**

Dr. Sarah Barthelemy

**HOSPITAL NAME**

Healing Traditions Holistic Vet

**REFERRING VET**

Dr. Balc

**INVOICE**

17483

**DATE**

9/29/22

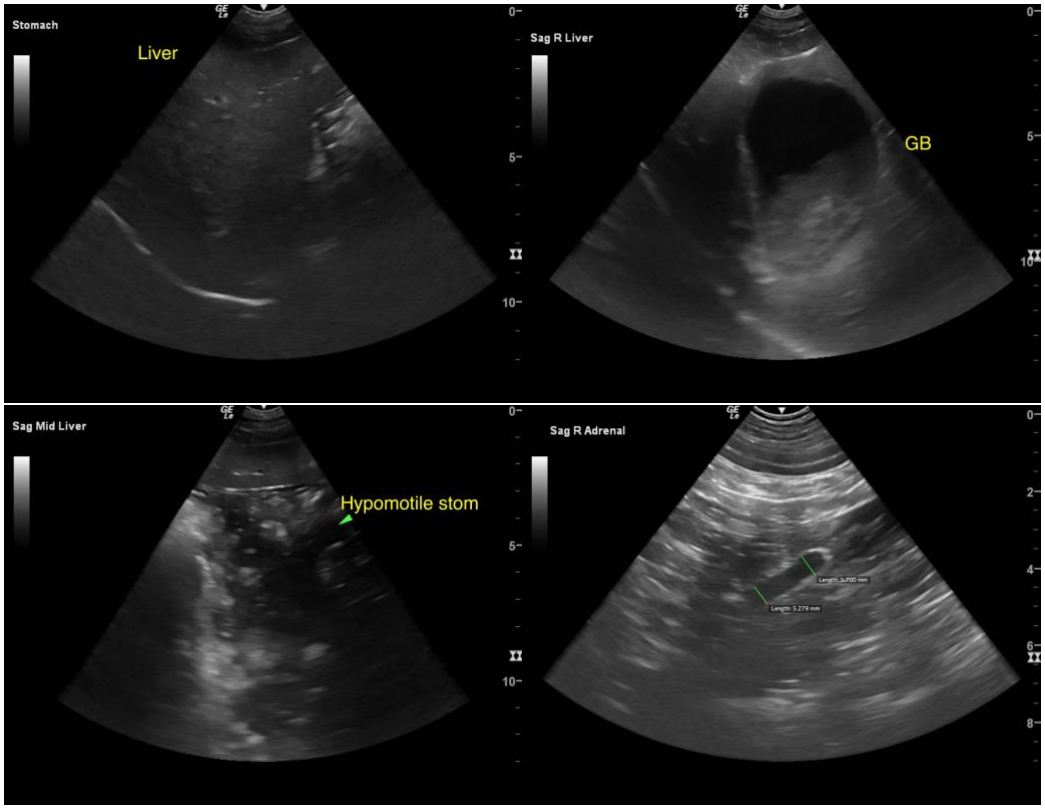


**The information and recommendations provided are based on the images presented by the referring veterinarian. No evaluation can be communicated regarding pathology that was not visible in the image/video clips provided.**

Thank you for this referral. If the clinical or image interpretation does not parallel your findings or if I can be of any further assistance please contact me.

**R. McKenzie Daniel, DVM, DABVP (Canine / Feline Practice)**
**info@SonoPath.com**