



PATIENT

Lu lu Pittman

SPECIES

Canine

BREED

Shih tzu

SEX

SF

AGE

13 years

WEIGHT

16 lbs

PRESENTING CLINICAL SIGNS

-Diarrhea, not eating, excessive drinking. Pt ate a little yesterday but then vomited it up.

Abnormal PE/Chem/CBC/UA Results- Heart murmur L 4/6 R 3/6. Anemic, high white blood cell count, and hyposthenuria.

ULTRASONOGRAPHIC EXAMINATION OF THE ABDOMEN

Urinary System

The urinary bladder presented uniformly thickened urinary bladder wall isoechoic to the adjacent normal urinary bladder wall. The luminal margin of the thickened urinary bladder wall was mildly asymmetrical in contour. Mineralization or echogenic foci within the thickened areas of urinary bladder wall was not present. The urinary bladder, trigone, cystourethral junction, and visible pelvic urethra exhibited normal tone to a depth of 2.0 cm. Mild to moderate, dependent mineralized sand was present. The sand appeared to extend into the area of the cystourethral junction and proximal urethra without evidence of obstruction. The ureteral papillae were normal. The ureters were not visible which is normal.

The area of the aortic trifurcation was free of pathology.

INTERPRETED BY

R. McKenzie Daniel,
DVM, DABVP
(Canine and Feline)

Normal size and margination were present in the kidneys. A normal 1:3 cortex / medulla ratio was maintained. The medulla and cortices were uniform in texture with some increased echogenicity and moderate loss of corticomedullary symmetry and definition expected for the age of the patient. Nonobstructive areas of medullary mineralization, primarily in the lateral diverticuli, were present. No evidence of pelvic dilation was present. The left kidney measured 4.5 cm in length. The right kidney measured 4.8 cm in length.

IMAGING PERFORMED BY

Rachel Runnells, RVT

Adrenal Glands

The left adrenal gland was symmetrically enlarged in size with nonhomogeneous to focal echogenic nodular parenchyma. The left adrenal gland measured 2.5 cm length x 1.2 cm width at the caudal pole and 1.6 cm width at the cranial pole. No overt vascular invasion associated with the left adrenal gland was noted.

HOSPITAL NAME

SVS Imaging KC

REFERRING VET

Dr. Johathon Renfro

The right adrenal gland was normal in size. Mild parenchyma heterogeneity and mild capsule asymmetry was present without suspicion for overt neoplasia. The right adrenal gland measured 1.8 cm length x 0.41 cm width in the caudal pole.

INVOICE

12342

DATE

9/29/21

Spleen

The spleen exhibited generalized hypoechoic parenchymal. No evidence of nodular changes was noted. The capsule was smooth and regular without apparent expansion. The splenic vasculature at the hilus was normal in volume with no evidence of congestion or thrombosis. The parenchymal heterogeneity is likely consistent with benign changes such as extramedullary hematopoiesis or age-related remodeling with minor potential for inflammatory or neoplastic disease.



PATIENT

Liver/ Gallbladder

Lu lu Pittman

The liver presented normal in size. The hepatic parenchyma revealed diffuse reduced echogenicity compared to the spleen and renal cortical parenchyma with a mild coarse echotexture. Increased portal vein prominence was evident. The capsule of the liver was normal in margination. Distinct masses or nodules were not evident. The hepatic and portal vasculature were normal in appearance. The gallbladder was non-distended in size with mild luminal debris and mildly echogenic to prominent gallbladder walls. The cystic and common bile ducts were normal.

SPECIES

Canine

BREED

Shih tzu

Gastrointestinal

SEX

The stomach presented wall thickening secondary to echogenic mucosa hypertrophy. Intact wall layering was maintained and distinct. Mild gastric distension with primarily anechoic fluid was present.

SF

AGE

13 years

The small intestine exhibited intact yet segmental to generalized prominent wall layering owing to segmental propensity for muscularis layer hypertrophy, as well as prominent to echogenic submucosa. A large intestinal mass noted in the subjective mid to cranial abdomen exhibiting marked mural hypertrophy, decreased mural echogenicity, and loss of wall layering, measuring approximately 7.0 cm - 8.0 cm in length with wall width up to 2.0 cm in width, was present. Potential for additional areas of intestinal mural thickening within the area of the mid to cranial intestinal mass is also possible.

WEIGHT

16 lbs

Normal visible colon wall layers were present with apparent formed feces in lumen.

INTERPRETED BY

Pancreas

R. McKenzie Daniel,
DVM, DABVP
(Canine and Feline)

The pancreas was normal in size and contour with isoechoic to heterogeneous parenchyma compared to adjacent omentum. No signs of active inflammation or neoplasia.

**IMAGING
PERFORMED BY**

Free Abdomen

Rachel Runnells, RVT

Mid abdominal to potentially peri ileocolic lymph nodes were present. The lymph nodes exhibited symmetrical to rounded margination with abnormal width: length ratio (>0.5). The enlarged lymph nodes were bordered by echogenic to reactive mesentery. The generalized reactive to echogenic mesentery along with mild peritoneal free fluid were noted.

HOSPITAL NAME

ULTRASONOGRAPHIC FINDINGS

SVS Imaging KC

Primary Findings

REFERRING VET

Dr. Johathon Renfro

- Infiltrative enteropathy pattern with large intestinal mass to potential masses
- Associated significant mesenteric lymphadenopathy and peritonitis
- Hypoechoic hepatosplenic parenchyma
- Left adrenal mass

INVOICE

12342

DATE

9/29/21

Secondary Findings

- Bilateral chronic renal changes with medullary mineralization
- Urinary bladder nonobstructive proximal urethral mineral



PATIENT

Lu lu Pittman

SPECIES

Canine

BREED

Shih tzu

SEX

SF

AGE

13 years

WEIGHT

16 lbs

INTERPRETED BY

R. McKenzie Daniel,
DVM, DABVP
(Canine and Feline)

IMAGING PERFORMED BY

Rachel Runnells, RVT

HOSPITAL NAME

SVS Imaging KC

REFERRING VET

Dr. Johathon Renfro

INVOICE

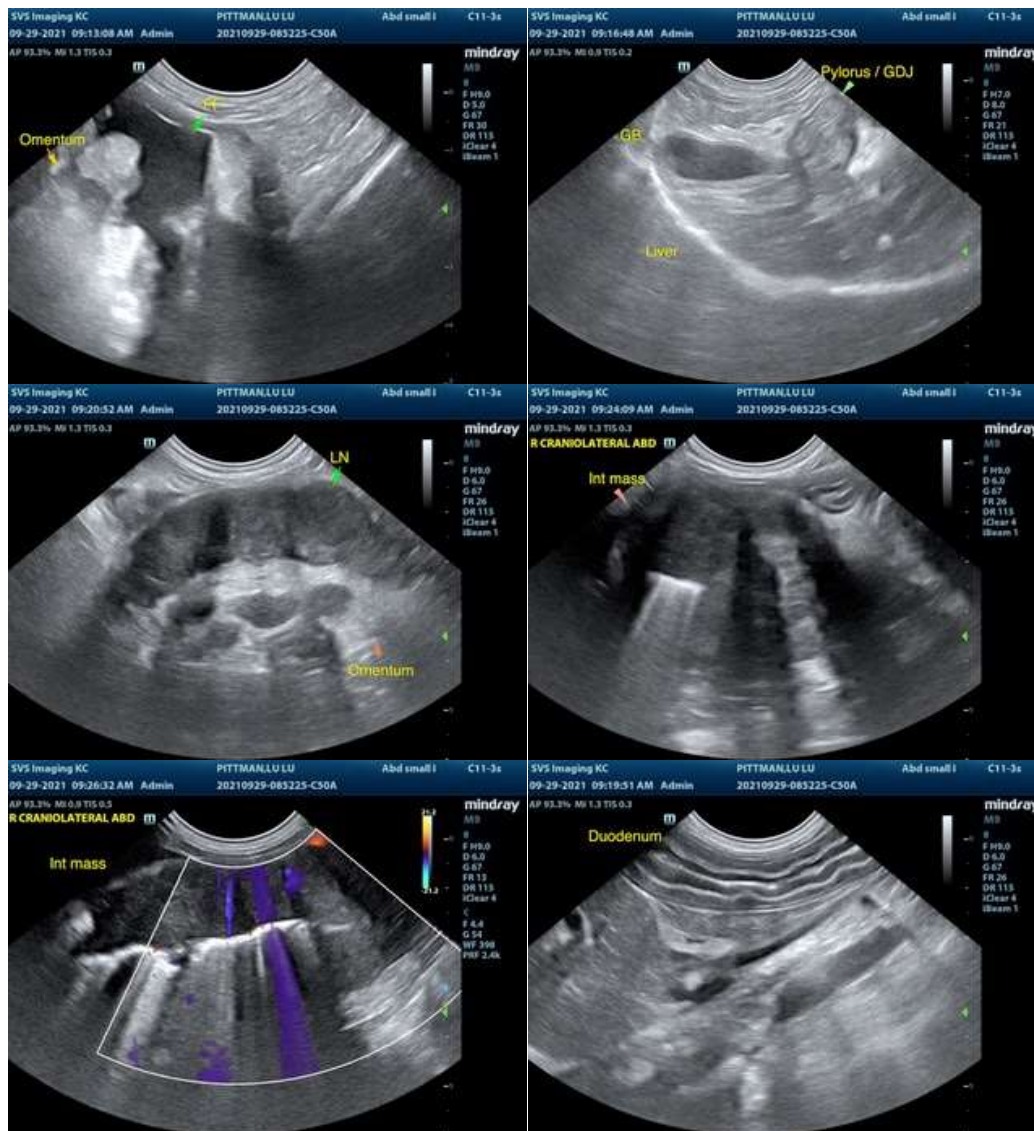
12342

DATE

9/29/21

INTERPRETATION OF THE FINDINGS & FURTHER RECOMMENDATIONS

Although sampling is required for further clarification, the appearance of the small intestine including the presence of large intestinal mural mass and concurrent lymphadenopathy is consistent with diffuse to multicentric neoplasia such as lymphoma, carcinoma, or other. The potential for hepatosplenic Involvement may be possible. Assuming normal clotting status, ultrasound guided FNA of the intestinal mural mass and lymph node with potential for oncology consultation may be considered. This case is nonsurgical. Overall, an unfavorable long-term prognosis is unfortunately indicated.





PATIENT

Lu lu Pittman

SPECIES

Canine

BREED

Shih tzu

SEX

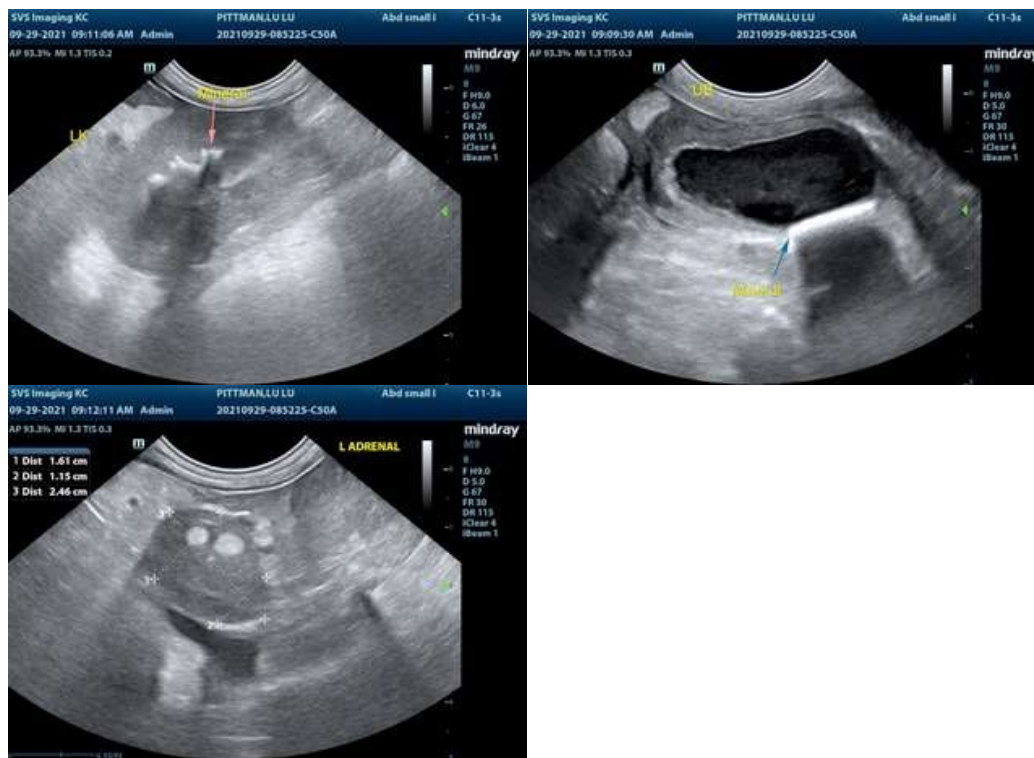
SF

AGE

13 years

WEIGHT

16 lbs



INTERPRETED BY

R. McKenzie Daniel,
DVM, DABVP
(Canine and Feline)

IMAGING PERFORMED BY

Rachel Runnells, RVT

HOSPITAL NAME

SVS Imaging KC

REFERRING VET

Dr. Johathon Renfro

INVOICE

12342

DATE

9/29/21

The information and recommendations provided are based on the images presented by the referring veterinarian. No evaluation can be communicated regarding pathology that was not visible in the image/video clips provided.

Thank you for this referral. If the clinical or image interpretation does not parallel your findings or if I can be of any further assistance please contact me.

R. McKenzie Daniel, DVM, DABVP (Canine / Feline Practice)
info@SonoPath.com