



PATIENT

Trig Allred

SPECIES

Canine

BREED

Pit Bull Mix

SEX

MN

AGE

12

WEIGHT

47 lbs.

INTERPRETED BY

R. McKenzie Daniel,
DVM, DABVP
(Canine and Feline)

IMAGING PERFORMED BY

Dr. Gromalak

HOSPITAL NAME

SVS Imaging

REFERRING VET

Dr. Beyer

INVOICE

12317

DATE

9/28/21

PRESENTING CLINICAL SIGNS

Heartworm positive currently undergoing treatment. looking into status of heart.

ULTRASONOGRAPHIC EXAMINATION OF THE HEART

CANINE CARDIAC PARAMETERS	MR VMAX (m/s)	TR VMAX (m/s)	LA/AO (Boon method)	LA/AO (Heart Base; Swe)	FS (%)	EF (%)	EPSS (cm)
NORMAL PARAMETER	4.5-5.5	<2.7	1.3	<1.6	28-40	40-100	<0.6
PATIENT			NM	2.0	35.7	66.7	0.27
CANINE CARDIAC PARAMETERS	HR (BPM)	AV VMAX (m/s)	PV MAX (m/s)	BODY WEIGHT (kg)	LA 2D short axis Base view (cm)	LVIDd Avg; 2D and m-mode short axis (cm)	LVIDs Avg; 2D and m-mode short axis (cm)
NORMAL PARAMETER	50-100	0.7-1.7	0.7-1.6	BELOW	BELOW	BELOW	BELOW
PATIENT	155	1.2	0.82		4.4	3.15	

Cardiac Presentation

The echocardiogram in this patient demonstrated mild excessive **left atrial** size based on 2 separate methods of LA evaluation. A large, nonhomogeneous heart base mass, which appears to be invading the left atrium lumen, was present, measuring approximately 5.0 cm x 3.2 cm. The cranial and caudal **mitral** valve leaflets presented normal linear structure, extension in systole, and union in diastole with normal kinesis. The **left ventricle** presented thicknesses with linear contour and was not dilated nor restricted. The **myocardium** presented normal echogenicity without subjective evidence of significant fibrotic or ischemic disease. **Contractility** of the ventricular walls was adequate and in normal range for this patient evidenced by the fractional shortening measurement and subjective evaluation of the different regions of the myocardium. The **left ventricular outflow** tract demonstrated normal laminar flow and subjective structural integrity. The **right atrium** and auricle revealed normal size, structure and content. No evidence of masses was noted. **Tricuspid** valvular assessment demonstrated adequate linear morphology and kinesis. The **right ventricle** was of normal size (1/3 diameter of LV), chordae structure, myocardial echogenicity and thickness. **Pulmonary outflow** tract assessment revealed normal valve structure, laminar flow, and diameter (approx. 1:1 pa/ao ratio). No visible **pericardial** or free pleura fluid was noted. The cranial **mediastinum and pericardial and extra-cardiac regions** were free of masses in the visible window.

ULTRASONOGRAPHIC FINDINGS

Primary Findings

- Large nonhomogeneous heart base mass appearing to invade the left atrium - consistent with neoplasia, hemangiosarcoma, chemodectoma or other possible



PATIENT

Trig Allred

SPECIES

Canine

BREED

Pit Bull Mix

SEX

MN

AGE

12

WEIGHT

47 lbs.

INTERPRETED BY

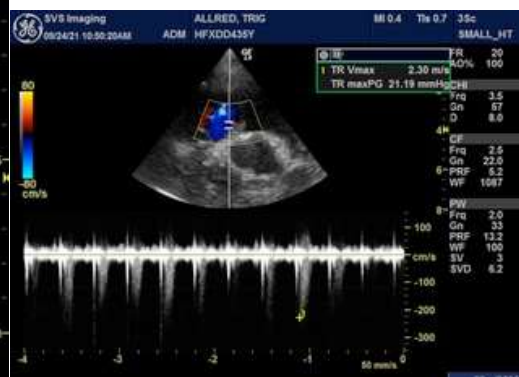
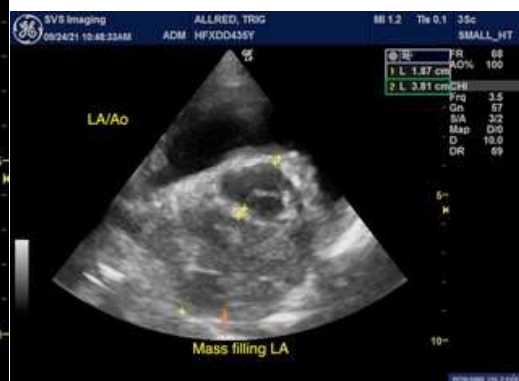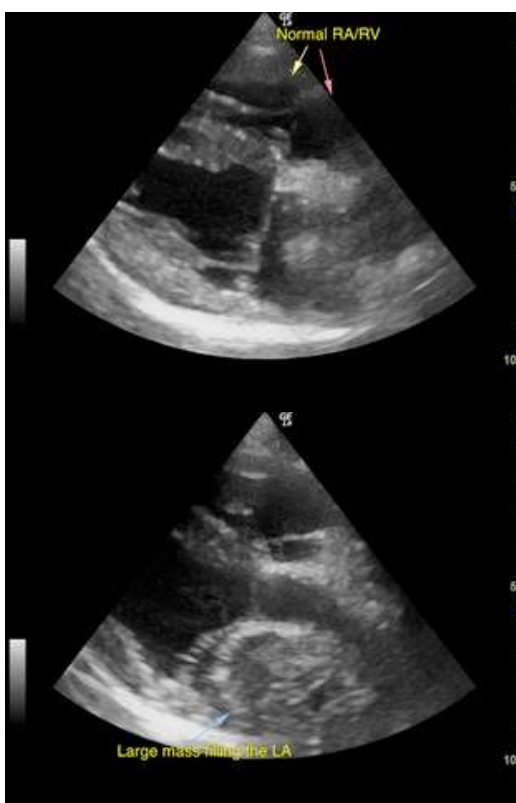
R. McKenzie Daniel, DVM, DABVP (Canine and Feline)

IMAGING PERFORMED BY

Dr. Gromalak

INTERPRETATION OF THE FINDINGS & FURTHER RECOMMENDATIONS

Unfortunately, the echocardiogram in this patient demonstrated a large heart base mass consistent with neoplasia appearing to invade the left atrium. If no clinical signs of pulmonary edema or collapse are present, this mass is not likely causing clinical signs at this time. However, an overall unfavorable long-term prognosis is indicated. Referral to a specialist, either cardiologist, oncologist, or surgeon could be considered in this case. However, therapeutic options are likely limited.



HOSPITAL NAME

SVS Imaging

REFERRING VET

Dr. Beyer

INVOICE

12317

DATE

9/28/21

The information and recommendations provided are based on the images presented by the referring veterinarian. No evaluation can be communicated regarding pathology that was not visible in the image/video clips provided.

Thank you for this referral. If the clinical or image interpretation does not parallel your findings or if I can be of any further assistance please contact me.

R. McKenzie Daniel, DVM, DABVP (Canine / Feline Practice)
info@SonoPath.com