



PATIENT

Ray Ciolkosz

SPECIES

Canine

BREED

Lab Mix

SEX

Male

AGE

3 Years

WEIGHT

72 Pounds

INTERPRETED BY

R. McKenzie Daniel,
DVM, DABVP
(Canine and Feline)

IMAGING PERFORMED BY

Jenn

HOSPITAL NAME

Rockaway AH

REFERRING VET

Dr. Maniar

INVOICE

13321

DATE

9/28/21

PRESENTING CLINICAL SIGNS

History: acute onset left leg swelling, anorexia, diarrhea

Abnormal PE/Chem/CBC/UA Results:

ULTRASONOGRAPHIC EXAMINATION OF THE ABDOMEN

Urinary System

The urinary bladder, trigone, cystourethral junction, and visible pelvic urethra to a depth of – cm exhibited normal thickness and tone. Anechoic urine was present in the lumen with no uroliths or sediment. The ureteral papillae were normal. The ureters were not visible which is normal. No evidence of inflammatory or neoplastic changes were noted.

No overt pathology in the area of the prostate.

No evidence of pathology in the area of the area of the aortic trifurcation, including no evidence of medial iliac or sublumbar lymphadenopathy as well as no evidence of caudal abdominal periaortic or pelvic masses.

Normal size and margination were present in the kidneys. A normal 1:3 cortex / medulla ratio and normal corticomedullary definition were maintained. The echogenicity of the cortex was similar to or slightly less than normal liver parenchyma while the medulla echogenicity was hypoechoic to the cortex with no evidence of pelvic dilation. The left kidney measured 6.7 cm in length. The right kidney measured 7.8 cm in length.

Adrenal Glands

The left adrenal gland was uniform in size and contour with a uniformly hypoechoic parenchyma. The left adrenal gland measured 0.60 cm width at the caudal pole and 0.54 cm width at the cranial pole.

The right adrenal gland was indistinctly visualized owing to patient size yet without overt pathology, subjectively measuring 0.60 cm at the cranial pole and 0.61 cm at the caudal pole.

Spleen

The spleen exhibited a finely textured and homogenous parenchyma which was hyperechoic to the liver and renal cortical parenchyma. The capsule was smooth and regular without apparent expansion. The splenic vasculature at the hilus was normal in volume with no evidence of congestion or thrombosis. Acute to chronic inflammatory, neoplastic, or benign parenchyma changes were not noted. The spleen was folded upon itself. No splenic masses or nodules noted.

Liver

The liver was subjectively normal in size, structure, and contour. The liver parenchyma was uniform and hypoechoic to the spleen with a mild coarse echotexture. The hepatic and portal vasculature were normal in appearance without signs of congestion. The gallbladder was non-distended in size with thin walls and primarily anechoic luminal content. The cystic and common bile ducts were normal.

Gastrointestinal

The stomach presented intact wall layering with a normal wall layer ratio. The lumen of the stomach was empty with no signs of ileus, obstruction or foreign material.



PATIENT

Ray Ciolkosz

The small intestine presented intact wall layering with 1:3 muscularis/mucosa ratio. The lumen of the small intestine was empty with no signs of ileus, obstruction or foreign material.

Normal visible colon wall layers were present with apparent formed feces in lumen.

SPECIES

Pancreas

Canine

The parenchyma of the left limb, body and right limb of the pancreas presented isoechoic to the adjacent omental fat. A normal curvilinear capsule contour of the pancreas was present. The visible pancreatic duct was normal. No signs of active inflammation or neoplastic disease was evident.

BREED

Free Abdomen

Lab Mix

No overt lymphadenopathy or peritoneal effusion was present.

SEX

ULTRASONOGRAPHIC FINDINGS

Male

- Sonographically unremarkable abdomen
- Mild splenic folding- not indicative of underlying splenic pathology, likely patient variant

AGE

INTERPRETATION OF THE FINDINGS & FURTHER RECOMMENDATIONS

3 Years

No overt evidence of visceral pathology as well as no evidence of caudal abdominal retroperitoneal or pelvic masses as the potential cause of acute left leg swelling. Continued as needed gastrointestinal support is recommended.

WEIGHT

72 Pounds

INTERPRETED BY

R. McKenzie Daniel,
DVM, DABVP
(Canine and Feline)

IMAGING PERFORMED BY

Jenn

HOSPITAL NAME

Rockaway AH

REFERRING VET

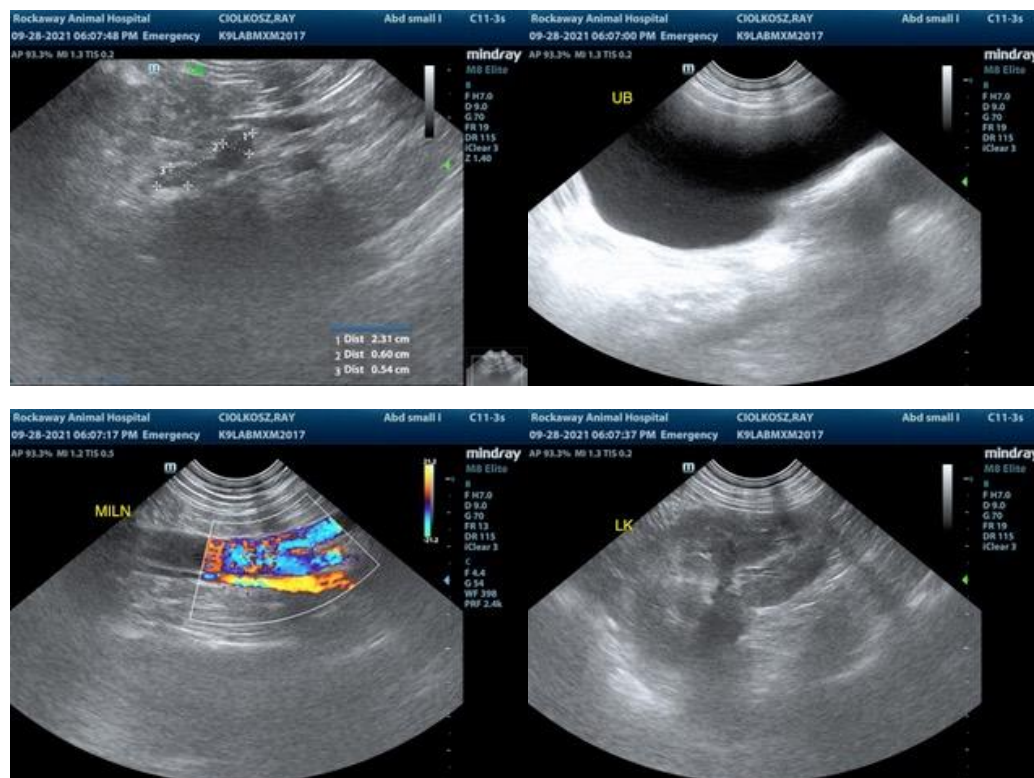
Dr. Maniar

INVOICE

13321

DATE

9/28/21





PATIENT

Ray Ciolkosz

SPECIES

Canine

BREED

Lab Mix

SEX

Male

AGE

3 Years

WEIGHT

72 Pounds

INTERPRETED BY

R. McKenzie Daniel,
DVM, DABVP
(Canine and Feline)

IMAGING PERFORMED BY

Jenn

HOSPITAL NAME

Rockaway AH

REFERRING VET

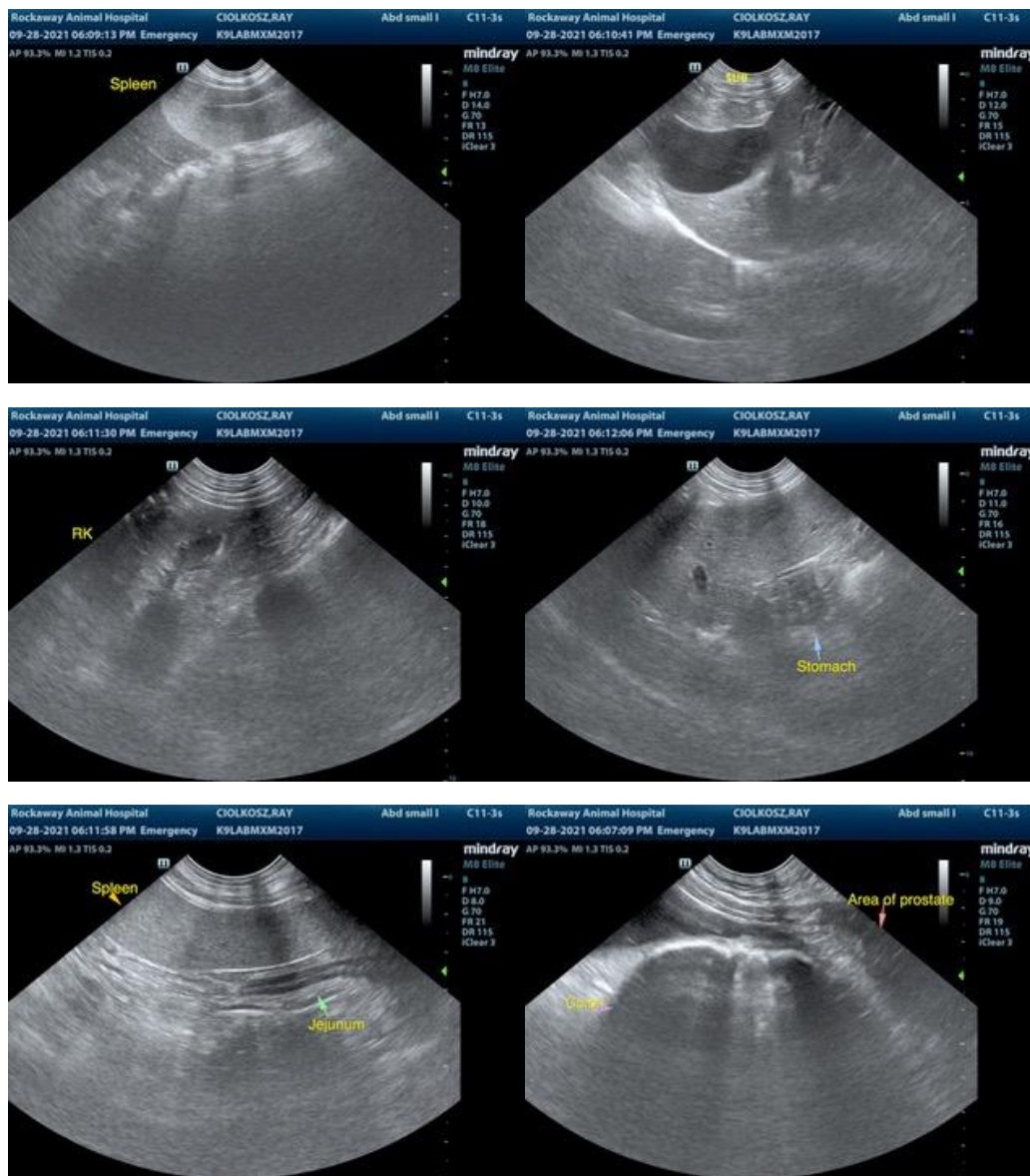
Dr. Maniar

INVOICE

13321

DATE

9/28/21



The information and recommendations provided are based on the images presented by the referring veterinarian. No evaluation can be communicated regarding pathology that was not visible in the image/video clips provided.

Thank you for this referral. If the clinical or image interpretation does not parallel your findings or if I can be of any further assistance please contact me.

R. McKenzie Daniel, DVM, DABVP (Canine / Feline Practice)
info@SonoPath.com