



PATIENT

Zoey
Husky/Shepherd

SPECIES

Feline

BREED

DLH

SEX

FS

AGE

12 years

WEIGHT

13.3

INTERPRETED BY

R. McKenzie Daniel,
DVM, DABVP
(Canine and Feline)

**IMAGING
PERFORMED BY**

Jenna Walsh, CVT

HOSPITAL NAME

West Eugene AH

REFERRING VET

Dr. Powers

INVOICE

13309

DATE

9/27/21

PRESENTING CLINICAL SIGNS

History of picky appetite and increased hiding for the past 6 months. O has noticed abdominal distention more recently. Frequently vomits hairballs, but this is not new per O. No diarrhea. Normal drinking/urination. Indoor only. Mild tachypnea during exam (50), but otherwise heart/lungs auscult WNL. Abdomen moderate-markedly distended; unable to palpate of specific structures through the distention.

ULTRASONOGRAPHIC EXAMINATION OF THE ABDOMEN

Urinary System

The urinary bladder, trigone, cystourethral junction, and visible pelvic urethra to a depth of 2.0 cm exhibited normal thickness and tone. Anechoic urine was present in the lumen with no uroliths or sediment. The ureteral papillae were normal. The ureters were not visible which is normal. No evidence of inflammatory or neoplastic changes was noted.

Normal size and margination were present in the kidneys. A normal 1:3 cortex / medulla ratio and normal corticomedullary definition were maintained. The echogenicity of the cortex was similar to or slightly less than normal liver parenchyma while the medulla echogenicity was hypoechoic to the cortex with no evidence of pelvic dilation. The left kidney measured 3.6 cm in length. The right kidney measured 3.8 cm in length.

Adrenal Glands

The left adrenal gland was uniform in size and contour with a uniformly hypoechoic parenchyma. The left adrenal gland measured 0.35 cm width.

The right adrenal gland was uniform in size and contour with a uniformly hypoechoic parenchyma. The right adrenal gland measured 0.40 cm width.

Spleen

The spleen exhibited a finely textured and homogenous parenchyma which was hyperechoic to the liver and renal cortical parenchyma. The capsule was smooth and regular without apparent expansion. The splenic vasculature at the hilus was normal in volume with no evidence of congestion or thrombosis. Acute to chronic inflammatory, neoplastic, or benign parenchyma changes were not noted.

Liver/ Gallbladder

The liver was subjectively normal in size, structure, and contour. The liver parenchyma was uniform and hypoechoic to the spleen with a mild coarse echotexture. The hepatic and portal vasculature were normal in appearance without signs of congestion. The gallbladder was non-distended in size with thin walls and primarily anechoic luminal content. The cystic and common bile ducts were normal.

Gastrointestinal



PATIENT

The stomach presented intact wall layering with a normal wall layer ratio. The lumen of the stomach was empty with mild luminal gas. No evidence of hairball density, retained ingesta or fluid.

Zoey

The small intestine exhibited intact wall layering and primarily maintained 1:3 muscularis/mucosa ratio with segmental propensity for mildly prominent muscularis layer along with intermittent potential jejunal spasming indicated by subtle jejunal corrugation. The jejunum wall measured 0.27 cm wall width.

SPECIES

Feline

BREED

DLH

SEX

FS

AGE

12 years

WEIGHT

13.3

Normal visible colon wall layers were present with apparent formed feces in lumen.

Pancreas

The parenchyma of the left limb, body, and right limb of the pancreas presented isoechoic to the adjacent omental fat. A normal curvilinear capsule contour of the pancreas was present. The visible pancreatic duct was normal. No signs of active inflammation or neoplastic disease were evident.

Free Abdomen

A moderate amount of intraabdominal fat was present. No evidence of omental lymphadenopathy, masses or peritoneal effusion.

ULTRASONOGRAPHIC FINDINGS

- Potential mild inflammatory enteropathy
- Subjective moderate intraabdominal fat-no evidence of lymphadenopathy, masses or effusion

INTERPRETED BY

R. McKenzie Daniel,
DVM, DABVP
(Canine and Feline)

INTERPRETATION OF THE FINDINGS & FURTHER RECOMMENDATIONS

The small intestine exhibited potential for subtle mural changes which may suggest underlying inflammatory enteropathy. However, given the lack of reported gastrointestinal signs or weight loss this is a non-specific finding. Otherwise, no overt evidence of intraabdominal pathology with subjective increased omental fat present.

IMAGING PERFORMED BY

Jenna Walsh, CVT

Continued monitoring for gastrointestinal signs and/or weight loss is suggested.

HOSPITAL NAME

West Eugene AH

REFERRING VET

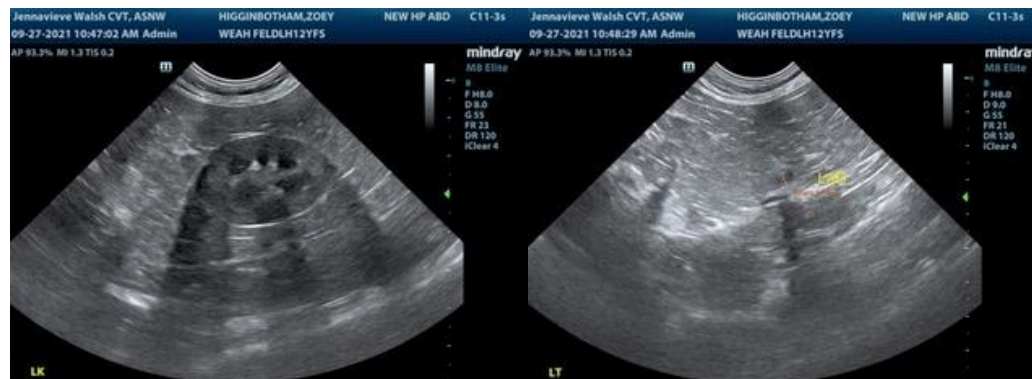
Dr. Powers

INVOICE

13309

DATE

9/27/21





PATIENT

Zoey
Higginbotham

SPECIES

Feline

BREED

DLH

SEX

FS

AGE

12 years

WEIGHT

13.3

INTERPRETED BY

R. McKenzie Daniel,
DVM, DABVP
(Canine and Feline)

IMAGING PERFORMED BY

Jenna Walsh, CVT

HOSPITAL NAME

West Eugene AH

REFERRING VET

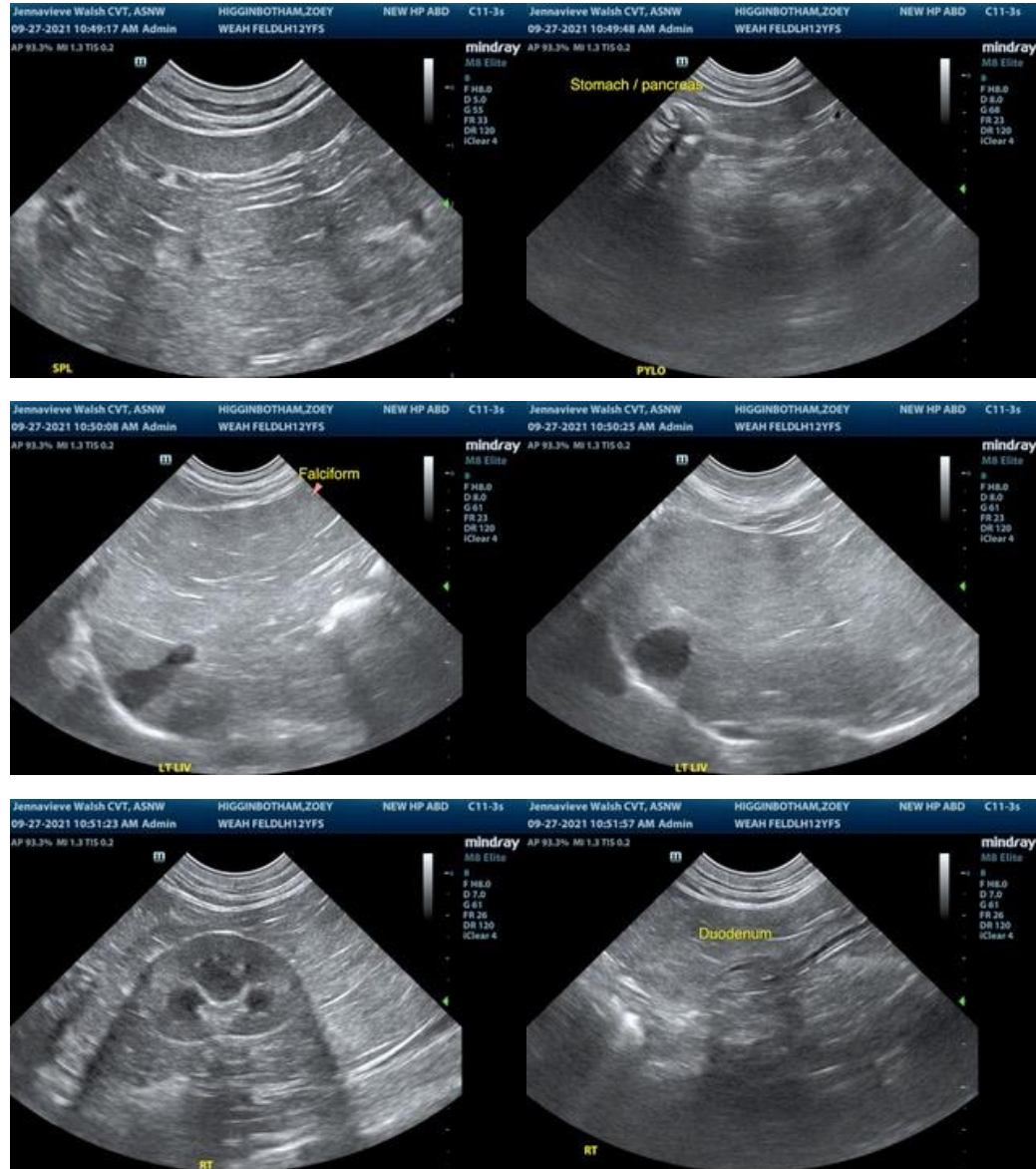
Dr. Powers

INVOICE

13309

DATE

9/27/21





PATIENT

Zoey
Higginbotham

SPECIES

Feline

BREED

DLH

SEX

FS

AGE

12 years

WEIGHT

13.3

INTERPRETED BY

R. McKenzie Daniel,
DVM, DABVP
(Canine and Feline)

IMAGING PERFORMED BY

Jenna Walsh, CVT

HOSPITAL NAME

West Eugene AH

REFERRING VET

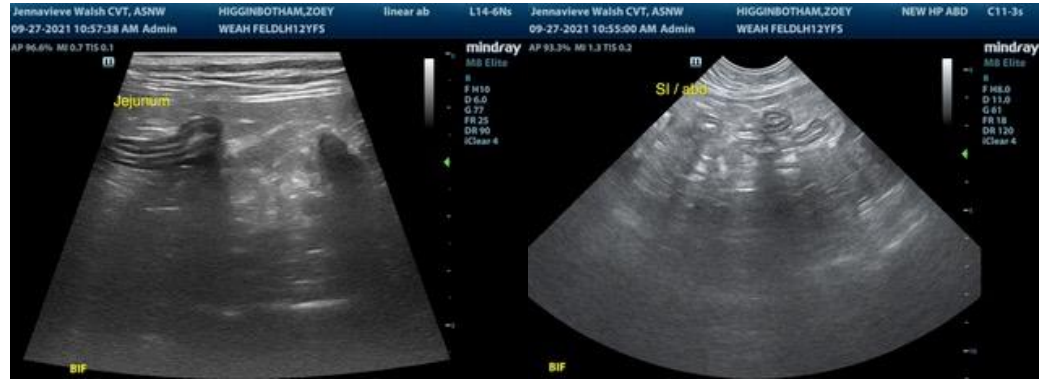
Dr. Powers

INVOICE

13309

DATE

9/27/21



The information and recommendations provided are based on the images presented by the referring veterinarian. No evaluation can be communicated regarding pathology that was not visible in the image/video clips provided.

Thank you for this referral. If the clinical or image interpretation does not parallel your findings or if I can be of any further assistance please contact me.

R. McKenzie Daniel, DVM, DABVP (Canine / Feline Practice)
info@SonoPath.com