



**PATIENT**

Boots Hollomon

**SPECIES**

Feline

**BREED**

DLH

**SEX**

Spayed Female

**AGE**

1 Year

**WEIGHT**

5 Pounds

**INTERPRETED BY**

R. McKenzie Daniel,  
DVM, DABVP  
(Canine and Feline)

**IMAGING PERFORMED BY**

Amanda Crook – SDEP  
Certified Clinical  
Sonographer

**HOSPITAL NAME**

Rivers Edge Pet  
Medical Center

**REFERRING VET**

Dr. Cora Hollomon

**INVOICE**

25827

**DATE**

9/27/21

**PRESENTING CLINICAL SIGNS**

Current History: Suspected UTI about 2 weeks ago, was put on clavamox and symptoms resolved but then similar symptoms represented yesterday. Acute onset of lethargy and pollakiuria 2 days ago with large kidney on palpation. Previous History: Hx of suspected toxoplasmosis, was treated successfully with 4 weeks of clindamycin. Has persistent pelvic limb neuromuscular deficits that have been slowly improving. Pelvic nerve issues, can urinate and defecate on her own but unable to posture due to weakness so pt is easily stimulated to eliminate on a regular schedule. Hx of uveitis in left eye, now non-visual. Current Medications: gabapentin PRN, neopolydex OS PRN

Abnormal PE/Chem/CBC/UA Results: See attached radiographs - decreased detail in abdomen, concern for abdominal effusion (retroperitoneal effusion seen on FAST scan). possible mild bronchial pattern in lungs. normal formed stool and gas in colon. See attached lab work - CBC: RBC 3.86, HCT 14.8%, HGB 5.5, MCHC 37.2, WBC 18.44, Neu 1.59, Lum 15.92, Mono 0.86, Eos 0.02, PLT 114 CHEM: TP >12.0, remainder of chem WNL UA: TNTC RBC, WBC, rods, cocci. 2+ struvite

**ULTRASONOGRAPHIC EXAMINATION OF THE ABDOMEN**

**Urinary System**

The urinary bladder was normal in size and overall tone. Ventral to ventral apical mural thickening to lesion exhibiting isoechoic echogenicity and without evidence of mural mineralization was present measuring approximately 4.7 cm x 2.6 cm. Minor particulate sediment was present. No calculi. The urethra was normal in structure and tone to a depth of 2.0 cm.

The left kidney exhibited severe enlargement (6.6 cm) with moderately hyperechoic renal cortex and medulla echogenicity. A hypoechoic halo was present at the periphery of the cortex. Mild dilation of the renal diverticuli was present. Subcapsular fluid was noted around the left kidney, suggestive of hypoechoic halo with concurrent potential cyst-like lesion. Associated left retroperitonitis extending caudally was present. Mild pyelectasia noted. Non-uniform appearance of the retroperitoneal space noted primarily around the left kidney with concurrent effusion extending caudally into the area of the iliac trifurcation.

The right kidney was also enlarged, yet not as severely as the left kidney, measuring 5.1 cm. A normal 1:3 cortex / medulla ratio and normal corticomedullary definition were maintained. The echogenicity of the cortex was similar to or slightly less than normal liver parenchyma while the medulla echogenicity was hypoechoic to the cortex with no evidence of pelvic dilation. A hyperechoic corticomedullary band, consistent with a medullary rim sign, was present. This is a nonspecific finding seen in both normal and abnormal kidneys. It may be associated interstitial renal disease, hypercalcemia, tubular necrosis, lymphoma, and FIP. However, it is a nonspecific finding. Mild pyelectasia noted. Potential for concurrent mild subcapsular fluid noted around the periphery of the right kidney versus minor concurrent retroperitoneal free fluid.

**Adrenal Glands**

The left adrenal gland was not definitively visualized given the left renomegaly.

The right adrenal gland was uniform in size and contour with a uniformly hypoechoic parenchyma. The right adrenal gland measured 0.43 cm.

**Spleen**

The spleen was mildly enlarged (1.2 cm in width at the level of the hilus) and exhibited a finely textured and homogenous parenchyma which was hyperechoic to the liver and renal cortical parenchyma. The capsule was smooth and regular without apparent expansion. The splenic vasculature at the hilus was normal in volume with no evidence of congestion or thrombosis. Acute to chronic inflammatory, neoplastic, or benign parenchyma changes were not noted.



**PATIENT**

*Liver*

Boots Hollomon

**SPECIES**

Feline

The liver was subjectively normal in size, structure, and contour. The liver parenchyma was mildly nonuniform and hypoechoic to the spleen with a moderate coarse echotexture and subjective mild to benign parenchymal remodeling. The hepatic and portal vasculature were normal in appearance without signs of congestion. The gallbladder was non-distended in size with thin walls and primarily anechoic luminal content. The cystic and common bile ducts were normal.

**BREED**

DLH

**Gastrointestinal**

The stomach presented intact wall layering with a normal wall layer ratio. The lumen of the stomach contained echogenic, nonshadowing ingesta most consistent with post prandial presentation without signs of ileus, obstruction or foreign material.

**SEX**

Spayed Female

The small intestine presented intact wall layering with 1:3 muscularis/mucosa ratio. The lumen of the small intestine was empty with no signs of ileus, obstruction or foreign material.

Normal visible colon wall layers were present with apparent formed feces in lumen.

**AGE**

1 Year

**Pancreas**

The pancreas was normal in size and contour. The left limb, right limb, and base of the pancreas presented hypoechoic to heterogeneous echogenicity compared to adjacent omental fat. Mild asymmetrical capsule margination was present with mild variable parenchymal swelling and mild peripancreatic inflammation. No overt evidence of neoplasia.

**WEIGHT**

5 Pounds

**Free Abdomen**

Several mildly enlarged medial iliac lymph nodes were present. Example measured 0.5 cm in width. These lymph nodes were homogenous, mildly hypoechoic and smoothly margined. A normal width:length ratio was maintained (<0.5). Evidence of perilymphatic inflammation was evident.

Concurrent small pockets of peritoneal free fluid were noted primarily in the cranial mid abdomen around the liver and in between intestinal loops.

**INTERPRETED BY**

R. McKenzie Daniel,  
DVM, DABVP  
(Canine and Feline)

**IMAGING PERFORMED BY**

Amanda Crook – SDEP  
Certified Clinical  
Sonographer

**HOSPITAL NAME**

Rivers Edge Pet  
Medical Center

**REFERRING VET**

Dr. Cora Hollomon

**PRIMARY FINDINGS**

- Left kidney severe renomegaly with nonuniform corticomedullary echogenicity, subcapsular fluid versus cyst-like lesion and associated retroperitonitis.
- Right kidney renomegaly with medullary rim sign and potential for concurrent subcapsular fluid versus concurrent minor retroperitonitis.
- Ventral urinary bladder mural thickening to mass lesion
- Non-specific mild splenomegaly
- Small pockets of concurrent peritoneal free fluid

**SECONDARY FINDINGS**

- Gastric ingesta – consistent with post-prandial presentation
- Possible low-grade pancreatitis versus patient variant
- Non-specific minor medial iliac lymphadenopathy

**INVOICE**

25827

**DATE**

9/27/21



**PATIENT**

Boots Hollomon

**SPECIES**

Feline

**BREED**

DLH

**SEX**

Spayed Female

**AGE**

1 Year

**WEIGHT**

5 Pounds

**INTERPRETED BY**

R. McKenzie Daniel,  
DVM, DABVP  
(Canine and Feline)

**IMAGING PERFORMED BY**

Amanda Crook – SDEP  
Certified Clinical  
Sonographer

**HOSPITAL NAME**

Rivers Edge Pet  
Medical Center

**REFERRING VET**

Dr. Cora Hollomon

**INVOICE**

25827

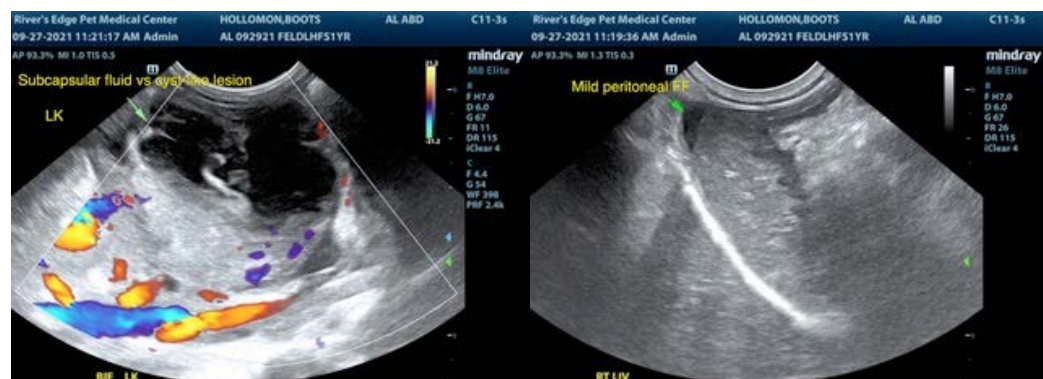
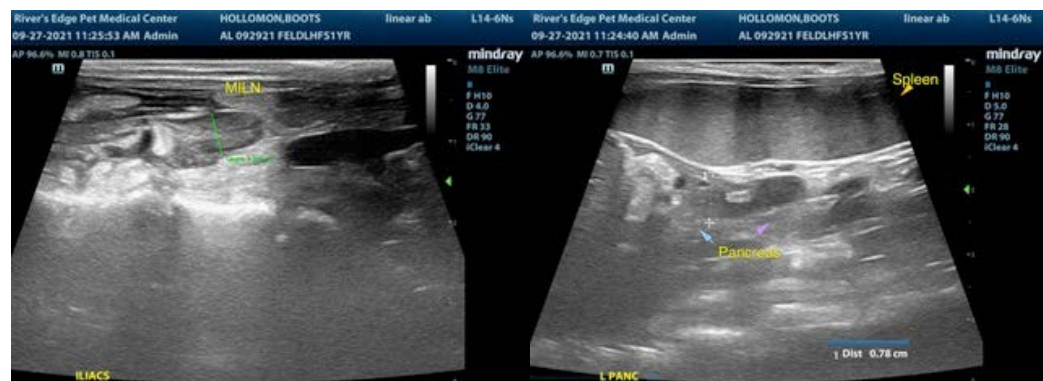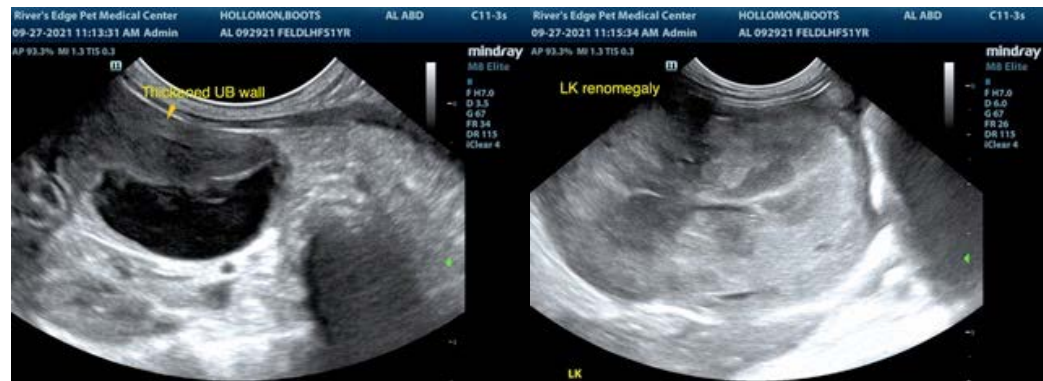**DATE**

9/27/21

**INTERPRETATION OF THE FINDINGS & FURTHER RECOMMENDATIONS**

Although sampling is required for further clarification, there is primary concern for primarily left, yet bilateral renal neoplasia with potential for multicentric neoplasia involving the urinary bladder or possible early hepatosplenic involvement. Primary concern for multicentric lymphoma versus other neoplasia. The potential for non-neoplastic etiologies such as bilateral severe non-specific nephritis, granulomatous nephritis, or other possible yet considered less likely.

Assuming normal clotting status, ultrasound guided FNA of the left renal cortex +/- hepatosplenic screening FNA using 25-gauge needle warranted for screening cytology. Recheck retroviral status as well as CBC pathology review +/- flow cytometry given the lymphocytosis may be considered. Very guarded prognosis.





**PATIENT**

Boots Hollomon

**SPECIES**

Feline

**BREED**

DLH

**SEX**

Spayed Female

**AGE**

1 Year

**WEIGHT**

5 Pounds

**INTERPRETED BY**

R. McKenzie Daniel,  
DVM, DABVP  
(Canine and Feline)

**IMAGING  
PERFORMED BY**

Amanda Crook – SDEP  
Certified Clinical  
Sonographer

**HOSPITAL NAME**

Rivers Edge Pet  
Medical Center

**REFERRING VET**

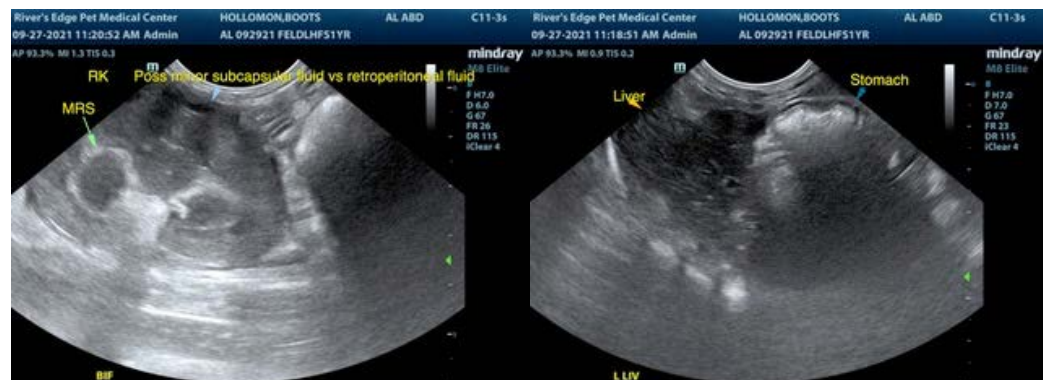
Dr. Cora Hollomon

**INVOICE**

25827

**DATE**

9/27/21



The information and recommendations provided are based on the images presented by the referring veterinarian. No evaluation can be communicated regarding pathology that was not visible in the image/video clips provided.

Thank you for this referral. If the clinical or image interpretation does not parallel your findings or if I can be of any further assistance please contact me.

**R. McKenzie Daniel, DVM, DABVP (Canine / Feline Practice)**  
info@SonoPath.com