



PATIENT PRESENTING CLINICAL SIGNS

Eden Gaian Seen HREVC 09/24/2022 for Hx IBD, black vomitus. Was being managed by rDVM for IBD flare-up, on prednisolone, mirtazapine, cerenia, fortiflora, P was improving until vomiting became black (went from daily to weekly vomiting). meds: Unsure of dosing - prednisolone, mirtazapine, cerenia, fortiflora.

SPECIES ULTRASONOGRAPHIC EXAMINATION OF THE ABDOMEN

Feline

Urinary System

BREED

Bengal

The urinary bladder, trigone, cystourethral junction, and visible pelvic urethra to a depth of 2.0 cm exhibited normal thickness and tone. Anechoic urine was present in the lumen with no uroliths or sediment. The ureteral papillae were normal. The ureters were not visible which is normal. No evidence of inflammatory or neoplastic changes were noted.

SEX

Spayed Female

The area of the aortic trifurcation was free of pathology.

AGE

16 Years

Normal size and margination were present in the kidneys. A normal 1:3 cortex / medulla ratio was maintained. The medulla and cortices were uniform in texture with some increased echogenicity and loss of corticomedullary symmetry and definition expected for the age of the patient. No evidence of pelvic dilation was present. The right kidney revealed focal to intermittent cortical infarcts. The left kidney measured 4.4 cm. The right kidney measured 3.8 cm.

Adrenal Glands

WEIGHT

9 Pounds

Both adrenal glands were indistinctly visualized, potentially owing to subnormal size secondary to Prednisolone therapy. The right adrenal gland measured 0.26 cm. The left adrenal gland measured 0.24 cm.

INTERPRETED BY Spleen

R. McKenzie Daniel,
DVM, DABVP
(Canine and Feline)

The spleen exhibited a finely textured and homogenous parenchyma which was hyperechoic to the liver and renal cortical parenchyma. The capsule was smooth and regular without apparent expansion. The splenic vasculature at the hilus was normal in volume with no evidence of congestion or thrombosis. Acute to chronic inflammatory, neoplastic, or benign parenchyma changes were not noted.

IMAGING PERFORMED BY

Kelly Reschny

Liver

HOSPITAL NAME

Hamilton Region VEC

The liver was subjectively normal in size, structure, and contour. The liver parenchyma was mildly nonuniform and hypoechoic to the spleen with a moderate coarse echotexture and subjective mild to benign parenchymal remodeling. A solitary, well demarcated, non-disruptive, uniform hyperechoic intraparenchymal nodule was noted measuring 0.69 cm in diameter. The hepatic and portal vasculature were normal in appearance without signs of congestion. The gallbladder was non-distended in size with thin walls and primarily anechoic luminal content. The cystic and common bile ducts were normal.

REFERRING VET

Dr. Vercaigne

Gastrointestinal

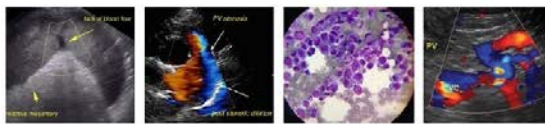
INVOICE

41663

The gastric walls were moderately thickened, exhibiting asymmetrical luminal surface contour, decreased mural echogenicity, and loss discernable gastric wall layer detail, subjectively involving the gastric body, extending into the area of the pylorus/antrum. Concurrent retained mild gastric fluid, luminal gas, and potential for focal shadowing ingesta, which may suggest concurrent paralytic gastric stasis. Gastric wall measured up to 1.6 cm in width. Regional mild hyperechoic perigastric mesentery was noted with intermittent small pocket of perigastric free fluid. No obvious evidence of concurrent gastric or cranial mesenteric lymphadenopathy.

DATE

9/26/22



PATIENT

Eden Gaian

The small intestine presented intact wall layering with 1:3 muscularis/mucosa ratio. The lumen of the small intestine was empty with no signs of ileus, obstruction or foreign material.

Normal visible colon wall layers were present with apparent formed feces in lumen.

SPECIES

Feline

Pancreas

The parenchyma of the left limb, body and right limb of the pancreas presented isoechoic to the adjacent omental fat. A normal curvilinear capsule contour of the pancreas was present. The visible pancreatic duct was normal. No signs of active inflammation or neoplastic disease was evident.

BREED

Bengal

ULTRASONOGRAPHIC FINDINGS

SEX

Spayed Female

- Regional moderate gastric wall thickening/gastric mural mass exhibiting decreased mural echogenicity and loss of wall layer detail – sonographically consistent with infiltrative neoplasia i.e., gastric lymphoma or other.
- Bilateral chronic renal changes with right kidney cortical infarcts
- Probable benign hepatic intraparenchymal nodule – suggestive of focal nodular hyperplasia or small lipogranuloma.

AGE

16 Years

INTERPRETATION OF THE FINDINGS & FURTHER RECOMMENDATIONS

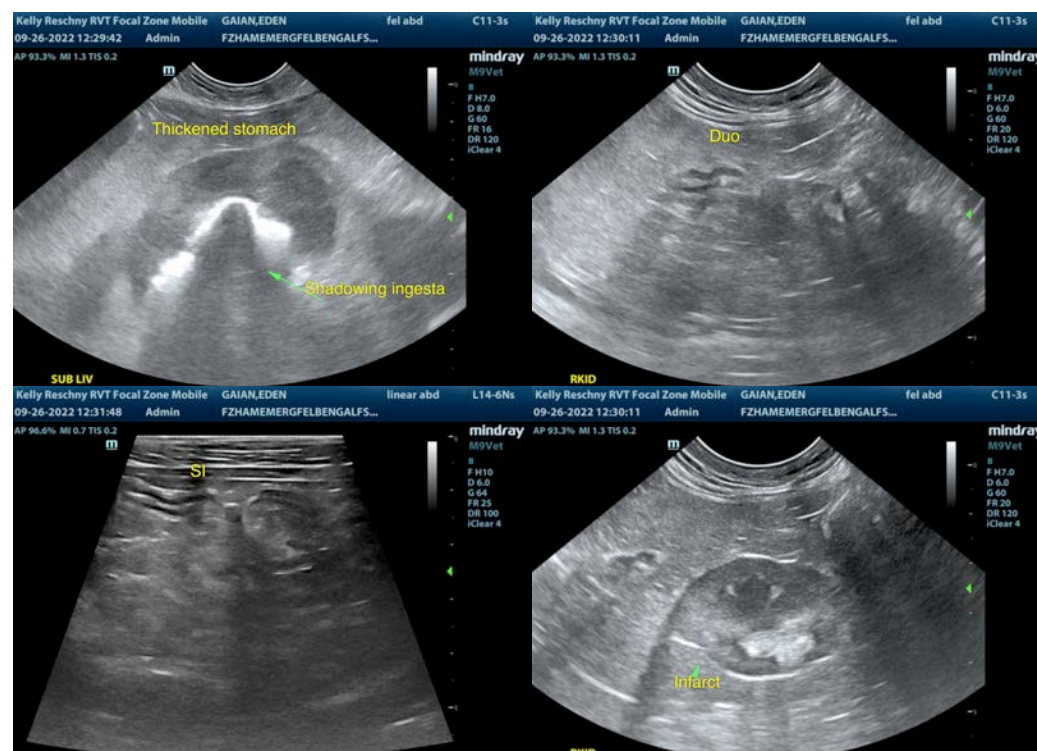
WEIGHT

9 Pounds

Ultrasound guided FNA of the thickened stomach, assuming normal clotting status and using 25-gauge needle is recommended for further assessment and potential for oncology consult. Suspect potential ulceration associated with a gastric neoplastic process. Empirically, as needed gastroprotectants and gastrointestinal support warranted. Potential for focal non-obstructive shadowing gastric foreign body yet considered unlikely. Unfortunately, unfavorable long-term prognosis indicated.

INTERPRETED BY

R. McKenzie Daniel,
DVM, DABVP
(Canine and Feline)



IMAGING PERFORMED BY

Kelly Reschny

HOSPITAL NAME

Hamilton Region VEC

REFERRING VET

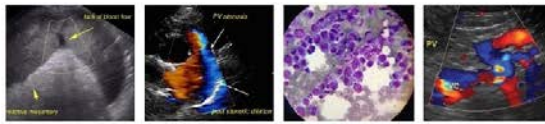
Dr. Vercaigne

INVOICE

41663

DATE

9/26/22



PATIENT

Eden Gaian

SPECIES

Feline

BREED

Bengal

SEX

Spayed Female

AGE

16 Years

WEIGHT

9 Pounds

INTERPRETED BY

R. McKenzie Daniel,
DVM, DABVP
(Canine and Feline)

IMAGING PERFORMED BY

Kelly Reschny

HOSPITAL NAME

Hamilton Region VEC

REFERRING VET

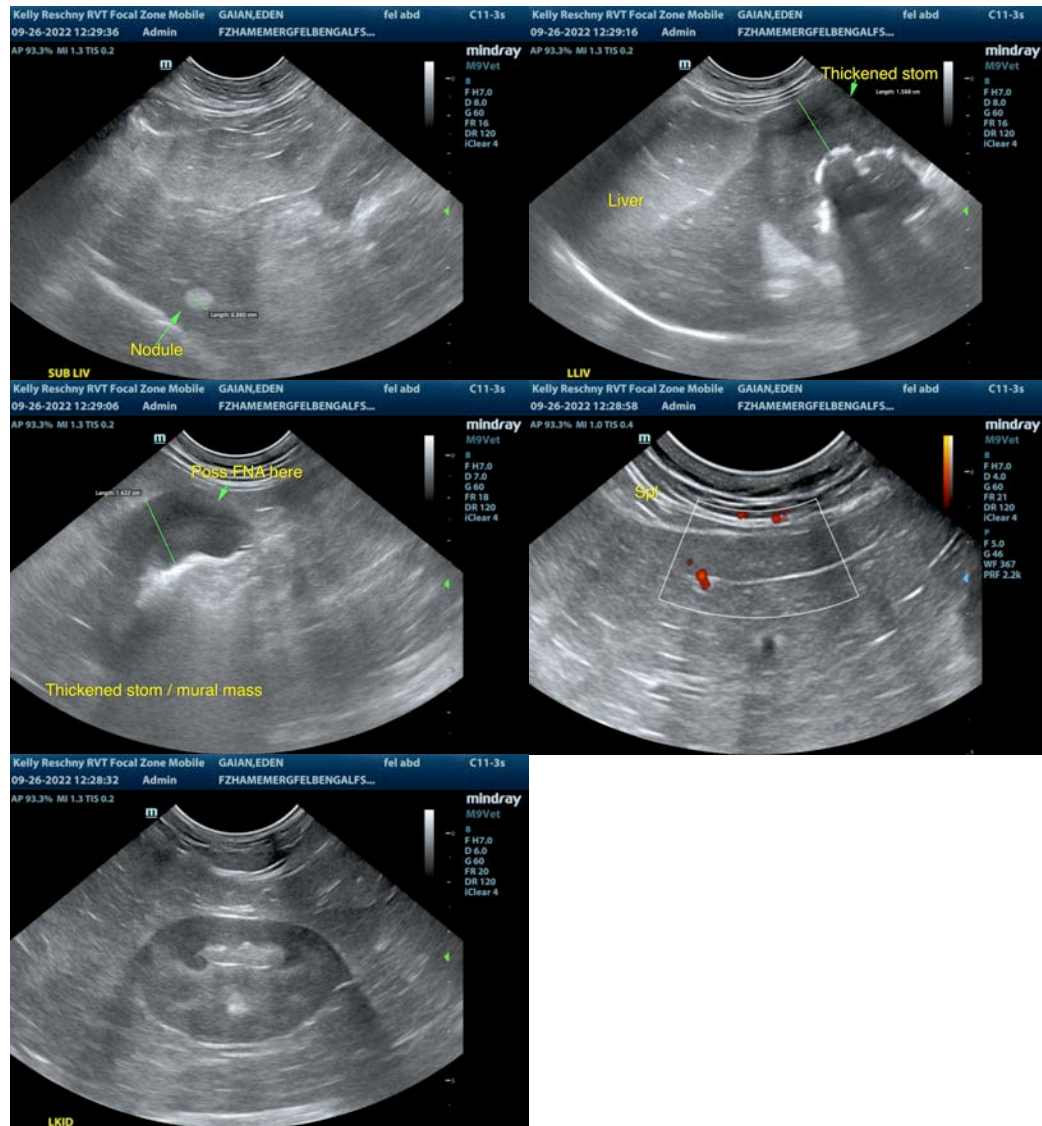
Dr. Vercaigne

INVOICE

41663

DATE

9/26/22



The information and recommendations provided are based on the images presented by the referring veterinarian/sonographer. No evaluation can be communicated regarding pathology that was not visible in the image/video clips provided.

Thank you for this referral. If the clinical or image interpretation does not parallel your findings or if I can be of any further assistance please contact me.

R. McKenzie Daniel, DVM, DABVP (Canine / Feline Practice)
info@SonoPath.com