



PATIENT

Ella Nunes

SPECIES

Canine

BREED

Yorkie

SEX

FS

AGE

12 years

WEIGHT

3.6 kg

PRESENTING CLINICAL SIGNS

Organomegaly, suspect liver on rads. Has had history of vomiting and diarrhea. No meds currently. Recently finished Metronidazole.

Abnormal PE/Chem/CBC/UA Results: Normal CPLi, M1 elevated ALT.

ULTRASONOGRAPHIC EXAMINATION OF THE ABDOMEN

Urinary System

The urinary bladder, trigone, and cystourethral junction exhibited normal thickness and tone. Anechoic urine was present in the lumen with no uroliths or sediment. The ureteral papillae were normal. The ureters were not visible which is normal. No evidence of inflammatory or neoplastic changes was noted.

The area of the aortic trifurcation was free of pathology.

Normal size and margination were present in the kidneys. A normal 1:3 cortex / medulla ratio was maintained. The medulla and cortices were uniform in texture with some increased echogenicity and moderate loss of corticomedullary symmetry and definition expected for the age of the patient. No evidence of pelvic dilation was present. Pinpoint to focal minor areas of medullary mineral were noted. Left kidney cortical cysts were present. The left kidney measured 3.3 cm in length. The right kidney measured 3.6 cm in length.

Adrenal Glands

The bilateral adrenal glands were normal in size. Mild parenchyma heterogeneity and mild capsule asymmetry was present without suspicion for overt neoplasia. The left adrenal gland measured 0.52 cm width in the cranial pole and 0.43 cm width in the caudal pole. The right adrenal gland measured 0.59 cm width in the caudal pole. No evidence of adrenomegaly or tumors.

Spleen

The spleen exhibited a finely textured and homogenous parenchyma which was hyperechoic to the liver and renal cortical parenchyma. The capsule was smooth and regular without apparent expansion. The splenic vasculature at the hilus was normal in volume with no evidence of congestion or thrombosis. Acute to chronic inflammatory, neoplastic, or benign parenchyma changes were not noted.

Liver/ Gallbladder

The liver presented enlarged in size. The parenchyma of the liver was subjectively normal in echogenicity compared to the spleen and renal cortices. The liver parenchyma was uniform with a mildly coarse echotexture. The capsule of the liver was symmetrically rounded to mildly swollen in margination. The hepatic and portal vasculature were normal in appearance without signs of congestion.

The gallbladder was non-distended in size with mild, primarily dependent, mildly hyperechoic gallbladder debris. No evidence of gallbladder or peripheral gallbladder inflammatory criteria was noted. The cystic and common bile ducts were normal.

INTERPRETED BY

R. McKenzie Daniel,
DVM, DABVP

IMAGING PERFORMED BY

Crystal Hill

HOSPITAL NAME

Hawkins AH

REFERRING VET

Dr. Hawkins

INVOICE

14964

DATE

9-23-22


PATIENT
Gastrointestinal

Ella Nunes

The stomach presented intact wall layering with a normal wall layer ratio. The lumen of the stomach was empty with no signs of ileus, obstruction, or foreign material. The ventral gastric body wall width measured 0.36 cm.

SPECIES

Canine

The small intestine presented intact wall layering with 1:3 muscularis/mucosa ratio. The lumen of the small intestine was empty with no signs of ileus, obstruction, or foreign material. The duodenum wall measured 0.45 cm width.

BREED

Yorkie

Normal visible colon wall layers were present with apparent formed feces in lumen.

Pancreas
SEX

FS

The parenchyma of the pancreas base and right pancreatic limb was mildly hyperechoic to adjacent omental fat with diffuse parenchyma remodeling. The capsule of the pancreas was mildly asymmetrical in contour without evidence of peripancreatic inflammation. These changes may suggest chronic inflammation, fibrosis, or saponification if previous history of pancreatitis. No overt signs of pancreatic neoplasia.

AGE

12 years

Free Abdomen

No overt lymphadenopathy or peritoneal effusion was present.

WEIGHT

3.6 kg

ULTRASONOGRAPHIC FINDINGS

- Hepatopathy - nonspecific, overtly benign, reactive, mild inflammatory hepatopathy possible, no evidence of neoplastic criteria
- Mild gallbladder debris (non-mucocele)
- Mild chronic pancreatitis pattern, potential for mild pancreatic fibrosis
- Bilateral chronic renal changes exhibiting minor medullary mineral and left kidney cortical cysts
- Overtly normal gastrointestinal tract - potential low grade to resolving gastroenteritis

INTERPRETED BY

 R. McKenzie Daniel,
 DVM, DABVP

**IMAGING
 PERFORMED BY**

Crystal Hill

HOSPITAL NAME

Hawkins AH

REFERRING VET

Dr. Hawkins

INTERPRETATION OF THE FINDINGS & FURTHER RECOMMENDATIONS

Assuming normal clotting status, screening hepatic FNA cytology may be considered, primarily to assess for or possibly identify inflammatory cell type if present. Hepatosupportive medications such as Denamarin +/- Ursodiol may prove beneficial.

As-needed GI supportive care and/or empirical therapy for potential chronic pancreatitis is recommended. A spec cPL could be considered.

INVOICE

14964

DATE

9-23-22



PATIENT

Ella Nunes

SPECIES

Canine

BREED

Yorkie

SEX

FS

AGE

12 years

WEIGHT

3.6 kg

INTERPRETED BY

R. McKenzie Daniel,
DVM, DABVP

**IMAGING
PERFORMED BY**

Crystal Hill

HOSPITAL NAME

Hawkins AH

REFERRING VET

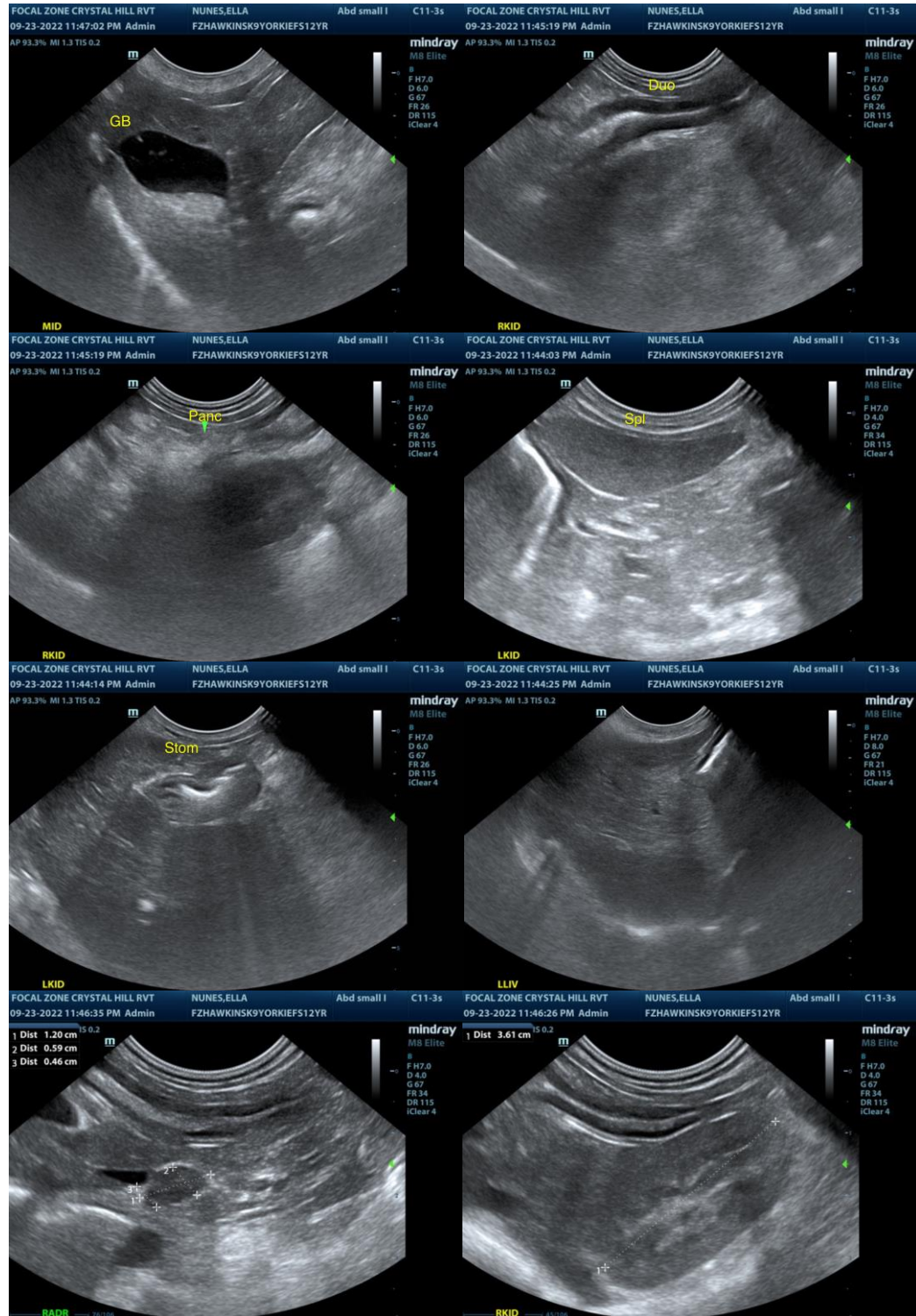
Dr. Hawkins

INVOICE

14964

DATE

9-23-22





PATIENT

Ella Nunes

SPECIES

Canine

BREED

Yorkie

SEX

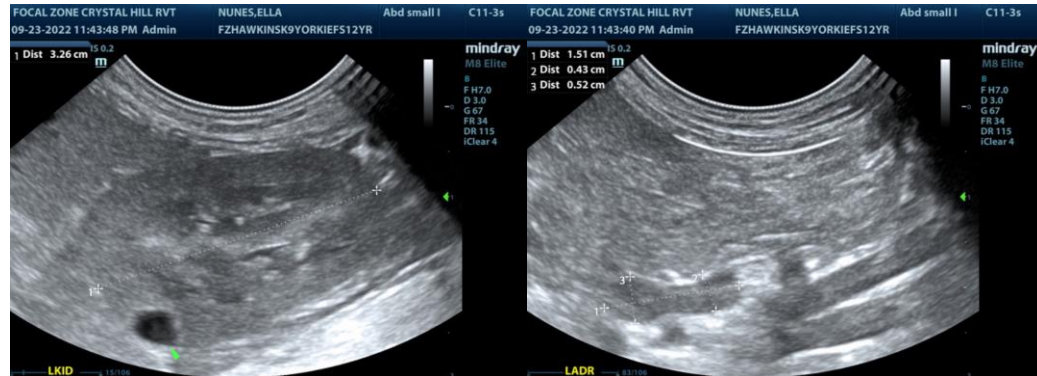
FS

AGE

12 years

WEIGHT

3.6 kg



The information and recommendations provided are based on the images presented by the referring veterinarian/sonographer. No evaluation can be communicated regarding pathology that was not visible in the image/video clips provided.

Thank you for this referral. If the clinical or image interpretation does not parallel your findings or if I can be of any further assistance please contact me.

R. McKenzie Daniel, DVM, DABVP (Canine / Feline Practice)
info@SonoPath.com

INTERPRETED BY

R. McKenzie Daniel,
DVM, DABVP

**IMAGING
PERFORMED BY**

Crystal Hill

HOSPITAL NAME

Hawkins AH

REFERRING VET

Dr. Hawkins

INVOICE

14964

DATE

9-23-22