



PATIENT	PRESENTING CLINICAL SIGNS
Selva Roitman	Decreased appetite, regurgitation, CPL abnormal. Hx of hypothyroidism. Current meds: Soloxine, Cerenia, Ondansetron, Famotidine, Buprenex
SPECIES	Abnormal PE/Chem/CBC/UA Results: Cpl abnormal
Canine	ULTRASONOGRAPHIC EXAMINATION OF THE ABDOMEN
BREED	Urinary System
Rottweiler	The urinary bladder, trigone, cystourethral junction, and visible pelvic urethra to a depth of 4 cm exhibited normal thickness and tone. Anechoic urine was present in the lumen with no uroliths or sediment. The ureteral papillae were normal. The ureters were not visible which is normal. No evidence of inflammatory or neoplastic changes were noted.
SEX	
FS	Normal size and margination were present in the kidneys. A normal 1:3 cortex / medulla ratio and normal corticomedullary definition were maintained. The echogenicity of the cortex was similar to or slightly less than normal liver parenchyma while the medulla echogenicity was hypoechoic to the cortex with no evidence of pelvic dilation. The left kidney measured 7.3 cm in length. The right kidney measured 6.7 cm in length.
AGE	
7yr	The area of the aortic trifurcation was free of pathology.
WEIGHT	Adrenal Glands
101lb	The left adrenal gland was uniform in size and contour with a uniformly hypoechoic parenchyma. The left adrenal gland measured 0.64 cm width at the caudal pole and 2.3 cm length. The right adrenal gland was uniform in size and contour with a uniformly hypoechoic parenchyma. The right adrenal gland measured 0.75 cm width at the caudal pole and 2.7 cm length.
INTERPRETED BY	Spleen
R. McKenzie Daniel, DVM, DABVP (Canine and Feline)	The spleen exhibited a finely textured and homogenous parenchyma which was hyperechoic to the liver and renal cortical parenchyma. The capsule was smooth and regular without apparent expansion. The splenic vasculature at the hilus was normal in volume with no evidence of congestion or thrombosis. Acute to chronic inflammatory, neoplastic, or benign parenchyma changes were not noted.
IMAGING PERFORMED BY	Liver
Shari Reffi CVT	The liver was subjectively normal in size, structure, and contour. The liver parenchyma was uniform and hypoechoic to the spleen with a mild coarse echotexture. The hepatic and portal vasculature were normal in appearance without signs of congestion. The gallbladder was non-distended in size with thin walls and primarily anechoic luminal content. The cystic and common bile ducts were normal.
HOSPITAL NAME	Gastrointestinal
Newton Vet	The stomach presented intact wall layering with a normal wall layer ratio. The stomach was moderately distended with retained anechoic fluid with no signs of ileus, obstruction or foreign material. The gastric body wall measured 0.5 cm in width. Prominent wall layering in the area of the antrum and pylorus owing to prominent mucosa. The pyloric wall measured 0.92 cm in width.
REFERRING VET	
Dr. Verhalen	The small intestine presented intact wall layering with 1:3 muscularis/mucosa ratio. The lumen of the small intestine was empty with no signs of ileus, obstruction or foreign material. The duodenum measured 0.52 cm in width. The jejunum measured 0.34 cm in width.
INVOICE	
11683ag	
DATE	
09/20/2022	



PATIENT

Normal visible colon wall layers were present with apparent formed feces in lumen.

Selva Roitman

Pancreas

SPECIES

The area of the pancreas base and right pancreatic limb exhibited mildly non-uniform to hyperechoic regional parenchyma compared to adjacent omental fat. A normal curvilinear capsule contour of the pancreas was present. The visible pancreatic duct was normal.

Canine

Free Abdomen

BREED

No overt lymphadenopathy or peritoneal effusion was present.

Rottweiler

ULTRASONOGRAPHIC FINDINGS

Primary

SEX

- Hypomotile stomach with pyloric gastritis pattern
- Possible mild hyperechoic pancreas vs regional peripancreatic/peripyloric hyperechoic reactive mesentery
- Sonographically unremarkable small bowel-no evidence of mechanical or metabolic ileus

FS

AGE

7yr

INTERPRETATION OF THE FINDINGS & FURTHER RECOMMENDATIONS

Considerations for the hypomotile stomach may include metabolic vs mechanical gastric stasis. Overt evidence of mechanical pyloric outflow obstruction was not definitively visualized. The appearance of the pylorus and antrum are suggestive of inflammatory criteria without evidence of neoplastic disease. Gastric hypomotility secondary to inflammation, low-grade resolving or chronic pancreatitis is possible. Continued medical therapy for gastritis, gastric hypomotility and resolving low-grade to chronic pancreatitis over the next 24-36 hours would be reasonable. If persistent evidence of retained gastric fluid, regurgitation or vomiting, gastric endoscopy for further assessment of the gastric lumen and pyloric outflow would likely be ideal. Contrast study to assess pyloric outflow if clinically indicated may be considered as a more conservative approach. A resting cortisol level to rule out occult Addison's disease may be considered although thought unlikely.

WEIGHT

101lb

INTERPRETED BY

R. McKenzie Daniel,
DVM, DABVP
(Canine and Feline)

IMAGING PERFORMED BY

Shari Reffi CVT

HOSPITAL NAME

Newton Vet

REFERRING VET

Dr. Verhalen

INVOICE

11683ag

DATE

09/20/2022



PATIENT

Selva Roitman

SPECIES

Canine

BREED

Rottweiler

SEX

FS

AGE

7yr

WEIGHT

101lb

INTERPRETED BY

R. McKenzie Daniel,
DVM, DABVP
(Canine and Feline)

IMAGING PERFORMED BY

Shari Reffi CVT

HOSPITAL NAME

Newton Vet

REFERRING VET

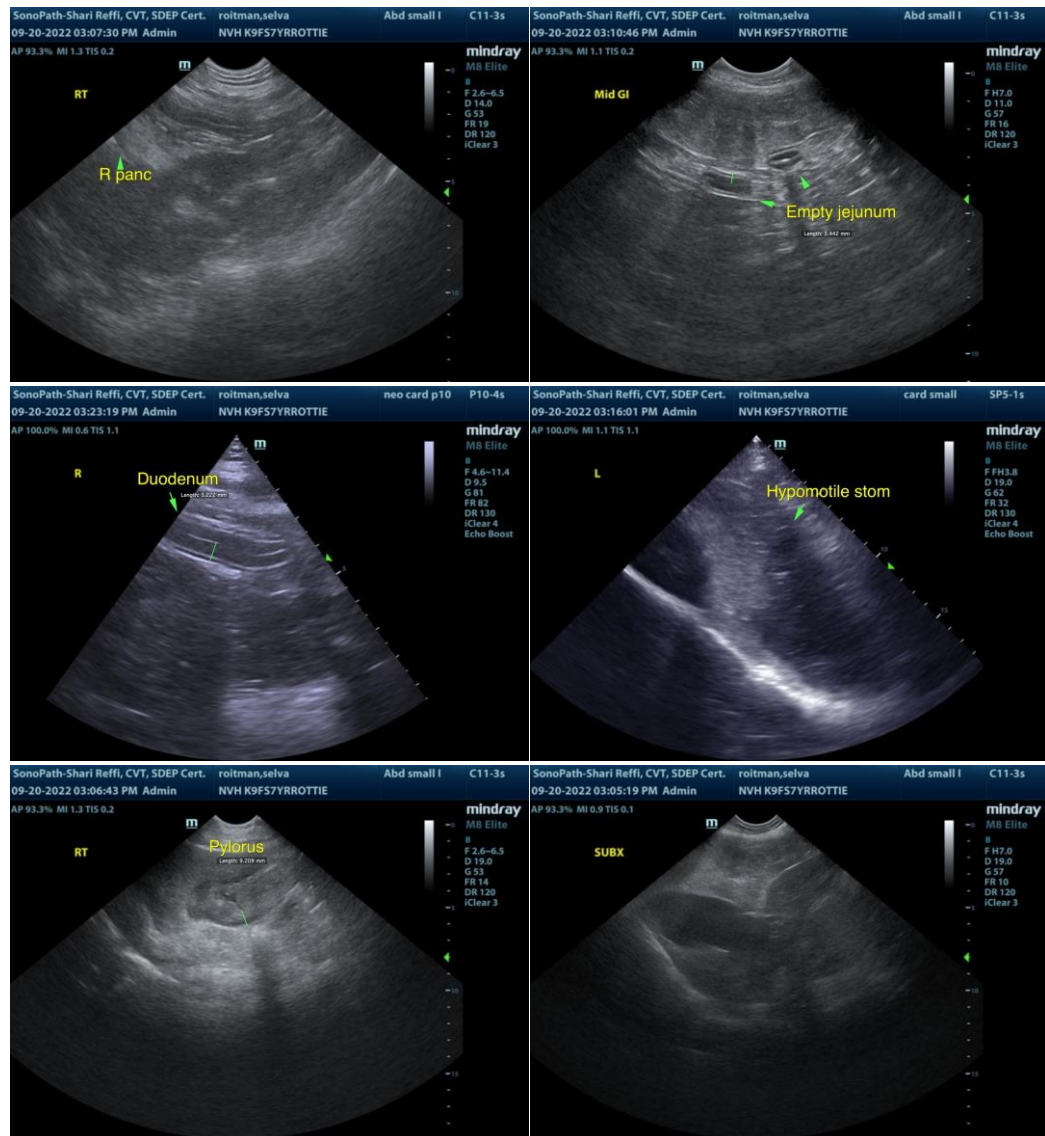
Dr. Verhalen

INVOICE

11683ag

DATE

09/20/2022





PATIENT

Selva Roitman

SPECIES

Canine

BREED

Rottweiler

SEX

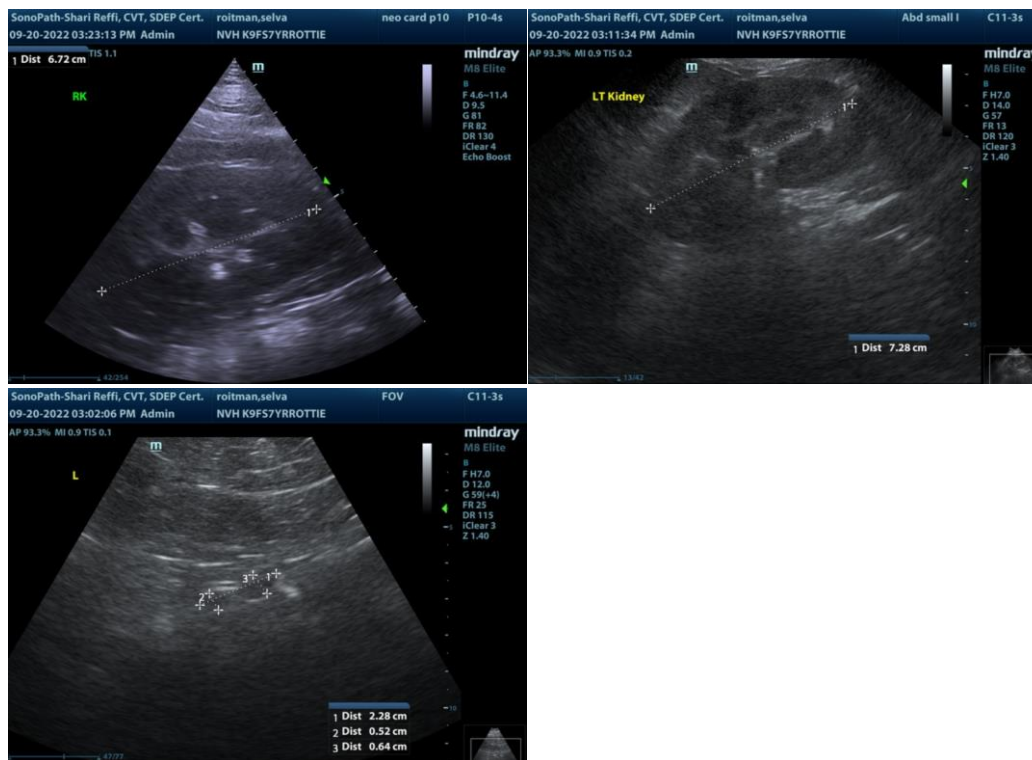
FS

AGE

7yr

WEIGHT

101lb



INTERPRETED BY

R. McKenzie Daniel,
DVM, DABVP
(Canine and Feline)

IMAGING PERFORMED BY

Shari Reffi CVT

HOSPITAL NAME

Newton Vet

REFERRING VET

Dr. Verhalen

INVOICE

11683ag

DATE

09/20/2022

The information and recommendations provided are based on the images presented by the referring veterinarian/sonographer. No evaluation can be communicated regarding pathology that was not visible in the image/video clips provided.

Thank you for this referral. If the clinical or image interpretation does not parallel your findings or if I can be of any further assistance please contact me.

R. McKenzie Daniel, DVM, DABVP (Canine / Feline Practice)

info@SonoPath.com