



PATIENT	PRESENTING CLINICAL SIGNS
Mr. Wilson Roberts	Increased ALPK, patient is not on any medications Abnormal PE/Chem/CBC/UA Results: ALKP=1104, May 2022 was 604
SPECIES	
Canine	ULTRASONOGRAPHIC EXAMINATION OF THE ABDOMEN
BREED	Urinary System
Scottish Terrier	The urinary bladder, trigone, cystourethral junction, and visible pelvic urethra to a depth of 2.0 cm exhibited normal thickness and tone. Anechoic urine was present in the lumen with no uroliths or sediment. The ureteral papillae were normal. The ureters were not visible which is normal. No evidence of inflammatory or neoplastic changes was noted.
SEX	No evidence of pathology associated with the residual prostate was noted.
MN	The area of the aortic trifurcation was free of pathology.
AGE	Normal size and margination were present in the kidneys. A normal 1:3 cortex / medulla ratio and normal corticomedullary definition were maintained. The echogenicity of the cortex was similar to or slightly less than normal liver parenchyma while the medulla echogenicity was hypoechoic to the cortex with no evidence of pelvic dilation. The left kidney measured 5.4 cm in length. The right kidney measured 5.7 cm in length.
8 yrs	
WEIGHT	
30.4	
INTERPRETED BY	Adrenal Glands
R. McKenzie Daniel, DVM, DABVP (Canine and Feline)	The left adrenal gland was uniform in size and contour with a uniformly hypoechoic parenchyma. The left adrenal gland measured 0.49 cm width at the caudal pole. The right adrenal gland was uniform in size and contour with a uniformly hypoechoic parenchyma. The right adrenal gland measured 0.68 cm width at the caudal pole and 0.7 cm width at the cranial pole. No evidence of adrenomegaly or tumors.
IMAGING PERFORMED BY	Spleen
Nicole Gotfredson	The spleen exhibited a finely textured and homogenous parenchyma which was hyperechoic to the liver and renal cortical parenchyma. The capsule was smooth and regular without apparent expansion. The splenic vasculature at the hilus was normal in volume with no evidence of congestion or thrombosis. Acute to chronic inflammatory, neoplastic, or benign parenchyma changes were not noted.
HOSPITAL NAME	Liver/ Gallbladder
Buffalo Veterinary Clinic	The liver exhibited subjective mild generalized enlargement. The parenchyma of the liver was subjectively normal in echogenicity compared to the spleen and renal cortices. The liver parenchyma was uniform with a mildly coarse echotexture. A solitary, small, thinly-walled, nondisruptive, intraparenchymal cyst was noted in the ventral liver measuring 0.87 cm in diameter. The capsule of the liver was symmetrically rounded to mildly swollen in margination. The hepatic and portal vasculature were normal in appearance without signs of congestion. The gallbladder was non-distended in size containing primarily anechoic content with mildly echogenic, luminal gallbladder debris. No evidence of gallbladder or peripheral gallbladder inflammatory criteria was noted. The cystic and common bile ducts were normal.
REFERRING VET	
Teresa Bessler	
INVOICE	
14919	
DATE	
9-20-22	



PATIENT

Gastrointestinal

Mr. Wilson Roberts

The stomach presented intact wall layering with a normal wall layer ratio. The lumen of the stomach was empty with no signs of ileus, obstruction, or foreign material.

SPECIES

Canine

The small intestine presented intact wall layering with 1:3 muscularis/mucosa ratio. The lumen of the small intestine was empty with no signs of ileus, obstruction, or foreign material.

BREED

Scottish Terrier

Normal visible colon wall layers were present with apparent formed feces in lumen.

SEX

MN

Pancreas

The parenchyma of the left limb, body, and right limb of the pancreas presented isoechoic to the adjacent omental fat. A normal curvilinear capsule contour of the pancreas was present. The visible pancreatic duct was normal. No signs of active inflammation or neoplastic disease were evident.

AGE

8 yrs

Free Abdomen

No overt lymphadenopathy or peritoneal effusion was present.

WEIGHT

30.4

ULTRASONOGRAPHIC FINDINGS

- Vacuolar hepatopathy pattern
- Mild gallbladder debris (non-mucocele)

INTERPRETED BY

R. McKenzie Daniel,
DVM, DABVP
(Canine and Feline)

INTERPRETATION OF THE FINDINGS & FURTHER RECOMMENDATIONS

Sonographically, the appearance of the liver was consistent with vacuolar hepatopathy or breed-associated vacuolar hepatopathy, as Scottish Terriers are prone to increased ALP elevations. Inflammatory hepatopathy, i.e., cholangiohepatitis, is considered a less likely differential diagnosis without evidence of current neoplastic criteria. However, this condition in Scottish Terriers may potentially progress to hepatic masses or neoplastic criteria.

IMAGING PERFORMED BY

Nicole Gotfredson

Serial sonographic monitoring of the liver i.e., recheck every 6-12 months, would be ideal, specifically if progressive ALP elevations are noted. Hepatosupportive medications including Denamarin and Ursodiol may prove beneficial. Initial screening FNA hepatic cytology could be considered assuming normal clotting status.

HOSPITAL NAME

Buffalo Veterinary
Clinic

REFERRING VET

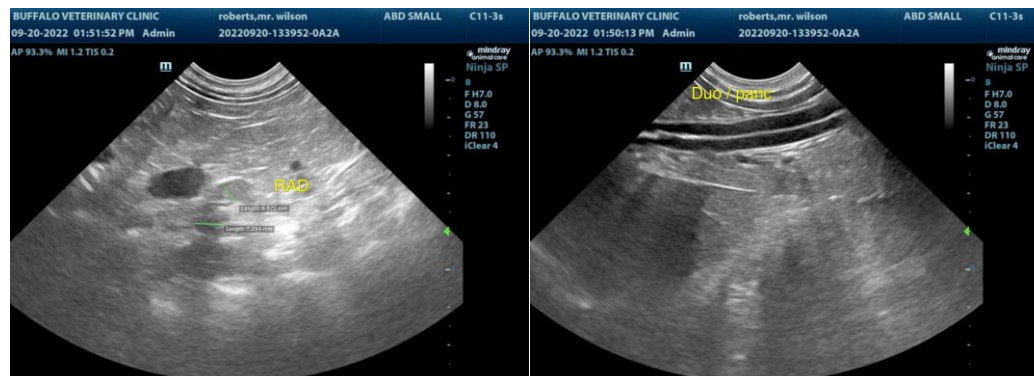
Teresa Bessler

INVOICE

14919

DATE

9-20-22





PATIENT

Mr. Wilson Roberts

SPECIES

Canine

BREED

Scottish Terrier

SEX

MN

AGE

8 yrs

WEIGHT

30.4

INTERPRETED BY

R. McKenzie Daniel,
DVM, DABVP
(Canine and Feline)

IMAGING PERFORMED BY

Nicole Gotfredson

HOSPITAL NAME

Buffalo Veterinary
Clinic

REFERRING VET

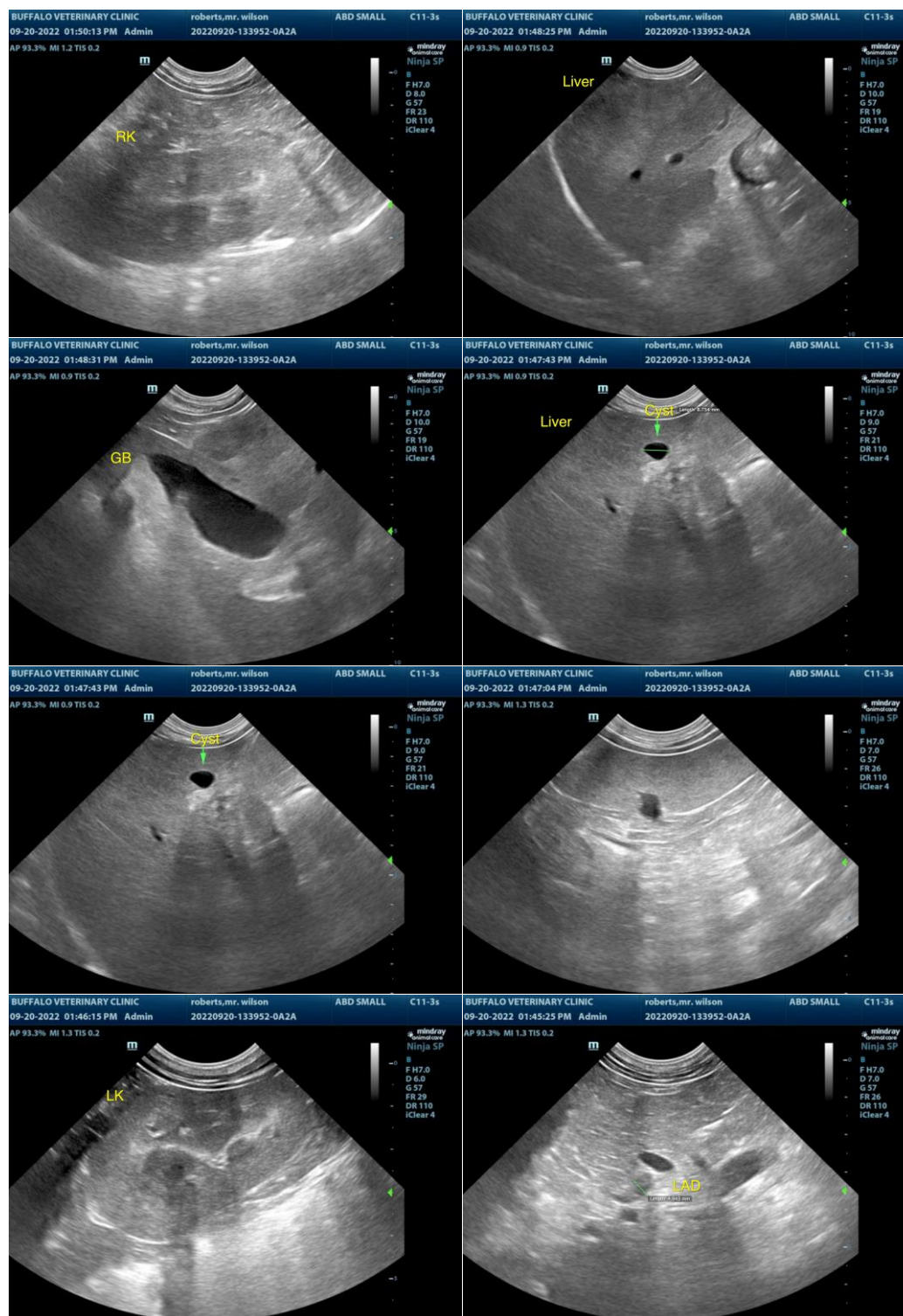
Teresa Bessler

INVOICE

14919

DATE

9-20-22



The information and recommendations provided are based on the images presented by the referring veterinarian/sonographer. No evaluation can be communicated regarding pathology that was not visible in the image/video clips provided.



PATIENT

Mr. Wilson Roberts

Thank you for this referral. If the clinical or image interpretation does not parallel your findings or if I can be of any further assistance please contact me.

SPECIES

Canine

R. McKenzie Daniel, DVM, DABVP (Canine / Feline Practice)
info@SonoPath.com

BREED

Scottish Terrier

SEX

MN

AGE

8 yrs

WEIGHT

30.4

INTERPRETED BY

R. McKenzie Daniel,
DVM, DABVP
(Canine and Feline)

**IMAGING
PERFORMED BY**

Nicole Gotfredson

HOSPITAL NAME

Buffalo Veterinary
Clinic

REFERRING VET

Teresa Bessler

INVOICE

14919

DATE

9-20-22