



PATIENT PRESENTING CLINICAL SIGNS

Truffles Ambrosino Liver enzymes elevated; anemia

SPECIES

Abnormal PE/Chem/CBC/UA Results: ALP 369; GGTP 44; creatinine 0.4; BUN/creatinine ratio 45; RBC 5.5; hemoglobin 8.8; HCT 29; NRBC 6; platelet count 524

Canine

ULTRASONOGRAPHIC EXAMINATION OF THE ABDOMEN

BREED

Urinary System

Yorkshire Terrier

The urinary bladder, trigone, cystourethral junction, and visible pelvic urethra to a depth of 2 cm exhibited normal thickness and tone. Anechoic urine was present in the lumen with no uroliths or sediment. The ureteral papillae were normal. The ureters were not visible which is normal. No evidence of inflammatory or neoplastic changes were noted.

SEX

FI

Normal size and margination was present in the kidneys. A normal 1:3 cortex / medulla ratio was maintained. The medulla and cortices were uniform in texture with some increased echogenicity and moderate loss of corticomedullary symmetry and definition expected for the age of the patient. No evidence of pelvic dilation was present. Pinpoint non-obstructive medullary mineral was present in the right kidney. The left kidney measured 3.6 cm in length. The right kidney measured 3.9 cm in length.

AGE

11yr

The area of the aortic trifurcation was free of pathology.

WEIGHT

5.8lb

No obvious pathology associated with the uterus or bilateral ovaries.

Adrenal Glands

INTERPRETED BY

R. McKenzie Daniel, DVM, DABVP (Canine and Feline)

The left adrenal gland was uniform in size and contour with a uniformly hypoechoic parenchyma. The left adrenal gland measured 0.49 cm width at the caudal pole and 0.36 cm width at the cranial pole. The right adrenal gland was uniform in size and contour with a uniformly hypoechoic parenchyma. The right adrenal gland measured 0.36 cm width at the caudal pole and 0.49 cm width at the cranial pole.

Spleen

IMAGING PERFORMED BY

Pamela Harrigan, RDCS

The spleen exhibited a finely textured and homogenous parenchyma which was hyperechoic to the liver and renal cortical parenchyma. The capsule was smooth and regular without apparent expansion. The splenic vasculature at the hilus was normal in volume with no evidence of congestion or thrombosis. Acute to chronic inflammatory, neoplastic, or benign parenchyma changes were not noted.

HOSPITAL NAME

East Boston Animal Hospital

Liver

REFERRING VET

Dr. Chopra

The liver exhibited moderate to marked enlargement owing to a large expansive non-homogeneous to mixed echogenic mass in the parenchyma including extension into the area of the portal vein/porta hepatis. The mass measured ~ 10 cm in diameter. Concurrent intraparenchymal cystic nodules were present in the left lateral liver an example measuring 1.9 cm in diameter. The hepatic and portal vasculature were normal in appearance without signs of congestion.

INVOICE

11678ag

The gallbladder was non-distended in size with thin walls and primarily anechoic luminal content with moderate non-dependent mobile hyperechoic luminal debris. The cystic and common bile ducts were normal.

Gastrointestinal

DATE

09/19/2022

The stomach presented intact wall layering with a normal wall layer ratio. The lumen of the stomach was empty with no signs of ileus, obstruction or foreign material. The stomach was mildly displaced owing to hepatomegaly. The gastric body wall measured 0.32 cm in width.



PATIENT

Truffles Ambrosino

The small intestine presented intact wall layering with 1:3 muscularis/mucosa ratio. The lumen of the small intestine was empty with no signs of ileus, obstruction or foreign material. The duodenum wall measured 0.31 cm in width. The jejunum wall measured 0.32 cm in width.

SPECIES

Canine

Normal visible colon wall layers were present with apparent formed feces in lumen.

Pancreas

The pancreas was normal in size and contour with isoechoic to heterogeneous parenchyma compared to adjacent omentum. No signs of active inflammation or neoplasia.

BREED

Yorkshire Terrier

Free Abdomen

Regional perihepatic hyperechoic mesentery and small pockets of scant perihepatic free fluid were present. Potential for concurrent lymphadenopathy possible although differentiation from hepatic nodules was unclear.

SEX

FI

AGE

11yr

WEIGHT

5.8lb

ULTRASONOGRAPHIC FINDINGS

- Large non-homogeneous liver mass with concurrent intraparenchymal nodules
- Gallbladder debris (non-mucocele)
- Mild chronic renal changes
- Heterogeneous pancreas-likely incidental

INTERPRETATION OF THE FINDINGS & FURTHER RECOMMENDATIONS

INTERPRETED BY

R. McKenzie Daniel, DVM,
 DABVP (Canine and Feline)

Although sampling is required for further assessment the liver mass and intraparenchymal nodules are consistent with neoplastic criteria. Potential for non-neoplastic etiologies is considered unlikely. Further assessment may include a screening hepatic FNA cytology with potential for oncology consult. Given the size and position of the liver mass, surgical resection is precluded.

IMAGING PERFORMED BY

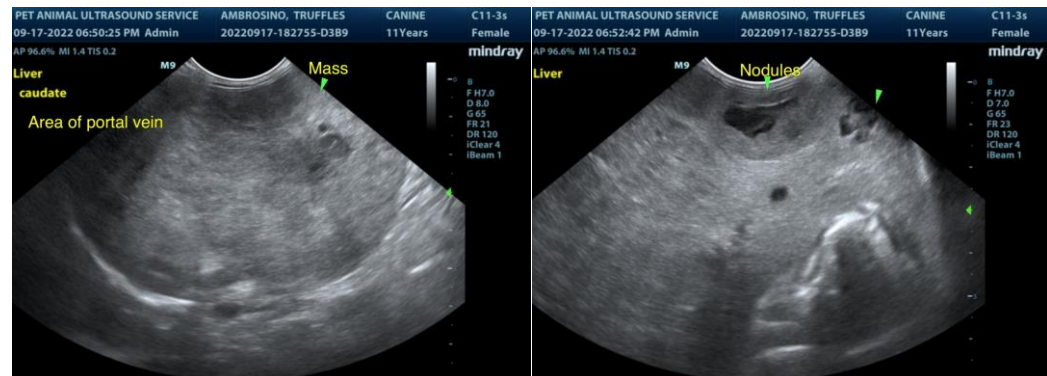
Pamela Harrigan, RDCS

HOSPITAL NAME

East Boston Animal
 Hospital

REFERRING VET

Dr. Chopra



INVOICE

11678ag

DATE

09/19/2022



PATIENT
 Truffles Ambrosino

SPECIES
 Canine

BREED
 Yorkshire Terrier

SEX
 FI

AGE
 11yr

WEIGHT
 5.8lb

INTERPRETED BY
 R. McKenzie Daniel, DVM,
 DABVP (Canine and Feline)

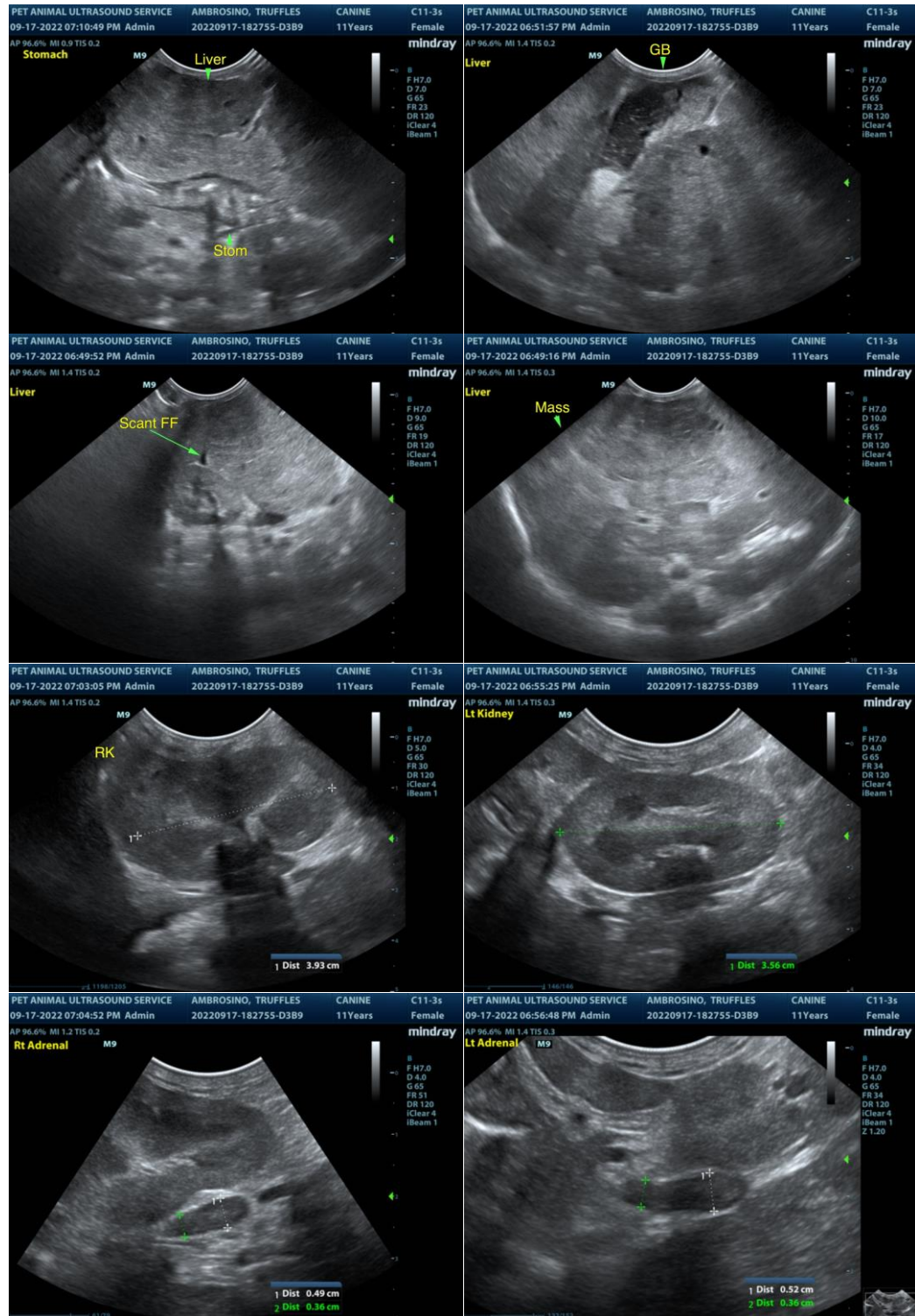
IMAGING PERFORMED BY
 Pamela Harrigan, RDCS

HOSPITAL NAME
 East Boston Animal
 Hospital

REFERRING VET
 Dr. Chopra

INVOICE
 11678ag

DATE
 09/19/2022





PATIENT

Truffles Ambrosino

Thank you for this referral. If the clinical or image interpretation does not parallel your findings or if I can be of any further assistance please contact me.

SPECIES

Canine

R. McKenzie Daniel, DVM, DABVP (Canine / Feline Practice)
info@SonoPath.com

BREED

Yorkshire Terrier

SEX

FI

AGE

11yr

WEIGHT

5.8lb

INTERPRETED BY

R. McKenzie Daniel, DVM,
DABVP (Canine and Feline)

**IMAGING
PERFORMED BY**

Pamela Harrigan, RDMS

HOSPITAL NAME

East Boston Animal
Hospital

REFERRING VET

Dr. Chopra

INVOICE

11678ag

DATE

09/19/2022