

PATIENT

Luna DiCosmo

PRESENTING CLINICAL SIGNS

chronic intermittent diarrhea increased PL

SPECIES

Canine

ULTRASONOGRAPHIC EXAMINATION OF THE ABDOMEN

Urinary System

The urinary bladder, trigone, cystourethral junction, and visible pelvic urethra exhibited normal thickness and tone. Anechoic urine was present in the lumen with no uroliths or sediment. The ureteral papillae were normal. The ureters were not visible which is normal. No evidence of inflammatory or neoplastic changes were noted.

BREED

Poodle Mix

Normal size and margination were present in the kidneys. A normal 1:3 cortex / medulla ratio and normal corticomedullary definition were maintained. The echogenicity of the cortex was similar to or slightly less than normal liver parenchyma while the medulla echogenicity was hypoechoic to the cortex with no evidence of pelvic dilation. The left kidney measured 5.2 cm in length. The right kidney measured 5.0 cm in length.

SEX

F

AGE

6mo

The area of the aortic trifurcation was free of pathology.

Adrenal Glands

The left adrenal gland was uniform in size and contour with a uniformly hypoechoic parenchyma. The left adrenal gland measured 0.44 cm width at the caudal pole and 2.4 cm length. The right adrenal gland was uniform in size and contour with a uniformly hypoechoic parenchyma. The right adrenal gland measured 0.57 cm width at the caudal pole and 2.3 cm length.

WEIGHT

33.5

Spleen

The spleen exhibited a finely textured and homogenous parenchyma which was hyperechoic to the liver and renal cortical parenchyma. The capsule was smooth and regular without apparent expansion. The splenic vasculature at the hilus was normal in volume with no evidence of congestion or thrombosis. Acute to chronic inflammatory, neoplastic, or benign parenchyma changes were not noted.

INTERPRETED BY

R. McKenzie Daniel,
DVM, DABVP
(Canine and Feline)

IMAGING PERFORMED BY

Jenn

Liver

The liver was subjectively normal in size, structure, and contour. The liver parenchyma was uniform and hypoechoic to the spleen with a mild coarse echotexture. The hepatic and portal vasculature were normal in appearance without signs of congestion. The gallbladder was non-distended in size with thin walls and primarily anechoic luminal content. The cystic and common bile ducts were normal.

HOSPITAL NAME

Rockaway Animal
Hospital

Gastrointestinal

REFERRING VET

Dr. Maniar

The stomach presented intact wall layering with a normal wall layer ratio. The lumen of the stomach contained mild non-shadowing ingesta/chyme with no signs of ileus, obstruction or foreign material.

The small intestine presented intact wall layering with 1:3 muscularis/mucosa ratio. The lumen of the small intestine was empty with no signs of ileus, obstruction or foreign material.

INVOICE

11656ag

Normal visible colon wall layers were present with apparent formed feces in lumen.

Pancreas

DATE

09/19/2022



PATIENT

Luna DiCosmo

The parenchyma of the left limb, body and right limb of the pancreas presented isoechoic to the adjacent omental fat. A normal curvilinear capsule contour of the pancreas was present. The visible pancreatic duct was normal. No signs of active inflammation or neoplastic disease was evident.

SPECIES

Canine

Free Abdomen

No overt lymphadenopathy or peritoneal effusion was present.

BREED

Poodle Mix

ULTRASONOGRAPHIC FINDINGS

Primary

- Overtly normal GI tract/colon with mild gastric ingesta
- Sonographically unremarkable pancreas

SEX

F

INTERPRETATION OF THE FINDINGS & FURTHER RECOMMENDATIONS

No overt evidence of structural gastroenterocolic or active pancreatitis was present in this study. Dietary intolerance / food hypersensitivity, occult parasitism, inflammatory bowel disease without evidence of mural changes or other with potential for low grade pancreatitis which may present sonographically normal. Assessment of serum cobalamin and folate levels is suggested.

AGE

6mo

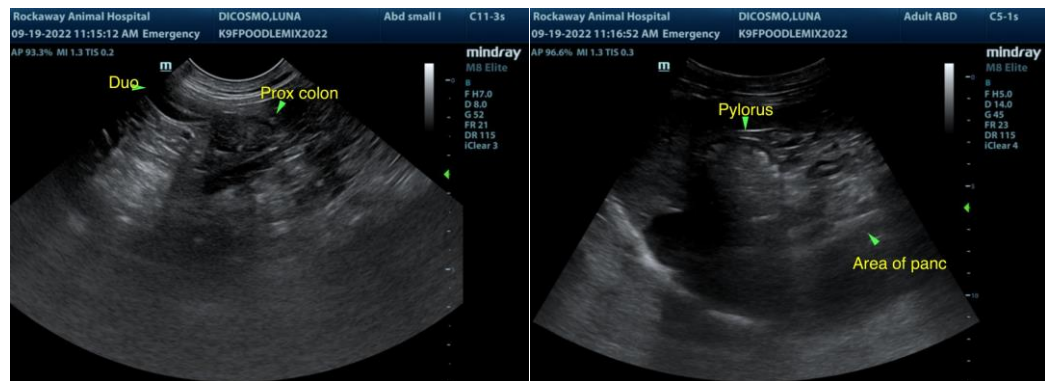
Empirically, a limited antigen or hydrolyzed diet trial with potential long term dietary therapy, prophylactic deworming (Panacur 50 mg/kg SID x 5 consecutive days with repeat protocol in 3 weeks even if fecal testing is negative), high colony count probiotic (Proviale or Visbiome), antibiotic trial and as needed gastrointestinal support with assessment of clinical response may prove beneficial.

WEIGHT

33.5

INTERPRETED BY

R. McKenzie Daniel,
DVM, DABVP
(Canine and Feline)

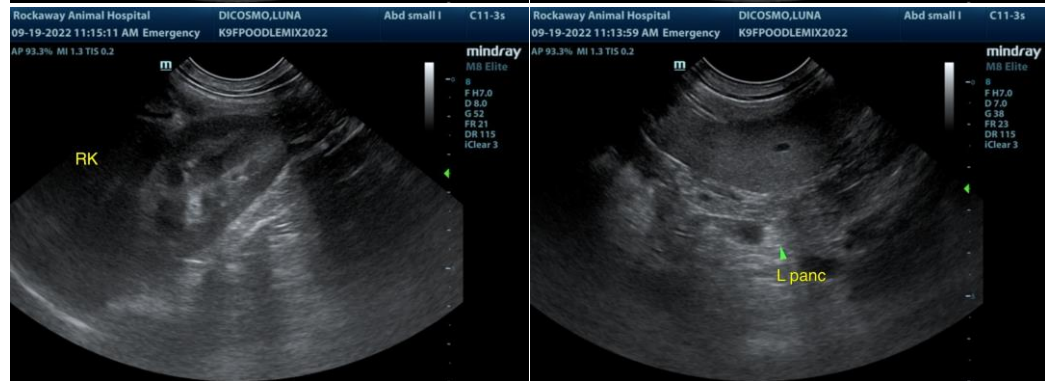


IMAGING PERFORMED BY

Jenn

HOSPITAL NAME

Rockaway Animal Hospital



REFERRING VET

Dr. Maniar

INVOICE

11656ag

DATE

09/19/2022



PATIENT

Luna DiCosmo

SPECIES

Canine

BREED

Poodle Mix

SEX

F

AGE

6mo

WEIGHT

33.5

INTERPRETED BY

R. McKenzie Daniel,
DVM, DABVP
(Canine and Feline)

IMAGING PERFORMED BY

Jenn

HOSPITAL NAME

Rockaway Animal
Hospital

REFERRING VET

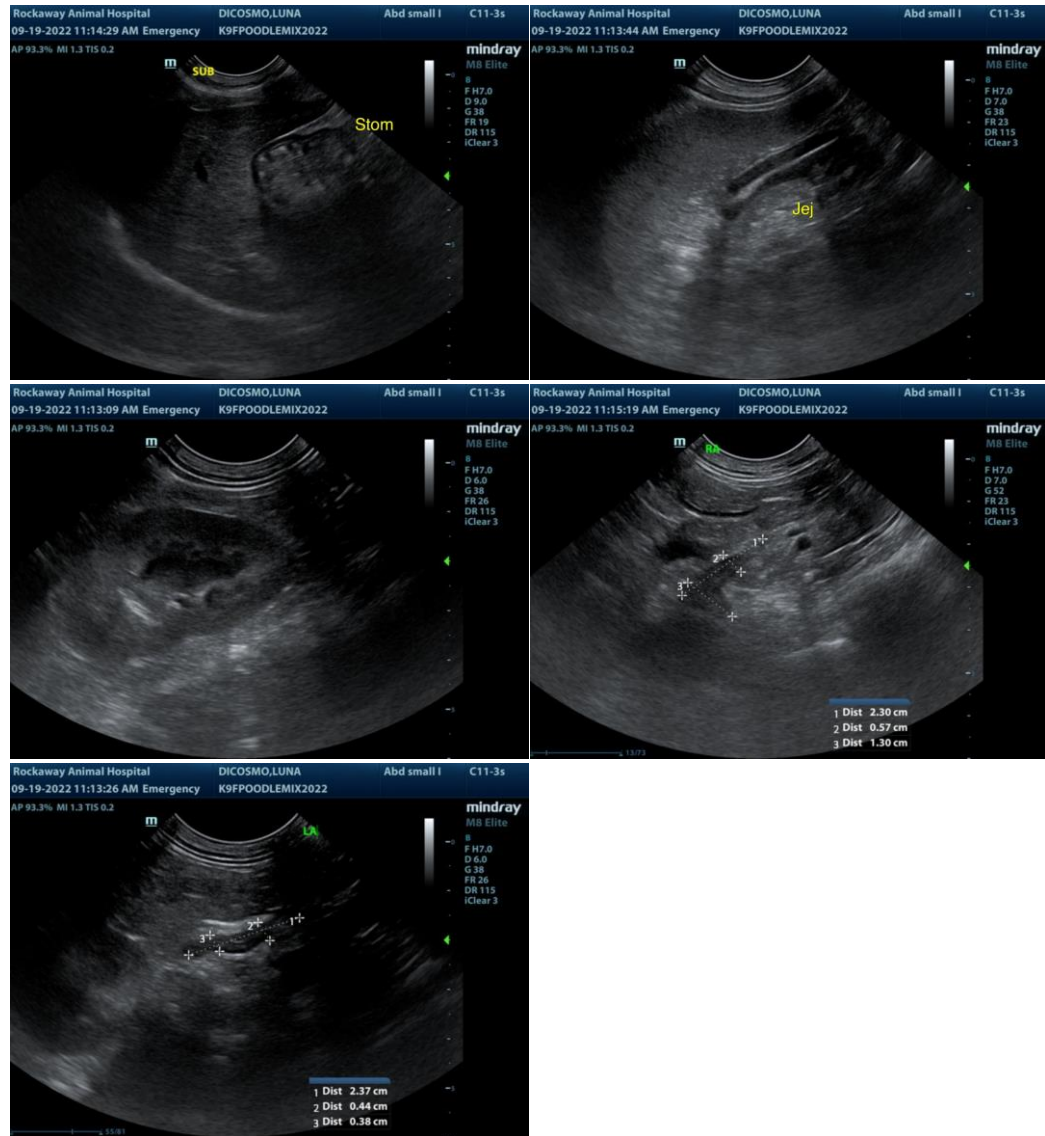
Dr. Maniar

INVOICE

11656ag

DATE

09/19/2022



The information and recommendations provided are based on the images presented by the referring veterinarian/sonographer. No evaluation can be communicated regarding pathology that was not visible in the image/video clips provided.

Thank you for this referral. If the clinical or image interpretation does not parallel your findings or if I can be of any further assistance please contact me.

R. McKenzie Daniel, DVM, DABVP (Canine / Feline Practice)

info@SonoPath.com