



**PATIENT PRESENTING CLINICAL SIGNS**

**Bernie Smith** Losing weight, sneezing, shivering. Temp taken at home low. Normal appetite. Lethargic, less active play with other cat. Has been going on for about 2 weeks. Abdomen seems distended on palpation. Was diagnosed with Herpes. No meds. Liver? Neoplasia? Other

**SPECIES**

Feline

Abnormal PE/Chem/CBC/UA Results: N/A

**ULTRASONOGRAPHIC EXAMINATION OF THE ABDOMEN**

**BREED**

**Urinary System**

DSH

The urinary bladder, trigone, cystourethral junction, and visible pelvic urethra to a depth of 2 cm exhibited normal thickness and tone. Anechoic urine was present in the lumen with moderate non-dependent particulate sediment. The ureteral papillae were normal. The ureters were not visible which is normal. No evidence of inflammatory or neoplastic changes were noted.

**SEX**

MN

Normal size and margination were present in the kidneys. A normal 1:3 cortex / medulla ratio with uniform increased cortex echogenicity and mildly enhanced corticomedullary border distinction. No evidence of pelvic dilation. The left kidney measured 4.4 cm in length. The right kidney measured 4.5 cm in length.

**AGE**

8yr

The area of the aortic trifurcation was free of pathology.

**WEIGHT**

5.2kg

**Adrenal Glands**

The left adrenal gland was uniform in size and contour with a uniformly hypoechoic parenchyma. The left adrenal gland measured 0.32 cm width. The right adrenal gland was uniform in size and contour with a uniformly hypoechoic parenchyma. The right adrenal gland measured 0.45 cm width.

**INTERPRETED BY**

R. McKenzie Daniel,  
DVM, DABVP  
(Canine and Feline)

**Spleen**

The spleen exhibited a finely textured and homogenous parenchyma which was hyperechoic to the liver and renal cortical parenchyma. The capsule was smooth and regular without apparent expansion. The splenic vasculature at the hilus was normal in volume with no evidence of congestion or thrombosis. Acute to chronic inflammatory, neoplastic, or benign parenchyma changes were not noted. The spleen measured 0.9 cm in width at the level of the hilus.

**IMAGING PERFORMED BY**

Crystal Hill

**Liver**

**HOSPITAL NAME**

Beatties PH East  
Hamilton

The liver was subjectively normal in size, structure, and contour. The liver parenchyma was uniform and hypoechoic to the spleen with a mild coarse echotexture. The hepatic and portal vasculature were normal in appearance without signs of congestion. The gallbladder was non-distended in size with thin walls and primarily anechoic luminal content. The cystic and common bile ducts were normal.

**REFERRING VET**

Dr. Wittenrich

**Gastrointestinal**

The stomach presented intact wall layering with a normal wall layer ratio. The lumen of the stomach contained moderate ingesta with progressive distal acoustic shadowing with no signs of ileus, obstruction or foreign material.

**INVOICE**

11664ag

The small intestine presented intact wall layering with 1:3 muscularis/mucosa ratio. The lumen of the small intestine contained segmental to generalized non-shadowing ingesta with no signs of ileus, obstruction or foreign material. No overt evidence of pathology at the level of the ileocolic junction although indistinctly visualized.

**DATE**

09/19/2022

Normal visible colon wall layers were present with apparent formed feces in lumen.



**PATIENT** *Pancreas*

Bernie Smith The parenchyma of the left limb, body and right limb of the pancreas presented isoechoic to the adjacent omental fat. A normal curvilinear capsule contour of the pancreas was present. The visible pancreatic duct was normal. No signs of active inflammation or neoplastic disease was evident.

**SPECIES** *Free Abdomen*

Feline No omental masses, overt lymphadenopathy or peritoneal effusion was present.

**BREED** **ULTRASONOGRAPHIC FINDINGS**

- DSH
  - Urinary bladder sediment
  - Non-specific increased bilateral renal cortex echogenicity
  - Sonographically unremarkable GI tract with gastric and intestinal ingesta

**SEX** **INTERPRETATION OF THE FINDINGS & FURTHER RECOMMENDATIONS**

MN Overall, no evidence of significant visceral pathology as a cause of the patient's clinical signs. The potential for normal renal echogenicity variant is possible although non-specific nephropathy or nephritis cannot be definitively excluded.

**AGE** 8yr The urinary bladder sediment may suggest cellular / crystalline debris or mucus. Correlation with full CBC/Chem panel, UA +/- C/S if inflammatory cells is recommended.

**WEIGHT** 5.2kg A GI panel to include PLI/TLI/Cobalamin/Folate as well as three view chest radiographs and neurological / musculoskeletal examination are recommended to assess for or rule out occult disease which may cause weight loss.

**INTERPRETED BY**

R. McKenzie Daniel,  
DVM, DABVP  
(Canine and Feline)

**IMAGING PERFORMED BY**

Crystal Hill

**HOSPITAL NAME**

Beatties PH East  
Hamilton

**REFERRING VET**

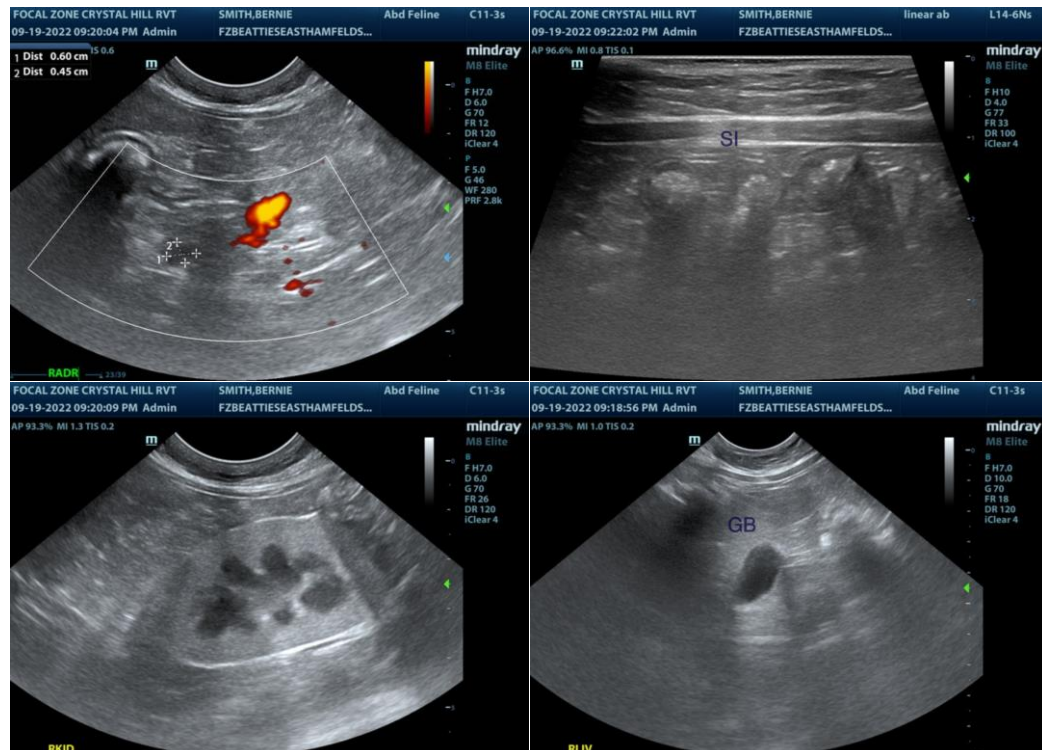
Dr. Wittenrich

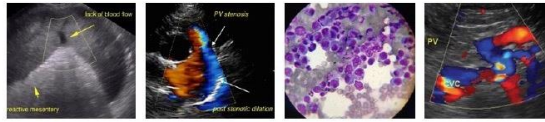
**INVOICE**

11664ag

**DATE**

09/19/2022





**PATIENT**

Bernie Smith

**SPECIES**

Feline

**BREED**

DSH

**SEX**

MN

**AGE**

8yr

**WEIGHT**

5.2kg

**INTERPRETED BY**

R. McKenzie Daniel,  
DVM, DABVP  
(Canine and Feline)

**IMAGING PERFORMED BY**

Crystal Hill

**HOSPITAL NAME**

Beatties PH East  
Hamilton

**REFERRING VET**

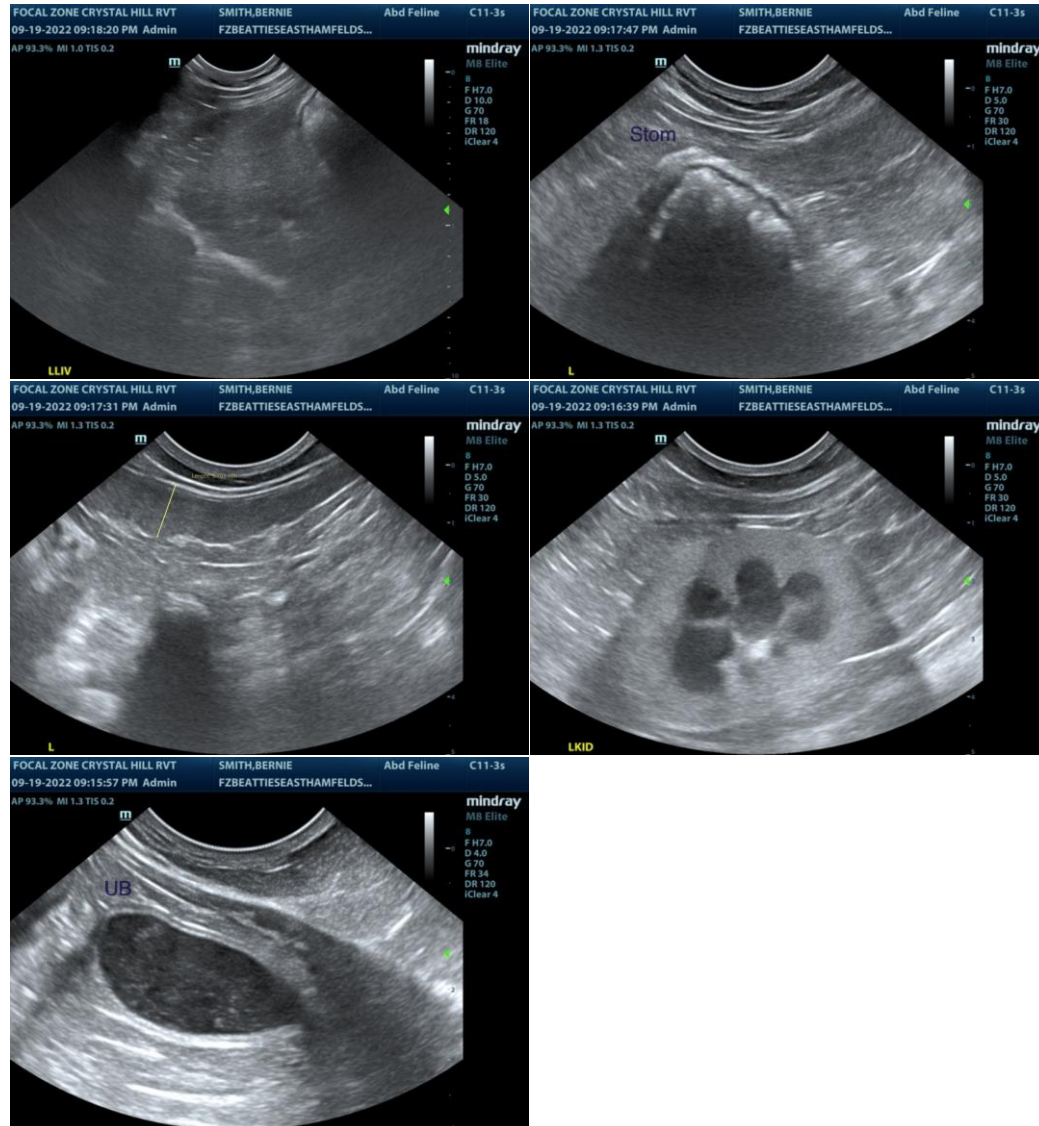
Dr. Wittenrich

**INVOICE**

11664ag

**DATE**

09/19/2022



The information and recommendations provided are based on the images presented by the referring veterinarian/sonographer. No evaluation can be communicated regarding pathology that was not visible in the image/video clips provided.

Thank you for this referral. If the clinical or image interpretation does not parallel your findings or if I can be of any further assistance please contact me.

R. McKenzie Daniel, DVM, DABVP (Canine / Feline Practice)

info@SonoPath.com