



PATIENT

Betty Ambrose

SPECIES

Canine

BREED

English Bulldog

SEX

FS

AGE

10yr

WEIGHT

65lb

INTERPRETED BY

R. McKenzie Daniel,
DVM, DABVP
(Canine and Feline)

IMAGING PERFORMED BY

Kelly Vazquez

HOSPITAL NAME

Marsh Hospital for
Animals

REFERRING VET

Dr. Milwicki

INVOICE

11642ag

DATE

09/16/2022

PRESENTING CLINICAL SIGNS

Patient with history of entrapped vulva and frequent UTIs presents for double cavity ultrasound. History of E. coli and Enterococcus.

Current meds: Gabapentin, Fluoxetine, just started Proin, but seems improved already.

ULTRASONOGRAPHIC EXAMINATION OF THE ABDOMEN AND HEART

CANINE CARDIAC PARAMETERS	MR VMAX (m/s)	TR VMAX (m/s)	LA/AO (Boon method)	LA/AO (Heart Base; Swe)	FS (%)	EF (%)	EPSS (cm)
NORMAL PARAMETER	4.5-5.5	<2.7	1.3	<1.3	28-40	40-100	<0.6
PATIENT				1.4	45	78.2	0.38
CANINE CARDIAC PARAMETERS	HR (BPM)	AV VMAX (m/s)	PV MAX (m/s)	BODY WEIGHT (kg)	LA 2D short axis Base view (cm)	LVIDd Avg; 2D and m-mode short axis (cm)	LVIDs Avg; 2D and m-mode short axis (cm)
NORMAL PARAMETER	50-100	0.7-1.7	0.7-1.6				
PATIENT	98	1.2	1.2		3.8	3.1	

Cardiac Presentation

The echocardiogram in this patient demonstrated normal left atrial size based on 3 separate methods of LA evaluation. The cranial and caudal mitral valve leaflets presented normal linear structure, extension in systole, and union in diastole with normal kinesis. The left ventricle presented thicknesses with linear contour and was not dilated nor restricted. The myocardium presented normal echogenicity without subjective evidence of significant fibrotic or ischemic disease. Contractility of the ventricular walls was adequate and in normal range for this patient evidenced by the fractional shortening measurement and subjective evaluation of the different regions of the myocardium. The left ventricular outflow tract demonstrated normal laminar flow and subjective structural integrity. The right atrium and auricle revealed normal size, structure and content. No evidence of masses was noted. Tricuspid valvular assessment demonstrated adequate linear morphology and kinesis. The right ventricle was of normal size (1/3 diameter of LV), chordae structure, myocardial echogenicity and thickness. Pulmonary outflow tract assessment revealed normal valve structure, laminar flow, and diameter (approx.1:1 pa/ao ratio). No visible pericardial or free pleura fluid was noted. The cranial mediastinum and pericardial and extra-cardiac regions were free of masses in the visible window.

Urinary System

The urinary bladder, trigone, cystourethral junction, and visible pelvic urethra to a depth of 3 cm exhibited normal thickness and tone. Anechoic urine was present in the lumen with no uroliths or sediment. The ureteral papillae were normal. The ureters were not visible which is normal. No evidence of inflammatory or neoplastic changes were noted. No evidence of urethral dilation with retained urine was present.



PATIENT	Normal size and margination was present in the kidneys. A normal 1:3 cortex / medulla ratio was maintained. The medulla and cortices were uniform in texture with some increased echogenicity and loss of corticomedullary symmetry and definition expected for the age of the patient. No evidence of pelvic dilation was present. The left kidney measured 5.5 cm in length. The right kidney measured 5.9 cm in length.
Betty Ambrose	
SPECIES	
Canine	The area of the aortic trifurcation was free of pathology.
BREED	
English Bulldog	
SEX	
FS	
AGE	
10yr	
WEIGHT	
65lb	
INTERPRETED BY	
R. McKenzie Daniel, DVM, DABVP (Canine and Feline)	
IMAGING PERFORMED BY	
Kelly Vazquez	
HOSPITAL NAME	
Marsh Hospital for Animals	
REFERRING VET	
Dr. Milwicki	
INVOICE	
11642ag	
DATE	
09/16/2022	
	ULTRASONOGRAPHIC FINDINGS

Adrenal Glands

The left adrenal gland was uniform in size and contour with a uniformly hypoechoic parenchyma. The left adrenal gland measured 0.63 cm width at the caudal pole and 0.67 cm width at the cranial pole. The right adrenal gland was uniform in size and contour with a uniformly hypoechoic parenchyma. The right adrenal gland measured 0.52 cm width at the caudal pole and 0.4 cm width at the cranial pole.

Spleen

The spleen exhibited a finely textured and homogenous parenchyma which was hyperechoic to the liver and renal cortical parenchyma. The capsule was smooth and regular without apparent expansion. The splenic vasculature at the hilus was normal in volume with no evidence of congestion or thrombosis. Acute to chronic inflammatory, neoplastic, or benign parenchyma changes were not noted.

Liver

The liver was subjectively normal in size, structure, and contour. The liver parenchyma was mildly nonuniform and hypoechoic to the spleen with a moderate coarse echotexture and subjective mild to benign parenchymal remodeling. The hepatic and portal vasculature were normal in appearance without signs of congestion.

The gallbladder was non-distended in size with thin walls and primarily anechoic luminal content. The cystic and common bile ducts were normal.

Gastrointestinal

The stomach presented intact wall layering with a normal wall layer ratio. The lumen of the stomach contained moderate ingesta exhibiting subtle progressive distal acoustic shadowing with no signs of ileus, obstruction or foreign material.

The small intestine presented intact wall layering with 1:3 muscularis/mucosa ratio. The lumen of the small intestine was empty with no signs of ileus, obstruction or foreign material.

Normal visible colon wall layers were present with apparent formed feces in lumen.

Pancreas

The parenchyma of the left limb, body and right limb of the pancreas presented isoechoic to the adjacent omental fat. A normal curvilinear capsule contour of the pancreas was present. The visible pancreatic duct was normal. No signs of active inflammation or neoplastic disease was evident.

Free Abdomen

No omental masses, overt lymphadenopathy or peritoneal effusion was present.



PATIENT

Betty Ambrose

SPECIES

Canine

BREED

English Bulldog

SEX

FS

AGE

10yr

WEIGHT

65lb

INTERPRETED BY

R. McKenzie Daniel,
DVM, DABVP
(Canine and Feline)

IMAGING PERFORMED BY

Kelly Vazquez

HOSPITAL NAME

Marsh Hospital for
Animals

REFERRING VET

Dr. Milwicki

INVOICE

11642ag

DATE

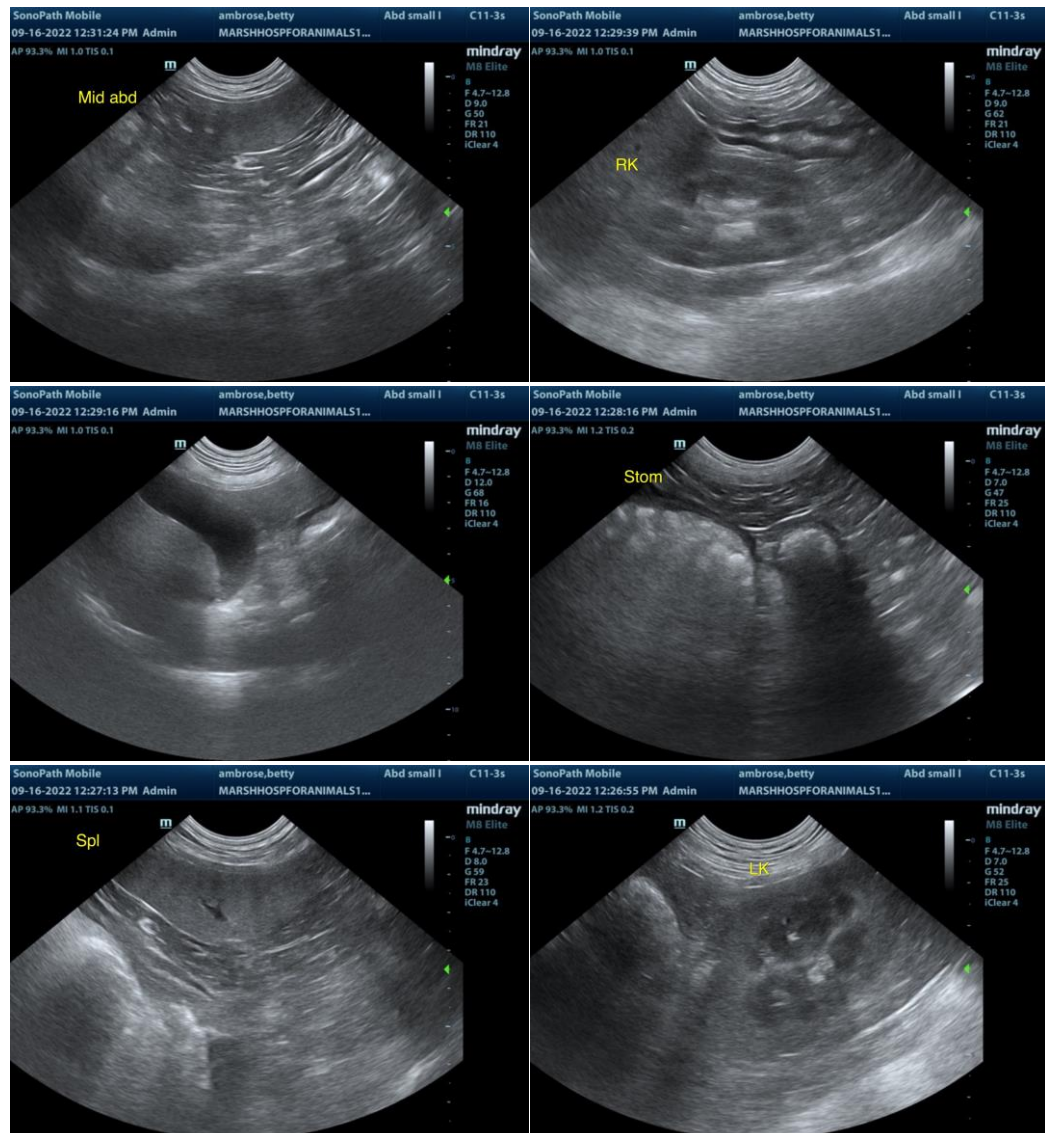
09/16/2022

Primary

- Normal echocardiogram
- Mild age-related renal changes
- Sonographically unremarkable urinary bladder and visible proximal urethra
- Gastric ingesta-probable post prandial presentation
- Minor hepatic parenchymal remodeling-benign

INTERPRETATION OF THE FINDINGS & FURTHER RECOMMENDATIONS

No evidence of cardiomyopathy or structural abdominal pathology was present in this study. Recheck urine C/S on sterile urine sample is suggested if recurrent clinical evidence of UTI.





PATIENT

Betty Ambrose

SPECIES

Canine

BREED

English Bulldog

SEX

FS

AGE

10yr

WEIGHT

65lb

INTERPRETED BY

R. McKenzie Daniel,
DVM, DABVP
(Canine and Feline)

IMAGING PERFORMED BY

Kelly Vazquez

HOSPITAL NAME

Marsh Hospital for
Animals

REFERRING VET

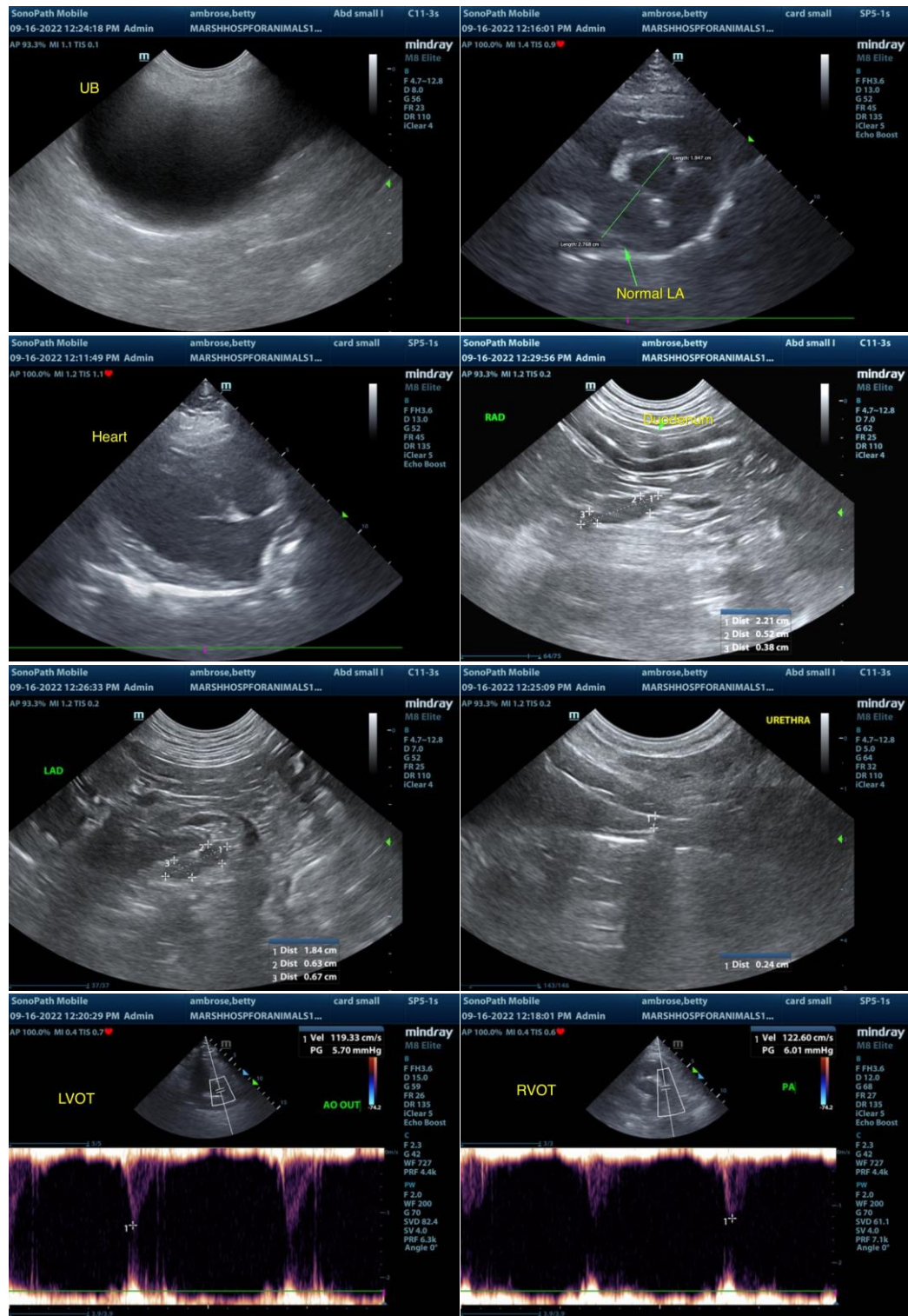
Dr. Milwicki

INVOICE

11642ag

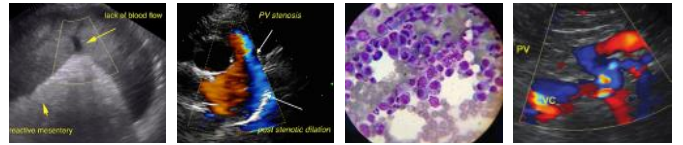
DATE

09/16/2022



The information and recommendations provided are based on the images presented by the referring veterinarian/sonographer. No evaluation can be communicated regarding pathology that was not visible in the image/video clips provided.

Thank you for this referral. If the clinical or image interpretation does not parallel your findings or if I



PATIENT

can be of any further assistance please contact me.

Betty Ambrose

R. McKenzie Daniel, DVM, DABVP (Canine / Feline Practice)

info@SonoPath.com

SPECIES

Canine

BREED

English Bulldog

SEX

FS

AGE

10yr

WEIGHT

65lb

INTERPRETED BY

R. McKenzie Daniel,
DVM, DABVP
(Canine and Feline)

**IMAGING
PERFORMED BY**

Kelly Vazquez

HOSPITAL NAME

Marsh Hospital for
Animals

REFERRING VET

Dr. Milwicki

INVOICE

11642ag

DATE

09/16/2022