

PATIENT PRESENTING CLINICAL SIGNS

Finnagan Turner History: Hematuria

SPECIES

Feline

BREED

Maine Coon

SEX

Neutered Male

AGE

13 years

WEIGHT

21.1 Pounds

ULTRASONOGRAPHIC EXAMINATION OF THE ABDOMEN AND CHEST

Urinary System

The bladder exhibited regionally thickened apical to ventroapical urinary bladder wall with mild asymmetrical luminal surface contour, as well as likely luminal surface or potentially adhered mineral. The area of apical to ventroapical thickening measured approximately 3.1 cm x 1.3 cm. Subtle adjacent prominence of ventral wall was noted caudal to the area of ventroapical thickening. The ventral wall measured 0.44 cm in width. Anechoic content was present in the bladder without sediment or calculi. The urethra presented normal thickness and tone to a depth of 2.0 cm.

The area of the aortic trifurcation was normal and without overt evidence of medial iliac or sublumbar lymphadenopathy.

Normal size and margination were present in the kidneys. A normal 1:3 cortex / medulla ratio was maintained. The medulla and cortices were uniform in texture with some increased echogenicity and mild loss of corticomedullary symmetry and definition expected for the age of the patient. No evidence of pyelectasia was present. The left kidney measured 4.2 cm in length. The right kidney measured 4.0 cm in length.

Adrenal Glands

The left adrenal gland was uniform in size and contour with a uniformly hypoechoic parenchyma. The left adrenal gland measured 0.47 cm width. The right adrenal gland was uniform in size and contour with a uniformly hypoechoic parenchyma. The right adrenal gland measured 0.54 cm width.

Spleen

The spleen exhibited a finely textured and homogenous parenchyma which was hyperechoic to the liver and renal cortical parenchyma. The capsule was smooth and regular without apparent expansion. The splenic vasculature at the hilus was normal in volume with no evidence of congestion or thrombosis. Acute to chronic inflammatory, neoplastic, or benign parenchyma changes were not noted.

Liver/ Gallbladder

The liver was subjectively normal in size, structure, and contour. The liver parenchyma was uniform and hypoechoic to the spleen with a mild coarse echotexture. The hepatic and portal vasculature were normal in appearance without signs of congestion. The diaphragm appeared to be intact. The gallbladder was non-distended in size with thin walls and primarily anechoic luminal content. The cystic and common bile ducts were normal.

Gastrointestinal

The stomach presented intact wall layering with a normal wall layer ratio. The lumen of the stomach was empty with no signs of ileus, obstruction, or foreign material.

INTERPRETED BY

R. McKenzie Daniel,
DVM, DABVP
(Canine and Feline)

IMAGING PERFORMED BY

Rebekah Jakum, CVT
ARDMS/RVT

HOSPITAL NAME

New Britain VC

REFERRING VET

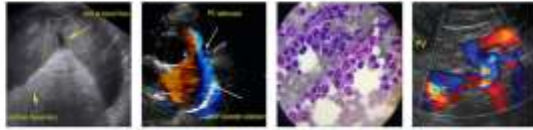
Dr. Bandekar

INVOICE

12253

DATE

9.16.2021



PATIENT

Finnagan Turner

The small intestine presented intact wall layering with 1:3 muscularis/mucosa ratio. The lumen of the small intestine was empty with no signs of ileus, obstruction, or foreign material.

Normal visible colon wall layers were present with apparent formed feces in lumen.

SPECIES

Feline

Pancreas

The parenchyma of the left limb, body, and right limb of the pancreas presented isoechoic to the adjacent omental fat. A normal curvilinear capsule contour of the pancreas was present. The visible pancreatic duct was normal. No signs of active inflammation or neoplastic disease were evident.

BREED

Maine Coon

Free Abdomen

No overt peritoneal effusion was present.

SEX

Neutered Male

Sonographic assessment of the thorax revealed unremarkable lung and pleural interface, without evidence of pleural effusion or peripheral nodules, or space-occupying masses. No evidence of pericardial effusion or pericardial masses.

AGE

13 years

ULTRASONOGRAPHIC FINDINGS

- Regionally thickened apical to ventroapical urinary bladder wall with luminal surface to potentially adhered mineral
- Mild age-related kidneys
- Sonographically unremarkable liver with intact diaphragm
- Sonographically unremarkable lung and pericardial space

WEIGHT

21.1 Pounds

INTERPRETED BY

R. McKenzie Daniel,
DVM, DABVP
(Canine and Feline)

INTERPRETATION OF THE FINDINGS & FURTHER RECOMMENDATIONS

Primary considerations for the thickened apical to ventroapical urinary bladder wall may include regional chronic cystitis with primary concern for mural mass such as transitional cell carcinoma, squamous cell carcinoma, adenocarcinoma, leiomyoma, leiomyosarcoma, or other. Biopsy of this area would be required for a definitive diagnosis. Subjectively, the area of thickened apical to ventroapical urinary bladder wall may be amendable to surgical resection based on location and size. No overt evidence of regional metastasis was noted.

IMAGING PERFORMED BY

Rebekah Jakum, CVT
ARDMS/RVT

HOSPITAL NAME

New Britain VC

REFERRING VET

Dr. Bandekar

INVOICE

12253

DATE

9.16.2021



PATIENT

Finnagan Turner

SPECIES

Feline

BREED

Maine Coon

SEX

Neutered Male

AGE

13 years

WEIGHT

21.1 Pounds

INTERPRETED BY

R. McKenzie Daniel,
DVM, DABVP
(Canine and Feline)

IMAGING PERFORMED BY

Rebekah Jakum, CVT
ARDMS/RVT

HOSPITAL NAME

New Britain VC

REFERRING VET

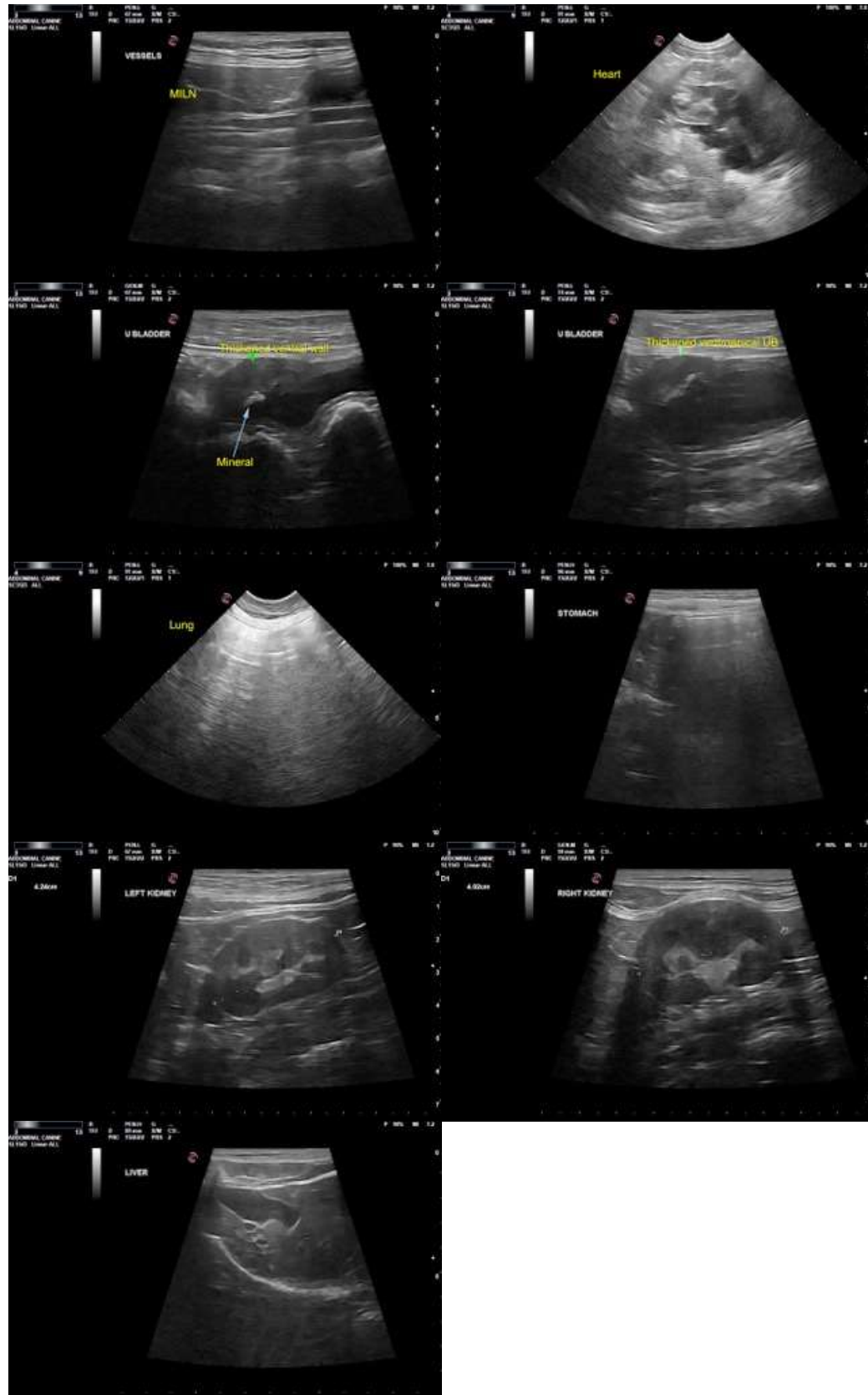
Dr. Bandekar

INVOICE

12253

DATE

9.16.2021





PATIENT

Finnagan Turner

SPECIES

Feline

The information and recommendations provided are based on the images presented by the referring veterinarian. No evaluation can be communicated regarding pathology that was not visible in the image/video clips provided.

BREED

Maine Coon

Thank you for this referral. If the clinical or image interpretation does not parallel your findings or if I can be of any further assistance please contact me.

SEX

Neutered Male

R. McKenzie Daniel, DVM, DABVP (Canine/Feline Practice)
mac.daniel@sonopath.com

AGE

13 years

WEIGHT

21.1 Pounds

INTERPRETED BY

R. McKenzie Daniel,
DVM, DABVP
(Canine and Feline)

**IMAGING
PERFORMED BY**

Rebekah Jakum, CVT
ARDMS/RVT

HOSPITAL NAME

New Britain VC

REFERRING VET

Dr. Bandekar

INVOICE

12253

DATE

9.16.2021