



## PATIENT

Rocky Phillip

## SPECIES

Canine

## BREED

Chihuahua Mix

## SEX

Intact Male

## AGE

4 Years

## WEIGHT

22.7 Pounds

## PRESENTING CLINICAL SIGNS

History: Patient presents for echo due to upcoming anesthetic procedure; safe to go under anesthesia? No reported meds.

Abnormal PE/Chem/CBC/UA Results:

## ULTRASONOGRAPHIC EXAMINATION OF THE HEART

CANINE CARDIAC PARAMETERS	MR VMAX (m/s)	TR VMAX (m/s)	LA/AO (Boon method)	LA/AO (Heart Base; Swe)	FS (%)	EF (%)	EPSS (cm)
NORMAL PARAMETER	4.5-5.5	<2.7	1.3	<1.6	28-40	40-100	<0.6
PATIENT	--	--	1.1	1.2	36.6	68.5	0.12
CANINE CARDIAC PARAMETERS	HR (BPM)	AV VMAX (m/s)	PV MAX (m/s)	BODY WEIGHT (kg)	LA 2D short axis Base view (cm)	LVIDd Avg; 2D and m-mode short axis (cm)	LVIDs Avg; 2D and m-mode short axis (cm)
NORMAL PARAMETER	50-100	0.7-1.7	0.7-1.6	BELOW	BELOW	BELOW	BELOW
PATIENT	94	1.47	1.0	--	2.5	2.7	--

## INTERPRETED BY

R. McKenzie Daniel,  
DVM, DABVP  
(Canine and Feline)

## IMAGING PERFORMED BY

Kelly Vazquez

## HOSPITAL NAME

Animal Paradise H

## REFERRING VET

Dr. Elshafie

## INVOICE

13046

## DATE

9/15/21

## Cardiac Presentation

The echocardiogram in this patient demonstrated normal **left atrial** size based on 3 separate methods of LA evaluation. The cranial and caudal **mitral** valve leaflets presented normal linear structure, extension in systole, and union in diastole with normal kinesis. Color doppler assessment revealed mild mitral valve insufficiency. The **left ventricle** presented thicknesses with linear contour and was not dilated nor restricted. The **myocardium** presented normal echogenicity without subjective evidence of significant fibrotic or ischemic disease. **Contractility** of the ventricular walls was adequate and in normal range for this patient evidenced by the fractional shortening measurement and subjective evaluation of the different regions of the myocardium. The **left ventricular outflow** tract demonstrated normal laminar flow and subjective structural integrity. The **right atrium** and auricle revealed normal size, structure and content. No evidence of masses was noted. **Tricuspid** valvular assessment demonstrated adequate linear morphology and kinesis. The **right ventricle** was of normal size (1/3 diameter of LV), chordae structure, myocardial echogenicity and thickness. **Pulmonary outflow** tract assessment revealed normal valve structure, laminar flow, and diameter (approx.1:1 pa/ao ratio). No visible **pericardial** or free pleura fluid was noted. The cranial **mediastinum and pericardial and extra-cardiac regions** were free of masses in the visible window.

## ULTRASONOGRAPHIC FINDINGS

- Normal cardiac structure and function



## PATIENT

- Mild mitral valve insufficiency

Rocky Phillip

## INTERPRETATION OF THE FINDINGS & FURTHER RECOMMENDATIONS

No evidence of structural or functional cardiomyopathy. The mild mitral valve insufficiency is not considered clinically significant given the lack of left atrium enlargement. No indication for cardiac medications or anesthetic contraindications. Recheck echocardiogram suggested in 12 months or sooner if clinical signs consistent with heart disease develop.

## SPECIES

Canine

## BREED

Chihuahua Mix

## SEX

Intact Male

## AGE

4 Years

## WEIGHT

22.7 Pounds

## INTERPRETED BY

R. McKenzie Daniel,  
DVM, DABVP  
(Canine and Feline)

## IMAGING PERFORMED BY

Kelly Vazquez

## HOSPITAL NAME

Animal Paradise H

## REFERRING VET

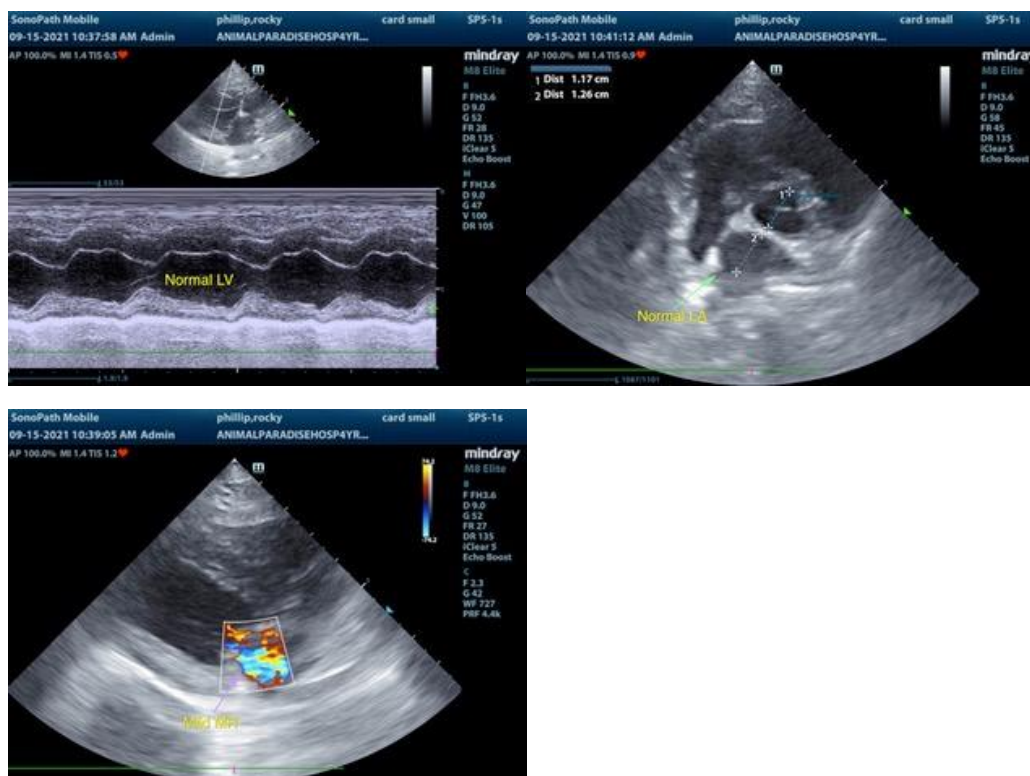
Dr. Elshafie

## INVOICE

13046

## DATE

9/15/21



The information and recommendations provided are based on the images presented by the referring veterinarian. No evaluation can be communicated regarding pathology that was not visible in the image/video clips provided.

Thank you for this referral. If the clinical or image interpretation does not parallel your findings or if I can be of any further assistance please contact me.

**R. McKenzie Daniel, DVM, DABVP (Canine / Feline Practice)**  
info@SonoPath.com