



PATIENT

Cain Bennett

SPECIES

Feline

BREED

DSH

SEX

Neutered Male

AGE

13 years

WEIGHT

7.7

INTERPRETED BY

R. McKenzie Daniel,
DVM, DABVP
(Canine and Feline)

IMAGING PERFORMED BY

Rachel Runnells, RVT

HOSPITAL NAME

SVS Imaging KC

REFERRING VET

Dr. Jennifer Kissinger

INVOICE

12249

DATE

9/15/21

PRESENTING CLINICAL SIGNS

Anorexia, weight loss, lethargy.

Abnormal PE/Chem/CBC/UA Results: Generalized loss of muscle mass, unkempt coat, >7% dehydrated, thickened/sloshy gut on abdominal palpation, pale MM and mildly icteric. Radiographs: poor serosal detail in abdomen. Intestines look thickened. CBC: non-regenerative anemia, thrombocytopenia, neutrophilia, lymphopenia. No evidence of hemotropic mycoplasma on blood smear. Chem: Albumin 2.3 (2.6-3.9), Globulins 6.1 (3.0-5.9) ALT 19 (27-158), total bilirubin 0.7. UA: USG 1.040, pH 6.5, trace protein, few rbc and wbc, urobilinogen. T4 1.4 (0.8-4.7) FELV/FIV: Negative for both. Aspirated yellow viscous fluid from abdomen.

ULTRASONOGRAPHIC EXAMINATION OF THE ABDOMEN

Urinary System

The urinary bladder, trigone, cystourethral junction, and visible pelvic urethra to a depth of 2.0 cm exhibited normal thickness and tone. Moderate, nondependent to swirling particulate sediment was present without evidence of calculus formation. Anechoic urine was present in the lumen with no uroliths or sediment. The ureteral papillae were normal. The ureters were not visible which is normal. No evidence of inflammatory or neoplastic changes was noted.

The area of the aortic trifurcation was free of pathology.

Normal size and margination were present in the kidneys. A normal 1:3 cortex / medulla ratio and normal corticomedullary definition were maintained. The echogenicity of the cortex was similar to or slightly less than normal liver parenchyma while the medulla echogenicity was hypoechoic to the cortex with no evidence of pelvic dilation. Right and left kidney primarily uniform cortical hypertrophy was present. No evidence of pyelectasia was noted. A hyperechoic corticomedullary band, consistent with a medullary rim sign, was present. This is a nonspecific finding seen in both normal and abnormal kidneys. It may be associated interstitial renal disease, hypercalcemia, tubular necrosis, lymphoma, and FIP. However, it is a nonspecific finding. The left kidney measured 4.1 cm in length. The right kidney measured 3.9 cm in length.

Adrenal Glands

The left adrenal gland was uniform in size and contour with a uniformly hypoechoic parenchyma. The left adrenal gland measured 0.27 cm width. The right adrenal gland was uniform in size and contour with a uniformly hypoechoic parenchyma. The right adrenal gland measured 0.33 cm width.

Spleen

The spleen exhibited a finely textured and homogenous parenchyma which was hyperechoic to the liver and renal cortical parenchyma. The capsule was smooth and regular without apparent expansion. The splenic vasculature at the hilus was normal in volume with no evidence of congestion or thrombosis. Acute to chronic inflammatory, neoplastic, or benign parenchyma changes were not noted.

Liver/ Gallbladder

The liver was subjectively normal in size, structure, and contour. The liver parenchyma was uniform and hypoechoic to the spleen with a mild coarse echotexture. The hepatic and portal vasculature were



PATIENT

Cain Bennett

normal in appearance without signs of congestion. The gallbladder was non-distended in size with thin walls and primarily anechoic luminal content. The cystic and common bile ducts were normal.

SPECIES

Feline

Gastrointestinal

The stomach exhibited gas distention. The visualized gastric walls were sonographically unremarkable. The gastric body wall width measured 0.24 cm. The lumen of the stomach was empty with no signs of ileus, obstruction, or foreign material.

BREED

DSH

The small intestine presented intact wall layering and primarily maintained a 1:3 muscularis/mucosa ratio without evidence of mural hypertrophy, loss of intestinal wall layering, or obvious intestinal masses. Generalized echogenic nonshadowing chyme was present in the intestinal lumen. The duodenum wall width measured 0.26 cm. The jejunum wall width measured 0.20 cm.

SEX

Neutered Male

Normal visible colon wall layers were present with apparent formed feces in lumen.

AGE

13 years

Pancreas

The left limb, right limb, and base of the pancreas presented hypoechoic to heterogeneous echogenicity compared to adjacent omental fat. Mild asymmetrical capsule margination was present with mild variable parenchymal swelling and mild peripancreatic reactivity / inflammation. No overt evidence of neoplasia.

WEIGHT

7.7

INTERPRETED BY

R. McKenzie Daniel,
DVM, DABVP
(Canine and Feline)

Free Abdomen

Generalized primarily uniform hyperechoic omentum along with subjective moderate peritoneal free fluid were present. No overt lymphadenopathy was noted.

ULTRASONOGRAPHIC FINDINGS

IMAGING PERFORMED BY

Primary Findings

- Bilateral chronic renal changes with prominent nonspecific medullary rim sign
- Active to chronic active pancreatitis
- Generalized peritonitis exhibited by primarily uniform hyperechoic omentum and peritoneal effusion
- Possible generalized gastrointestinal hypomotility

Rachel Runnells, RVT

HOSPITAL NAME

SVS Imaging KC

INTERPRETATION OF THE FINDINGS & FURTHER RECOMMENDATIONS

Recommend abdominocentesis, cytospin cytology with rapid slide preparation +/- C/S if evidence of inflammatory cells. FIP may be considered a top differential diagnosis in this case, even in light of the patient's advanced age. Therefore, FIP testing / titers on the fluid may be considered.

REFERRING VET

Dr. Jennifer Kissinger

INVOICE

12249

DATE

9/15/21

Other differentials may include inflammatory effusion owing to pancreatitis and/or neoplastic process such as carcinomatosis, lymphomatosis, or similar.

Assuming normal albumin levels, no overt evidence of overt hepatic or gastrointestinal pathology which may result in an effusion of this nature.



PATIENT

Cain Bennett

SPECIES

Feline

BREED

DSH

SEX

Neutered Male

AGE

13 years

WEIGHT

7.7

INTERPRETED BY

R. McKenzie Daniel,
DVM, DABVP
(Canine and Feline)

IMAGING PERFORMED BY

Rachel Runnells, RVT

HOSPITAL NAME

SVS Imaging KC

REFERRING VET

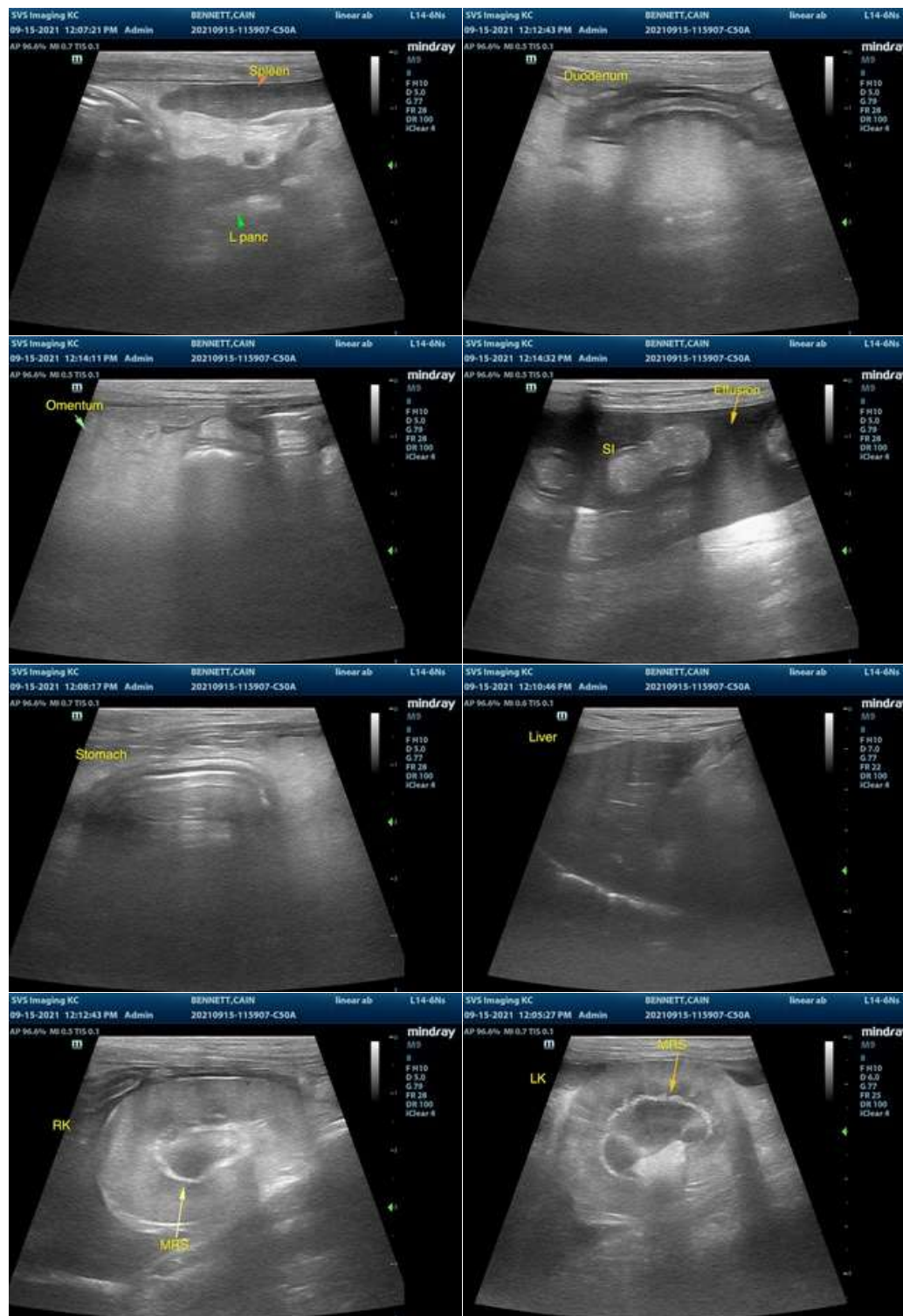
Dr. Jennifer Kissinger

INVOICE

12249

DATE

9/15/21





PATIENT

Cain Bennett

SPECIES

Feline

BREED

DSH

SEX

Neutered Male

AGE

13 years

WEIGHT

7.7

INTERPRETED BY

R. McKenzie Daniel,
DVM, DABVP
(Canine and Feline)

IMAGING PERFORMED BY

Rachel Runnells, RVT

HOSPITAL NAME

SVS Imaging KC

REFERRING VET

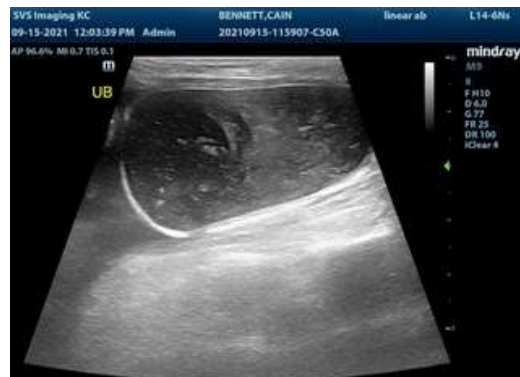Dr. Jennifer Kissinger

INVOICE

12249

DATE

9/15/21



The information and recommendations provided are based on the images presented by the referring veterinarian. No evaluation can be communicated regarding pathology that was not visible in the image/video clips provided.

Thank you for this referral. If the clinical or image interpretation does not parallel your findings or if I can be of any further assistance please contact me.

R. McKenzie Daniel, DVM, DABVP (Canine / Feline Practice)
info@SonoPath.com