



## PATIENT

Savannah Cardone

## SPECIES

Canine

## BREED

Mixed breed

## SEX

FS

## AGE

12.5 yrs

## WEIGHT

74.5 lbs

## INTERPRETED BY

R. McKenzie Daniel,  
DVM, DABVP  
(Canine and Feline)

## IMAGING PERFORMED BY

Kelly Vazquez

## HOSPITAL NAME

New Bridge  
Veterinary

## REFERRING VET

Dr. Abina Glennon

## INVOICE

14865

## DATE

9-14-22

## PRESENTING CLINICAL SIGNS

Patient presents for cough; no murmur heard.

## ULTRASONOGRAPHIC EXAMINATION OF THE HEART

CANINE	MR	TR	LA/AO	LA/AO	FS	EF	EPSS
<b>CARDIAC PARAMETERS</b>	<b>VMAX</b> (m/s)	<b>VMAX</b> (m/s)	(Boon method)	(Heart Base; Swe)	(%)	(%)	(cm)
<b>NORMAL PARAMETER</b>	4.5-5.5	<2.7	1.3	<1.3	28-40	40-100	<0.6
<b>PATIENT</b>			1.2	1.0	34.1	66.6	0.31
CANINE	HR	AV	PV	BODY WEIGHT	LA	LVIDd	LVIDs
<b>CARDIAC PARAMETERS</b>	(BPM)	<b>VMAX</b> (m/s)	<b>MAX</b> (m/s)	(kg)	2D short axis Base view (cm)	Avg; 2D and m-mode short axis (cm)	Avg; 2D and m-mode short axis (cm)
<b>NORMAL PARAMETER</b>	50-100	0.7-1.7	0.7-1.6				
<b>PATIENT</b>	101	1.3	1.0		4.2	4.1	

### Cardiac Presentation

The echocardiogram in this patient demonstrated normal **left atrial** size based on 3 separate methods of LA evaluation. The cranial and caudal **mitral** valve leaflets presented normal linear structure, extension in systole, and union in diastole with normal kinesis. Trace MR was present on doppler. The **left ventricle** presented normal thicknesses with linear contour and was not dilated nor restricted. The **myocardium** presented normal echogenicity without subjective evidence of significant fibrotic or ischemic disease. **Contractility** of the ventricular walls was adequate and in normal range for this patient evidenced by the fractional shortening measurement and subjective evaluation of the different regions of the myocardium. The **left ventricular outflow** tract demonstrated normal laminar flow and subjective structural integrity. The **right atrium** and auricle revealed normal size, structure and content. No evidence of masses was noted. **Tricuspid** valvular assessment demonstrated adequate linear morphology and kinesis. No TR was present. The **right ventricle** was of normal size (1/3 diameter of LV), chordae structure, myocardial echogenicity and thickness. **Pulmonary outflow** tract assessment revealed normal valve structure, laminar flow, and diameter (approx.1:1 pa/ao ratio). No visible **pericardial** or free pleura fluid was noted. The cranial **mediastinum and pericardial and extra-cardiac regions** were free of masses in the visible window.

### ULTRASONOGRAPHIC FINDINGS

- Normal echocardiogram
- Trace MR



**PATIENT**

Savannah Cardone

**SPECIES**

Canine

**BREED**

Mixed breed

**SEX**

FS

**AGE**

12.5 yrs

**WEIGHT**

74.5 lbs

**INTERPRETED BY**

R. McKenzie Daniel,  
DVM, DABVP  
(Canine and Feline)

**IMAGING PERFORMED BY**

Kelly Vazquez

**HOSPITAL NAME**

New Bridge  
Veterinary

**REFERRING VET**

Dr. Abina Glennon

**INVOICE**

14865

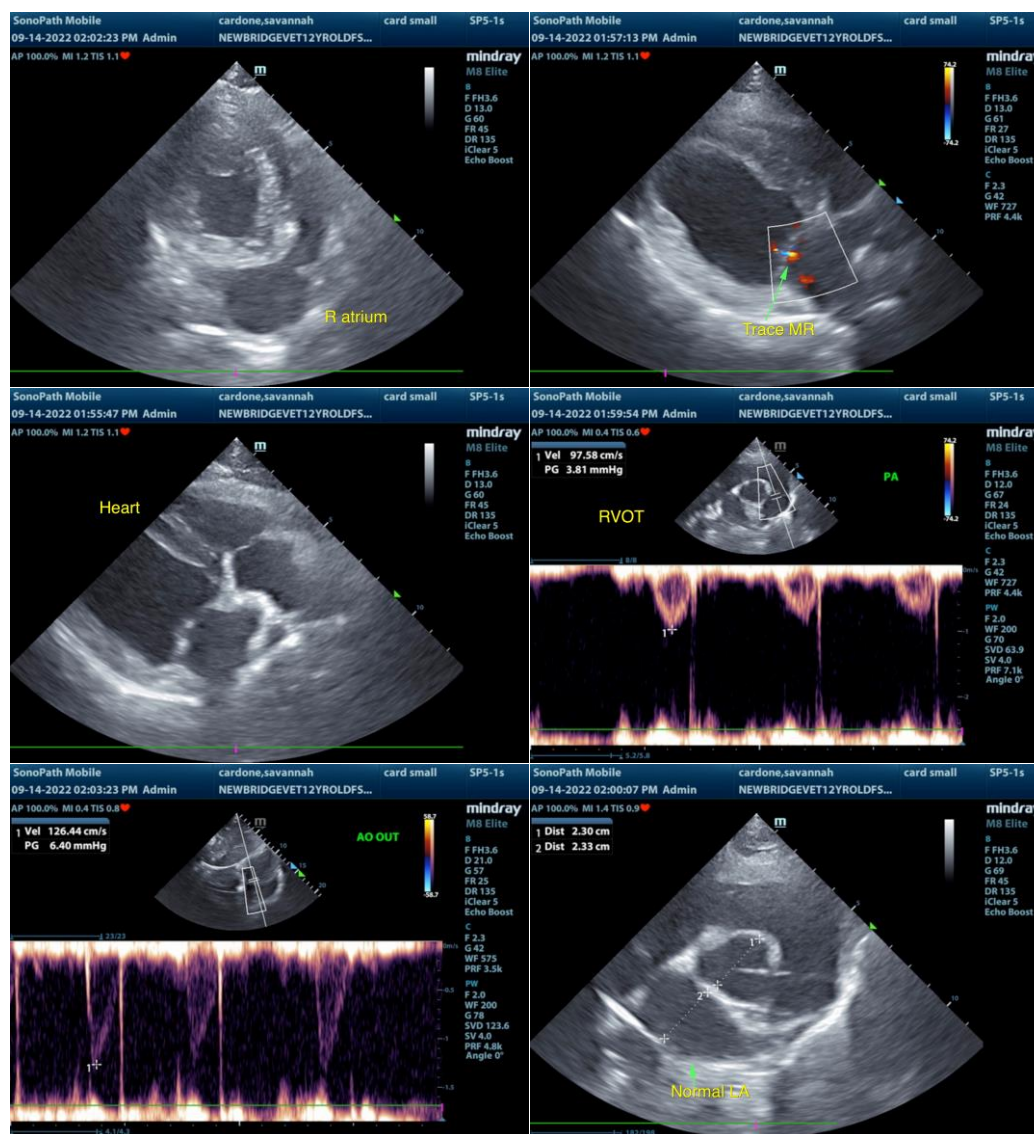
**DATE**

9-14-22

**INTERPRETATION OF THE FINDINGS & FURTHER RECOMMENDATIONS**

Overall normal cardiac structure and function without evidence of structural or functional cardiomyopathy, LV systolic dysfunction, left or right heart chamber enlargement, or clinical pulmonary hypertension.

Overall, the heart was not consistent with cardiogenic cough. Primary upper or lower airway disease is considered most probable for the underlying cause of the cough in this patient. A heartworm test may be considered if not recently done. No indication for cardiac medications is evident. As-needed respiratory support and/or lower airway sampling may be considered.





**PATIENT**

Savannah Cardone

**SPECIES**

Canine

**BREED**

Mixed breed

**SEX**

FS

**AGE**

12.5 yrs

**WEIGHT**

74.5 lbs

**INTERPRETED BY**

R. McKenzie Daniel,  
DVM, DABVP  
(Canine and Feline)

**IMAGING PERFORMED BY**

Kelly Vazquez

**HOSPITAL NAME**

New Bridge  
Veterinary

**REFERRING VET**

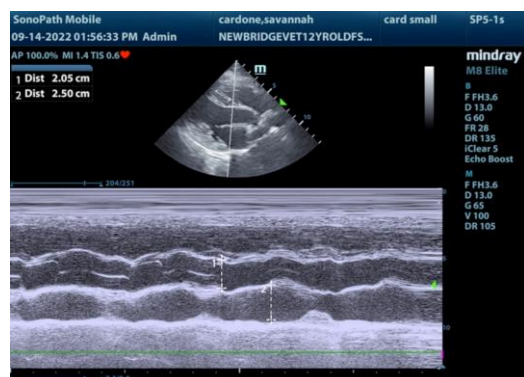
Dr. Abina Glennon

**INVOICE**

14865

**DATE**

9-14-22



The information and recommendations provided are based on the images presented by the referring veterinarian/sonographer. No evaluation can be communicated regarding pathology that was not visible in the image/video clips provided.

Thank you for this referral. If the clinical or image interpretation does not parallel your findings or if I can be of any further assistance please contact me.

**R. McKenzie Daniel, DVM, DABVP (Canine / Feline Practice)**  
info@SonoPath.com