



PATIENT

Marley Daly

SPECIES

Feline

BREED

DLH

SEX

Neutered Male

AGE

13 years

WEIGHT

11.3 lbs.

INTERPRETED BY

R. McKenzie Daniel,
DVM, DABVP
(Canine and Feline)

IMAGING PERFORMED BY

Diane McFadden

HOSPITAL NAME

Animal Care Centers
of Flanders

REFERRING VET

Dr. Hallihan

INVOICE

12233

DATE

9/14/21

PRESENTING CLINICAL SIGNS

2-3/6 systolic murmur (louder); iris stage 2 renal with wt loss; assess for possible dental
Abnormal PE/Chem/CBC/UA Results: BUN 31, crea 2.1

ULTRASONOGRAPHIC EXAMINATION OF THE HEART & ABDOMEN

FELINE CARDIAC PARAMETERS	BODY WEIGHT (kg)	HR (BPM)	IVSd (cm)	LVIDd (cm)	LVWd (cm)	FS (%)	EF (%)
NORMAL PARAMETER	-----	150-240	0.3-0.6	1.0-2.1	0.25-0.6	35-67	80-100
PATIENT		197	0.62	1.52	0.57	55.9	90.6
FELINE CARDIAC PARAMETERS	LA/AO (Boon)	LA/AO HEART BASE (Sisson)	LA 2D 4-chamber long axis AS to FW (Sisson) (cm)	LVOT VEL. (m/s)	RVOT VEL. (m/s)	IVRT (m)	
NORMAL PARAMETER	<1.5	0.88-1.79	0.7-1.7	<1.6	<1.3	40-60	
PATIENT	1.43	1.33	1.35	1.22	1.2	NM	
Adapted from June Boon, Veterinary Echocardiography, 1998 Sisson D et al. JVIM 1991; 5: 232, Jacobs et al. Am J Vet Res 1985; 46:1705							

Cardiac Presentation

The echocardiogram in this patient demonstrated normal **left atrial** size and structure with no evidence of "smoke" or thrombi. The cranial and caudal **mitral** valve leaflets appeared mildly thickened without overt insufficiency, yet potential for mild SAM. The **left ventricle** presented borderline excessive free wall and septal thicknesses with subjective hypertrophic tendencies noted in both the septum and free wall compared to normal for this species. The **myocardium** presented essentially normal echogenicity without immediate signs of fibrotic or ischemic disease. **Contractility** of the ventricular walls was considered excessive for this patient evidenced by the elevated fractional shortening measurement. The **left ventricular outflow** tract demonstrated turbulent laminar flow. Subjective assessment of the **right atrium** and auricle revealed normal size, structure and content. No evidence of masses was noted. **Tricuspid** valvular assessment demonstrated linear morphology. The **right ventricle** was of normal size with normal chordae structure, myocardial echogenicity and thickness. **Pulmonic** tract assessment revealed normal valve structure, laminar flow, and diameter. No visible **pericardial** or free pleura fluid was noted. No echographically detectable evidence of infiltrative disease was visible. The **mediastinum** was free of masses in the visible window.

Urinary System

The urinary bladder, trigone, cystourethral junction, and visible pelvic urethra to a depth of 2.0 cm exhibited normal thickness and tone. Anechoic urine was present in the lumen with no uroliths or



PATIENT	sediment. The ureteral papillae were normal. The ureters were not visible which is normal. No evidence of inflammatory or neoplastic changes was noted.
Marley Daly	
SPECIES	The area of the aortic trifurcation was free of pathology.
Feline	Normal size and margination were present in the kidneys. A normal 1:3 cortex / medulla ratio was maintained. The medulla and cortices were uniform in texture with some increased echogenicity and mild loss of corticomedullary symmetry and definition expected for the age of the patient. No evidence of pelvic dilation was present. The left kidney measured 3.7 cm in length. The right kidney measured 3.7 cm in length.
BREED	
DLH	
SEX	Adrenal Glands
Neutered Male	The left adrenal gland was uniform in size and contour with a uniformly hypoechoic parenchyma. The left adrenal gland measured 0.32 cm width. The right adrenal gland was uniform in size and contour with a uniformly hypoechoic parenchyma. The right adrenal gland measured 0.33 cm width.
AGE	Spleen
13 years	The spleen exhibited a finely textured and homogenous parenchyma which was hyperechoic to the liver and renal cortical parenchyma. The capsule was smooth and regular without apparent expansion. The splenic vasculature at the hilus was normal in volume with no evidence of congestion or thrombosis. Acute to chronic inflammatory, neoplastic, or benign parenchyma changes were not noted. The spleen measured 1.0 cm in width at the level of the hilus.
WEIGHT	Liver/ Gallbladder
11.3 lbs.	The liver was subjectively normal in size, structure, and contour. The liver parenchyma was uniform and hypoechoic to the spleen with a mild coarse echotexture. The hepatic and portal vasculature were normal in appearance without signs of congestion. The gallbladder was non-distended in size. Generalized yet variable common bile duct dilation was present extending to the approximate level of the duodenal papilla. The common bile duct dilation measured 0.33 to 0.46 cm. A solitary small mildly shadowing calculus was present in the distal common bile duct potentially approaching the area of the duodenal papilla. The calculus measured approximately 0.30 cm in diameter. No other evidence of gallbladder or common bile duct calculi or evidence of evidence of mucoduct. No evidence of regional associated inflammation or peritonitis.
INTERPRETED BY	Gastrointestinal
R. McKenzie Daniel, DVM, DABVP (Canine and Feline)	The stomach presented intact wall layering with a normal wall layer ratio. The lumen of the stomach was empty with no signs of ileus, obstruction, or foreign material. The pylorus wall width measured 0.25 cm.
IMAGING PERFORMED BY	
Diane McFadden	
HOSPITAL NAME	
Animal Care Centers of Flanders	
REFERRING VET	
Dr. Hallihan	
INVOICE	
12233	The small intestine presented intact wall layering with 1:3 muscularis/mucosa ratio. The lumen of the small intestine was empty with no signs of ileus, obstruction, or foreign material. The duodenum wall width measured 0.24 cm. The ileocolic wall width measured 0.33 cm. The jejunum wall width measured 0.23 cm.
DATE	
9/14/21	Normal visible colon wall layers were present with apparent formed feces in lumen.



PATIENT

Marley Daly

SPECIES

Feline

BREED

DLH

SEX

Neutered Male

AGE

13 years

WEIGHT

11.3 lbs.

INTERPRETED BY

R. McKenzie Daniel,
DVM, DABVP
(Canine and Feline)

IMAGING PERFORMED BY

Diane McFadden

HOSPITAL NAME

Animal Care Centers
of Flanders

REFERRING VET

Dr. Hallihan

INVOICE

12233

DATE

9/14/21

Pancreas

The parenchyma of the left limb, body, and right limb of the pancreas presented isoechoic to the adjacent omental fat. A normal curvilinear capsule contour of the pancreas was present. The visible pancreatic duct was normal. No signs of active inflammation or neoplastic disease were evident.

Free Abdomen

No overt lymphadenopathy or peritoneal effusion was present.

ULTRASONOGRAPHIC FINDINGS

Primary Findings

- Borderline hypertrophic IVS and LV free wall changes
- Normal left atrium
- Bilateral mild chronic renal changes
- Generalized to variably common bile duct dilation with distal focal choledocholith

INTERPRETATION OF THE FINDINGS & FURTHER RECOMMENDATIONS

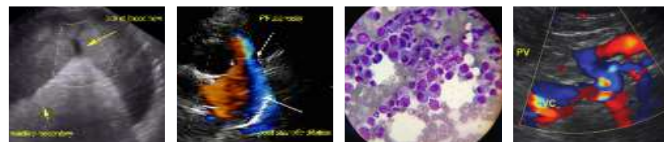
The heart exhibited subjective borderline hypertrophic left ventricular changes yet the normal left atrium size indicates that the risk of future complication is low at this time. The murmur in this patient may be a physiologic or flow murmur, yet potential for mild SAM is possible. Regardless, cardiac medications are not indicated. T4 levels are recommended if not recently done. Recheck echocardiogram is suggested in 6 months, sooner if clinical signs consistent with heart disease develop. No overt anesthetic contraindications. The following anesthetic protocol or similar protocol is suggested.

Suggested anesthetic protocol may include opioid or Benzodiazepine pre-med, induction with Propofol or Alfaxalone, and appropriate gas anesthesia with avoidance of alpha 2 agonists.

Given the lack of hepatic enzyme elevations or cholestasis reported, the common bile duct calculus and associated common bile duct dilation are not considered a clinical emergency at this point.

However, close monitoring of clinical signs or evidence of increasing hepatic enzyme elevations is recommended while eventual surgical intervention may be required if these signs are noted.

A GI panel to include PLI/TLI/Cobalamin/Folate as well as three view chest radiographs and neurological examination are recommended to assess for or rule out occult disease which may cause weight loss.



PATIENT

Marley Daly

SPECIES

Feline

BREED

DLH

SEX

Neutered Male

AGE

13 years

WEIGHT

11.3 lbs.

INTERPRETED BY

R. McKenzie Daniel,
DVM, DABVP
(Canine and Feline)

IMAGING PERFORMED BY

Diane McFadden

HOSPITAL NAME

Animal Care Centers
of Flanders

REFERRING VET

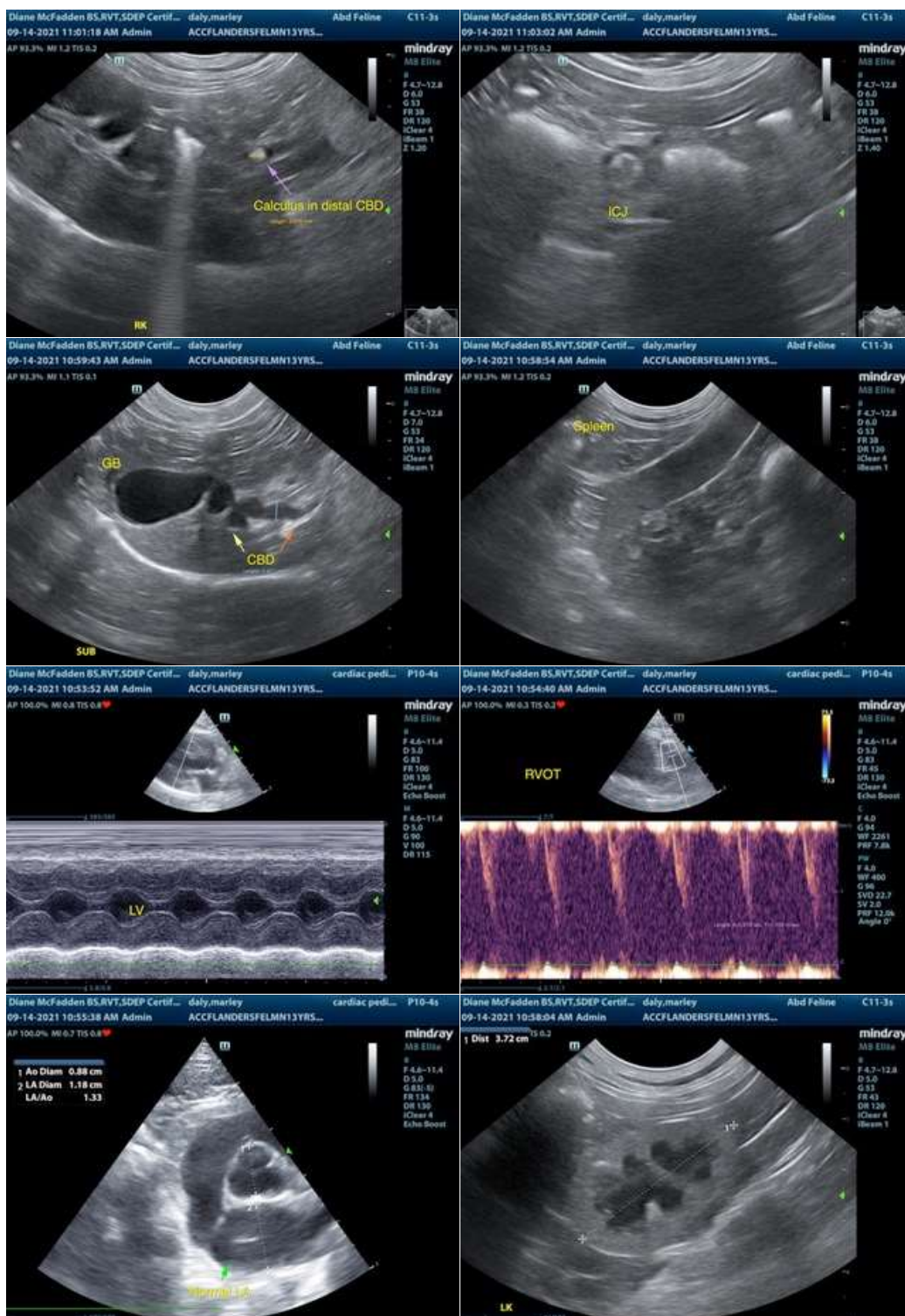
Dr. Hallihan

INVOICE

12233

DATE

9/14/21





PATIENT

Marley Daly

SPECIES

Feline

BREED

DLH

SEX

Neutered Male

AGE

13 years

WEIGHT

11.3 lbs.

INTERPRETED BY

R. McKenzie Daniel,
DVM, DABVP
(Canine and Feline)

IMAGING PERFORMED BY

Diane McFadden

HOSPITAL NAME

Animal Care Centers
of Flanders

REFERRING VET

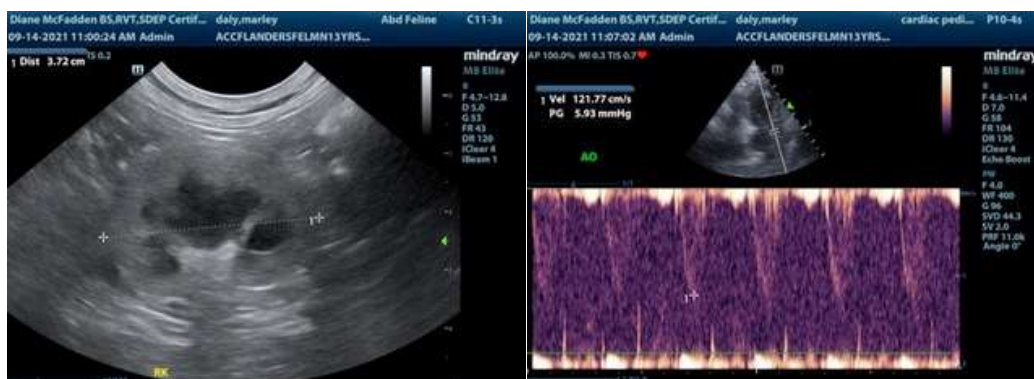Dr. Hallihan

INVOICE

12233

DATE

9/14/21



The information and recommendations provided are based on the images presented by the referring veterinarian. No evaluation can be communicated regarding pathology that was not visible in the image/video clips provided.

Thank you for this referral. If the clinical or image interpretation does not parallel your findings or if I can be of any further assistance please contact me.

R. McKenzie Daniel, DVM, DABVP (Canine / Feline Practice)
info@SonoPath.com