



PATIENT PRESENTING CLINICAL SIGNS

Dakota Judge Anorexic, losing weight, Vomits or regurge. 10lbs weight loss in 5 months
Abnormal PE/Chem/CBC/UA Results: WNL

SPECIES ULTRASONOGRAPHIC EXAMINATION OF THE HEART & ABDOMEN

Canine

BREED

Husky

SEX

Spayed Female

AGE

12 Years

WEIGHT

43 Pounds

CANINE CARDIAC PARAMETERS	MR VMAX (m/s)	TR VMAX (m/s)	LA/AO (Boon method)	LA/AO (Heart Base; Swe)	FS (%)	EF (%)	EPSS (cm)
NORMAL PARAMETER	4.5-5.5	<2.7	1.3	<1.6	28-40	40-100	<0.6
PATIENT			1.2	1.17	44.6	77.6	0.36
CANINE CARDIAC PARAMETERS	HR (BPM)	AV VMAX (m/s)	PV MAX (m/s)	BODY WEIGHT (kg)	LA 2D short axis Base view (cm)	LVIDd Avg; 2D and m-mode short axis (cm)	LVIDs Avg; 2D and m-mode short axis (cm)
NORMAL PARAMETER	50-100	0.7-1.7	0.7-1.6				
PATIENT	80	1.55	1.0		3.5	3.0	

Cardiac Presentation

The echocardiogram in this patient demonstrated normal **left atrial** size based on 3 separate methods of LA evaluation. The cranial and caudal **mitral** valve leaflets presented normal linear structure, extension in systole, and union in diastole with normal kinesis. The **left ventricle** presented thicknesses with linear contour and was not dilated nor restricted. The **myocardium** presented normal echogenicity without subjective evidence of significant fibrotic or ischemic disease. **Contractility** of the ventricular walls was adequate and in normal range for this patient evidenced by the fractional shortening measurement and subjective evaluation of the different regions of the myocardium. The **left ventricular outflow** tract demonstrated normal laminar flow and subjective structural integrity. The **right atrium** and auricle revealed normal size, structure and content. No evidence of masses was noted. **Tricuspid** valvular assessment demonstrated adequate linear morphology and kinesis. The **right ventricle** was of normal size (1/3 diameter of LV), chordae structure, myocardial echogenicity and thickness. **Pulmonary outflow** tract assessment revealed normal valve structure, laminar flow, and diameter (approx. 1:1 pa/ao ratio). No visible **pericardial** or free pleura fluid was noted. The cranial **mediastinum and pericardial and extra-cardiac regions** were free of masses in the visible window.

Urinary System

The urinary bladder, trigone, cystourethral junction, and visible pelvic urethra to a depth of 3.0 cm exhibited normal thickness and tone. Anechoic urine was present in the lumen with no uroliths or sediment. The ureteral papillae were normal. The ureters were not visible which is normal. No evidence of inflammatory or neoplastic changes were noted.

Normal size and margination were present in the kidneys. A normal 1:3 cortex / medulla ratio was maintained. The medulla and cortices were uniform in texture with some increased echogenicity and loss of corticomedullary symmetry and definition expected for the age of the patient. No evidence of pelvic dilation was present. The left kidney measured 5.6 cm. The right kidney measured 6.0 cm.

INTERPRETED BY

R. McKenzie Daniel, DVM, DABVP (Canine and Feline)

IMAGING PERFORMED BY

Jessica Miller

HOSPITAL NAME

Marsh Animal Hospital

REFERRING VET

Dr. Milwicki

INVOICE

25388

DATE

9/14/21



PATIENT

The area of the aortic trifurcation was free of pathology.

Dakota Judge

Adrenal Glands

SPECIES

The adrenal glands were uniform in size and contour with a uniformly hypoechoic parenchyma. The left adrenal gland measured 2.4 cm length x 0.62 cm at the caudal pole. The right adrenal gland 2.3 cm length x 0.49 cm at the caudal pole.

Canine

Spleen

BREED

The spleen exhibited a finely textured and homogenous parenchyma which was hyperechoic to the liver and renal cortical parenchyma. The capsule was smooth and regular without apparent expansion. The splenic vasculature at the hilus was normal in volume with no evidence of congestion or thrombosis. Acute to chronic inflammatory, neoplastic, or benign parenchyma changes were not noted.

Husky

SEX

Liver

Spayed Female

The liver was subjectively normal in size, structure, and contour. The liver parenchyma was mildly nonuniform and hypoechoic to the spleen with a moderate coarse echotexture and subjective mild to benign parenchymal remodeling. The hepatic and portal vasculature were normal in appearance without signs of congestion. The gallbladder was non-distended in size with thin walls and primarily anechoic luminal content. The cystic and common bile ducts were normal.

AGE

12 Years

Gastrointestinal

WEIGHT

43 Pounds

The stomach exhibited generalized mild to moderate mural thickening with subjective decreased mural echogenicity and indistinct wall layering, more prominent in the area of the gastric antrum and pylorus. The stomach was primarily empty with mild luminal gas and minor retained fluid. No overt evidence of gastric foreign material. Pylorus wall measured up to 1.0 cm wall width, whereas gastric fundus measured 0.66 cm wall width. Mild regional perigastric reactive mesentery was present. No overt evidence of concurrent perigastric or intraabdominal lymphadenopathy.

INTERPRETED BY

R. McKenzie Daniel,
DVM, DABVP
(Canine and Feline)

The small intestine presented intact wall layering with 1:3 muscularis/mucosa ratio. The lumen of the small intestine was empty with no signs of ileus, obstruction or foreign material. Mild upper duodenal metabolic ileus was noted, exhibited by mild retained upper duodenal fluid. Duodenum wall measured 0.37 cm. Jejunum wall measured 0.33 cm.

IMAGING PERFORMED BY

Jessica Miller

Normal visible colon wall layers were present with apparent formed feces in lumen.

HOSPITAL NAME

Pancreas

Marsh Animal Hospital

The parenchyma of the left limb, body and right limb of the pancreas presented isoechoic to the adjacent omental fat. A normal curvilinear capsule contour of the pancreas was present. The visible pancreatic duct was normal. No signs of active inflammation or neoplastic disease was evident.

REFERRING VET

Dr. Milwicki

ULTRASONOGRAPHIC FINDINGS

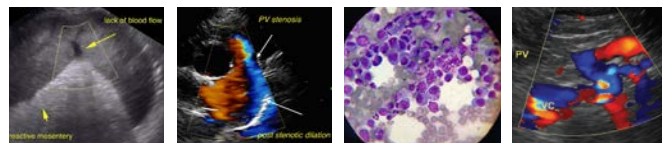
INVOICE

25388

- Normal echocardiogram
- Generalized thickened stomach, subjectively more prominent in the area of the gastric antrum/pylorus with decreased mural echogenicity and indistinct wall layering.
- Associated mild perigastric reactive mesentery
- Intact small bowel walls with mild upper duodenal metabolic ileus

DATE

9/14/21



PATIENT

Dakota Judge

SPECIES

Canine

BREED

Husky

SEX

Spayed Female

AGE

12 Years

WEIGHT

43 Pounds

INTERPRETATION OF THE FINDINGS & FURTHER RECOMMENDATIONS

The cause of the patient's clinical signs is associated with the upper gastrointestinal tract, specifically the stomach, and potentially upper duodenum. The appearance of the stomach and upper duodenum may suggest moderate to significant chronic gastritis/gastroduodenitis. However, given the patient's weight loss and appearance of the stomach, concern for infiltrative gastric mural process or neoplasia (although not definitive) is warranted.

Endoscopic upper gastrointestinal biopsies are recommended for further assessment and histopathology. Assessment of serum cobalamin and folate levels may be considered empirically. Some or all of the following protocol is suggested.

Helicobacter/Gastritis protocol

A clinical trial of **Zithromax (Dogs: 5-10 mg/kg p.o. q24h. May increase dosing interval to q48h after 3-5 days of treatment)**, **Metronidazole (10-20 mg/kg p.o. b.i.d.)**, **Pepcid (0.5-1 mg/kg s.i.d.)** and **Sucralfate (0.5-2 g/dog PO)** or **Omeprazole (1 mg/kg p.o. s.i.d.)** over the next 3 weeks along with a **novel-protein or hydrolyzed diet** with slurry feeding b.i.d./t.i.d. over the next 2-4 days and then increase to canned diet bid. Dry food should be avoided over the next 4 weeks. A recheck sonogram to assess GI improvement or progression would be ideal in 4 weeks.

INTERPRETED BY

R. McKenzie Daniel,
DVM, DABVP
(Canine and Feline)

IMAGING PERFORMED BY

Jessica Miller

HOSPITAL NAME

Marsh Animal Hospital

REFERRING VET

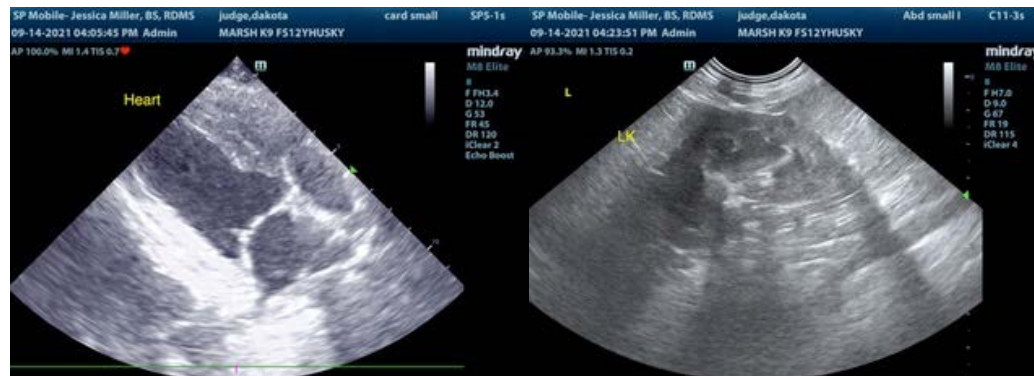
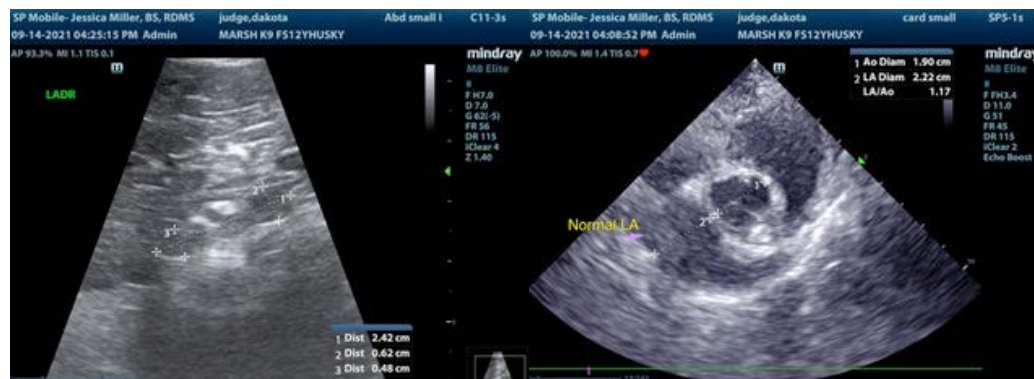Dr. Milwicki

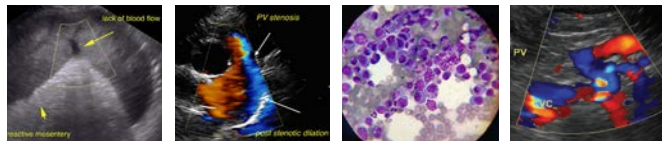
INVOICE

25388

DATE

9/14/21





PATIENT

Dakota Judge

SPECIES

Canine

BREED

Husky

SEX

Spayed Female

AGE

12 Years

WEIGHT

43 Pounds

INTERPRETED BY

R. McKenzie Daniel,
DVM, DABVP
(Canine and Feline)

IMAGING PERFORMED BY

Jessica Miller

HOSPITAL NAME

Marsh Animal Hospital

REFERRING VET

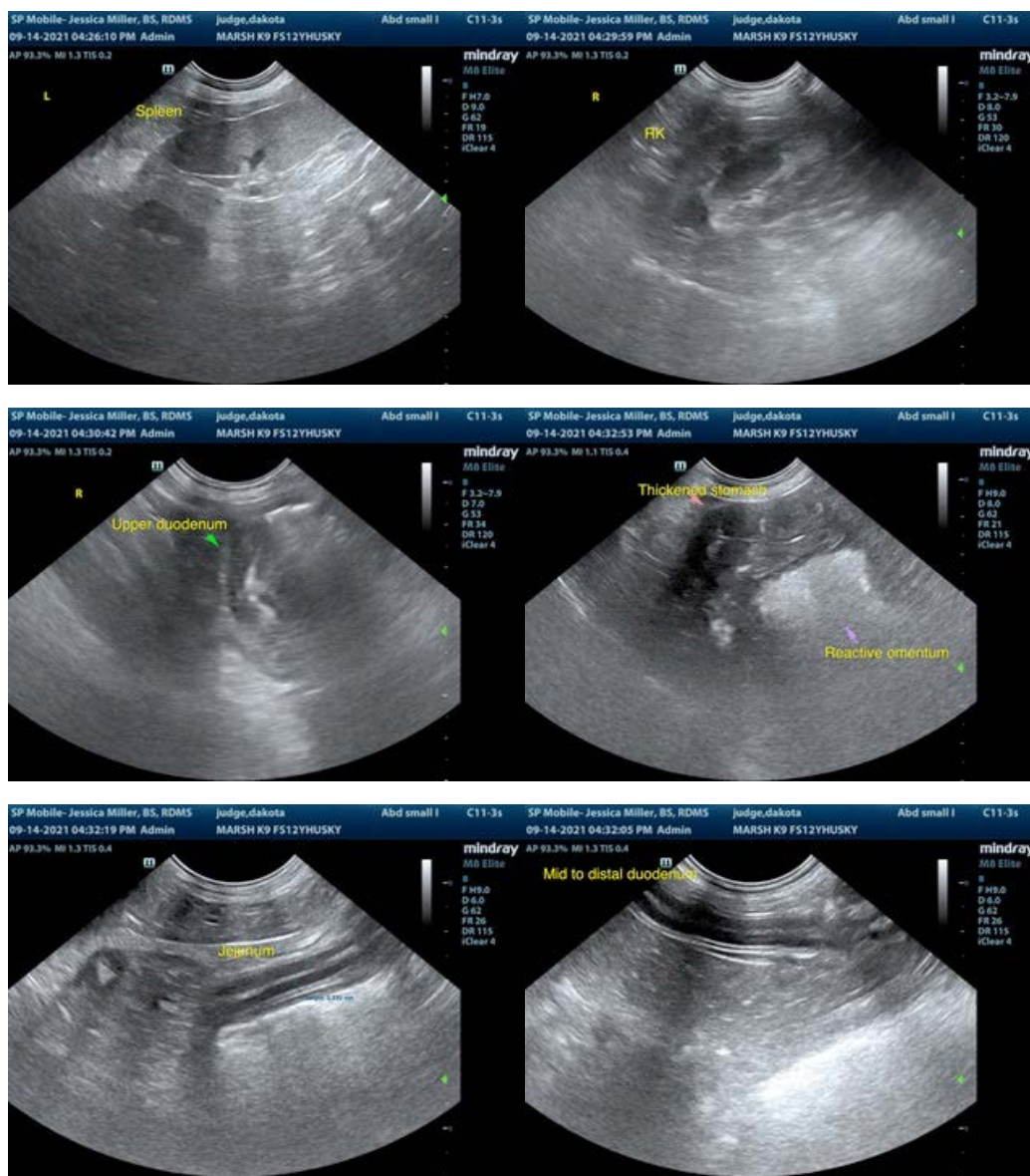
Dr. Milwicki

INVOICE

25388

DATE

9/14/21



The information and recommendations provided are based on the images presented by the referring veterinarian. No evaluation can be communicated regarding pathology that was not visible in the image/video clips provided.

Thank you for this referral. If the clinical or image interpretation does not parallel your findings or if I can be of any further assistance please contact me.

R. McKenzie Daniel, DVM, DABVP (Canine / Feline Practice)
info@SonoPath.com