



PATIENT PRESENTING CLINICAL SIGNS

Daisy Houk Grade 2/6 left side apical systolic heart murmur. No coughing, tires easy No arrhythmia, lung field quiet. pulse synchronous.
Abnormal PE/Chem/CBC/UA Results: No current BW

SPECIES ULTRASONOGRAPHIC EXAMINATION OF THE HEART

Canine

BREED

Dachshund X

SEX

Spayed Female

AGE

13 Years

WEIGHT

21 Pounds

CANINE CARDIAC PARAMETERS	MR VMAX (m/s)	TR VMAX (m/s)	LA/AO (Boon method)	LA/AO (Heart Base; Swe)	FS (%)	EF (%)	EPSS (cm)
NORMAL PARAMETER	4.5-5.5	<2.7	1.3	<1.6	28-40	40-100	<0.6
PATIENT	5.0	1.5	NM	1.67	44.8	79.6	0.25
CANINE CARDIAC PARAMETERS	HR (BPM)	AV VMAX (m/s)	PV MAX (m/s)	BODY WEIGHT (kg)	LA 2D short axis Base view (cm)	LVIDd Avg; 2D and m-mode short axis (cm)	LVIDs Avg; 2D and m-mode short axis (cm)
NORMAL PARAMETER	50-100	0.7-1.7	0.7-1.6				
PATIENT	110	1.0	0.8		2.9	2.9	

INTERPRETED BY

R. McKenzie Daniel, DVM, DABVP (Canine and Feline)

IMAGING PERFORMED BY

Kim Liedberg

HOSPITAL NAME

SVS Imaging

REFERRING VET

Dr. Bockmeier

INVOICE

25410

DATE

9/14/21

Cardiac Presentation

The echocardiogram for this patient presented mildly excessive **left atrial size** expressed both in the LA/AO and LA max measurements Chamber volumes and echogenicity were normal. The cranial and caudal **mitral** valve leaflets presented vegetative thickening consistent with endocardiosis. Doppler indicated mild eccentric mitral valve insufficiency. The **left ventricle** presented thicknesses with linear contour and was not dilated nor restricted. The **myocardium** presented normal echogenicity without subjective evidence of significant fibrotic or ischemic disease. **Contractility** of the ventricular walls was adequate and in normal range for this patient evidenced by the fractional shortening measurement and subjective evaluation of the different regions of the myocardium. The **left ventricular outflow** tract demonstrated normal laminar flow and subjective structural integrity. The **right atrium** and auricle revealed normal size, structure and content. No evidence of masses was noted or chamber overload. **Tricuspid** valvular assessment demonstrated adequate linear morphology. Doppler assessment of the tricuspid valve revealed mild insufficiency. The **right ventricle** was of normal size (1/3 diameter of LV), chordae structure, myocardial echogenicity and thickness. **Pulmonic** tract assessment revealed normal valve structure, laminar flow, and diameter (approx. 1:1 pa/ao ratio). No visible **pericardial** or free pleura fluid was noted. No echographically detectable evidence of infiltrative disease was visible. The cranial **mediastinum and pericardial regions** were free of masses in the visible window.

ULTRASONOGRAPHIC FINDINGS

- Compensated chronic mitral valve disease (ACVIM early B2)
- Mild tricuspid valve insufficiency – estimated pulmonary pressure gradient not consistent with clinical pulmonary hypertension.



PATIENT

Daisy Houk

SPECIES

Canine

BREED

Dachshund X

SEX

Spayed Female

AGE

13 Years

WEIGHT

21 Pounds

INTERPRETED BY

R. McKenzie Daniel,
DVM, DABVP
(Canine and Feline)

IMAGING PERFORMED BY

Kim Liedberg

HOSPITAL NAME

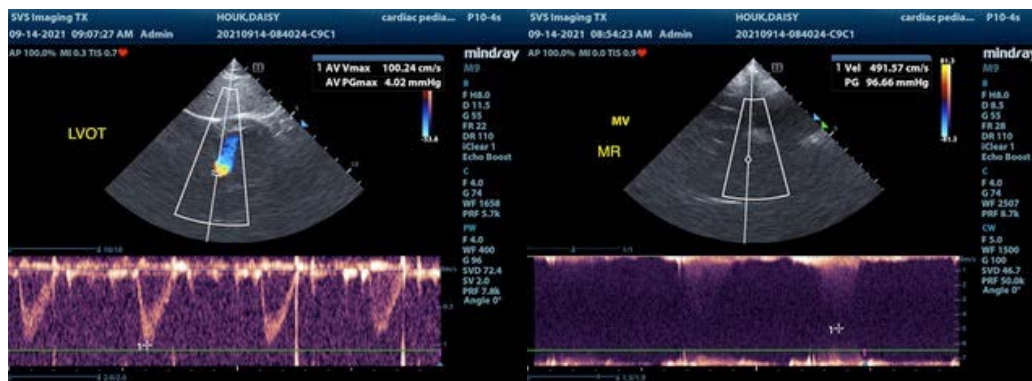
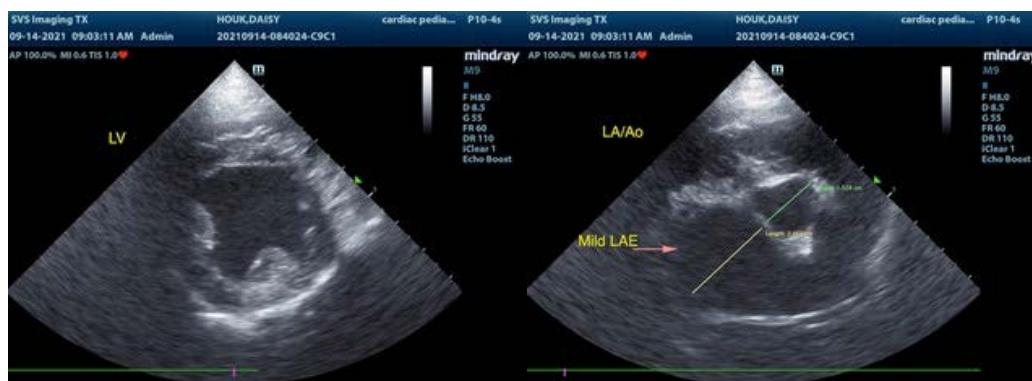SVS Imaging

REFERRING VET

Dr. Bockmeier

INTERPRETATION OF THE FINDINGS & FURTHER RECOMMENDATIONS

The cause of the murmur is most consistent with chronic degenerative valvular changes with secondary eccentric mitral valve insufficiency. The lack of left atrial enlargement indicates that the risk of future complication is relatively low, although prognosis is highly variable. No other clinical issues such as systolic dysfunction or clinical pulmonary hypertension noted. Given these findings, clinical signs secondary to heart disease are not anticipated. No overt indication for cardiac medications at this stage. Continued conservative monitoring with recheck echocardiogram recommended in 6 months, sooner if clinical signs consistent with heart disease (increased exercise intolerance, coughing, increased resting respiration rate, etc.) are noted.



The information and recommendations provided are based on the images presented by the referring veterinarian. No evaluation can be communicated regarding pathology that was not visible in the image/video clips provided.

Thank you for this referral. If the clinical or image interpretation does not parallel your findings or if I can be of any further assistance please contact me.

R. McKenzie Daniel, DVM, DABVP (Canine / Feline Practice)
info@SonoPath.com

INVOICE

25410

DATE

9/14/21