

PATIENT

Dusty Dryden

SPECIES

Canine

BREED

Lab

SEX

Neutered Male

AGE

7 years

WEIGHT

93 lbs.

INTERPRETED BY

R. McKenzie Daniel,
DVM, DABVP
(Canine and Feline)

IMAGING PERFORMED BY

Jenna Walsh

HOSPITAL NAME

Q Street AH

REFERRING VET

Dr. Bretschneider

INVOICE

12210

DATE

9/10/21

PRESENTING CLINICAL SIGNS

reduced appetite, weight loss, sporadic vomiting

Abnormal PE/Chem/CBC/UA Results: CBC = NSF, Platelets 63 (165-500 n) Chem = Alk Phos = 1159, ALT = 168 otherwise normal

Submitted thoracic radiographs revealed soft tissue opacity in the area of the cranial thorax / mediastinum.

ULTRASONOGRAPHIC EXAMINATION OF THE ABDOMEN

Urinary System

The urinary bladder, trigone, cystourethral junction, and visible pelvic urethra to a depth of 3.0 cm exhibited normal thickness and tone. Anechoic urine was present in the lumen with no uroliths or sediment. The ureteral papillae were normal. The ureters were not visible which is normal. No evidence of inflammatory or neoplastic changes was noted.

No overt pathology was noted in the area of the residual prostate.

Normal size and margination were present in the kidneys. A normal 1:3 cortex / medulla ratio and normal corticomedullary definition were maintained. The echogenicity of the cortex was similar to or slightly less than normal liver parenchyma while the medulla echogenicity was hypoechoic to the cortex with no evidence of pelvic dilation. The left kidney measured 7.4 cm in length. The right kidney measured 7.4 cm in length.

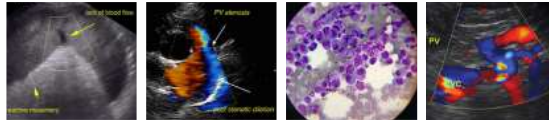
Adrenal Glands

The left adrenal gland was uniform in size and contour with a uniformly hypoechoic parenchyma. The left adrenal gland measured 0.76 cm width at the caudal pole and 0.64 cm width at the cranial pole.

A well-defined, hyperechoic nodule was present in the cranial pole of the right adrenal gland with mild associated symmetrical capsule expansion. The nodule did not exhibit signs of mineralization or vascular invasion. The nodule measured 1.0 cm x 0.67 cm. The right adrenal gland measured 0.75 cm width at the caudal pole and 1.2 cm width at the cranial pole.

Spleen

The spleen exhibited subjective mild enlargement with mild folding. The splenic folding is nonspecific. Primarily finely textured parenchyma which was hyperechoic to the liver and renal cortical parenchyma was present. Mild generalized parenchyma heterogeneity was present without evidence of nodular changes or distinct masses. The splenic vasculature at the hilus was normal in volume with no evidence of congestion or thrombosis. The parenchymal heterogeneity is likely consistent with benign changes such as extramedullary hematopoiesis or age-related remodeling with minor potential for inflammatory or neoplastic disease.



PATIENT

Liver/ Gallbladder

Dusty Dryden

The liver presented enlarged in size. The parenchyma of the liver was subjectively normal in echogenicity compared to the spleen and renal cortices. The liver parenchyma was uniform with a mildly coarse echotexture. The capsule of the liver was symmetrically rounded. Variable lobar swelling was present. The hepatic and portal vasculature were normal in appearance without signs of congestion. No distinct hepatic masses or nodules were noted. The gallbladder was non-distended in size with primarily anechoic luminal content. The cystic and common bile ducts were normal.

SPECIES

Canine

BREED

Lab

SEX

Neutered Male

Gastrointestinal

The stomach presented intact wall layering with a normal wall layer ratio. Minor retained anechoic pyloric fluid was present. The gastric body wall width measured 0.38 cm.

AGE

7 years

The small intestine presented intact wall layering with 1:3 muscularis/mucosa ratio. The lumen of the small intestine was empty with no signs of ileus, obstruction, or foreign material. The duodenum wall width measured 0.55 cm.

Normal visible colon wall layers were present with apparent formed feces in lumen.

WEIGHT

93 lbs.

Pancreas

The parenchyma of the left limb, body, and right limb of the pancreas presented isoechoic to the adjacent omental fat. A normal curvilinear capsule contour of the pancreas was present. The visible pancreatic duct was normal. No signs of active inflammation or neoplastic disease were evident.

INTERPRETED BY

R. McKenzie Daniel,
DVM, DABVP
(Canine and Feline)

Free Abdomen

Multifocal, mid to cranial abdominal mesenteric lymphadenopathy was present. The lymph nodes exhibited symmetrical to rounded margination with abnormal width: length ratio (>0.5). The enlarged lymph nodes were bordered by echogenic to reactive mesentery. An example of a mesenteric lymph node measured 2.6 cm x 2.0 cm width.

Focal, medial iliac lymph node was present. The lymph node was homogenous, mildly hypoechoic and smoothly margined. A normal width: length ratio was maintained (<0.5). Evidence of perilymphatic inflammation was evident. The lymph node measured 3.0 cm x 1.2 cm.

IMAGING PERFORMED BY

Jenna Walsh

HOSPITAL NAME

Q Street AH

A brief sonographic assessment of the heart and cranial thorax revealed subjectively normal cardiac structure and function. A moderately sized to lobulated hypoechoic mass was present in the cranial thorax and mediastinum, measuring approximately 8.0 x 7.0 cm.

REFERRING VET

Dr. Bretschneider

INVOICE

12210

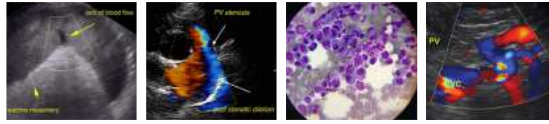
ULTRASONOGRAPHIC FINDINGS

Primary Findings

- Subjective splenomegaly with folding
- Hepatopathy with variable lobar swelling

DATE

9/10/21



PATIENT

Dusty Dryden

SPECIES

Canine

BREED

Lab

SEX

Neutered Male

AGE

7 years

WEIGHT

93 lbs.

INTERPRETED BY

R. McKenzie Daniel,
DVM, DABVP
(Canine and Feline)

IMAGING PERFORMED BY

Jenna Walsh

HOSPITAL NAME

Q Street AH

REFERRING VET

Dr. Bretschneider

INVOICE

12210

DATE

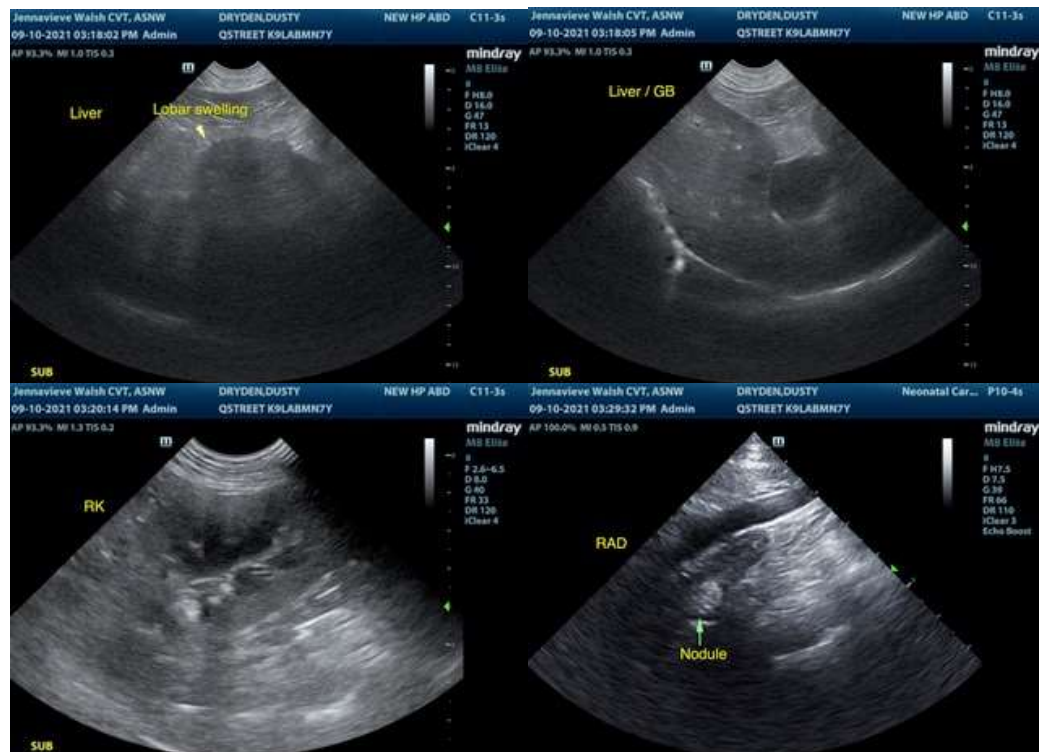
9/10/21

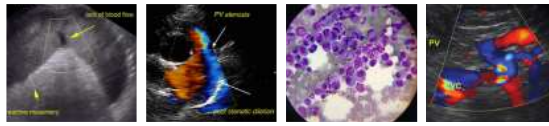
- Hypoechoic to swollen mesenteric and focal medial Iliac lymphadenopathy
- Nonspecific right adrenal nodule - suspect adenoma
- Cranial thoracic / mediastinal mass

INTERPRETATION OF THE FINDINGS & FURTHER RECOMMENDATIONS

Although cytology is needed for further clarification, this study is consistent with multicentric round cell neoplasia involving multiple intraabdominal lymph nodes, cranial thoracic / mediastinal mass and concern for hepatosplenic involvement. Primary concern for multicentric lymphoma vs. other round cell neoplasia.

Assuming normal clotting status, hepatosplenic, lymphatic, and cranial thoracic / mediastinal mass FNA is warranted for screening cytology and staging. Oncology consultation is recommended with potential for chemotherapeutic intervention. As-needed GI support is suggested.





PATIENT

Dusty Dryden

SPECIES

Canine

BREED

Lab

SEX

Neutered Male

AGE

7 years

WEIGHT

93 lbs.

INTERPRETED BY

R. McKenzie Daniel,
DVM, DABVP
(Canine and Feline)

IMAGING PERFORMED BY

Jenna Walsh

HOSPITAL NAME

Q Street AH

REFERRING VET

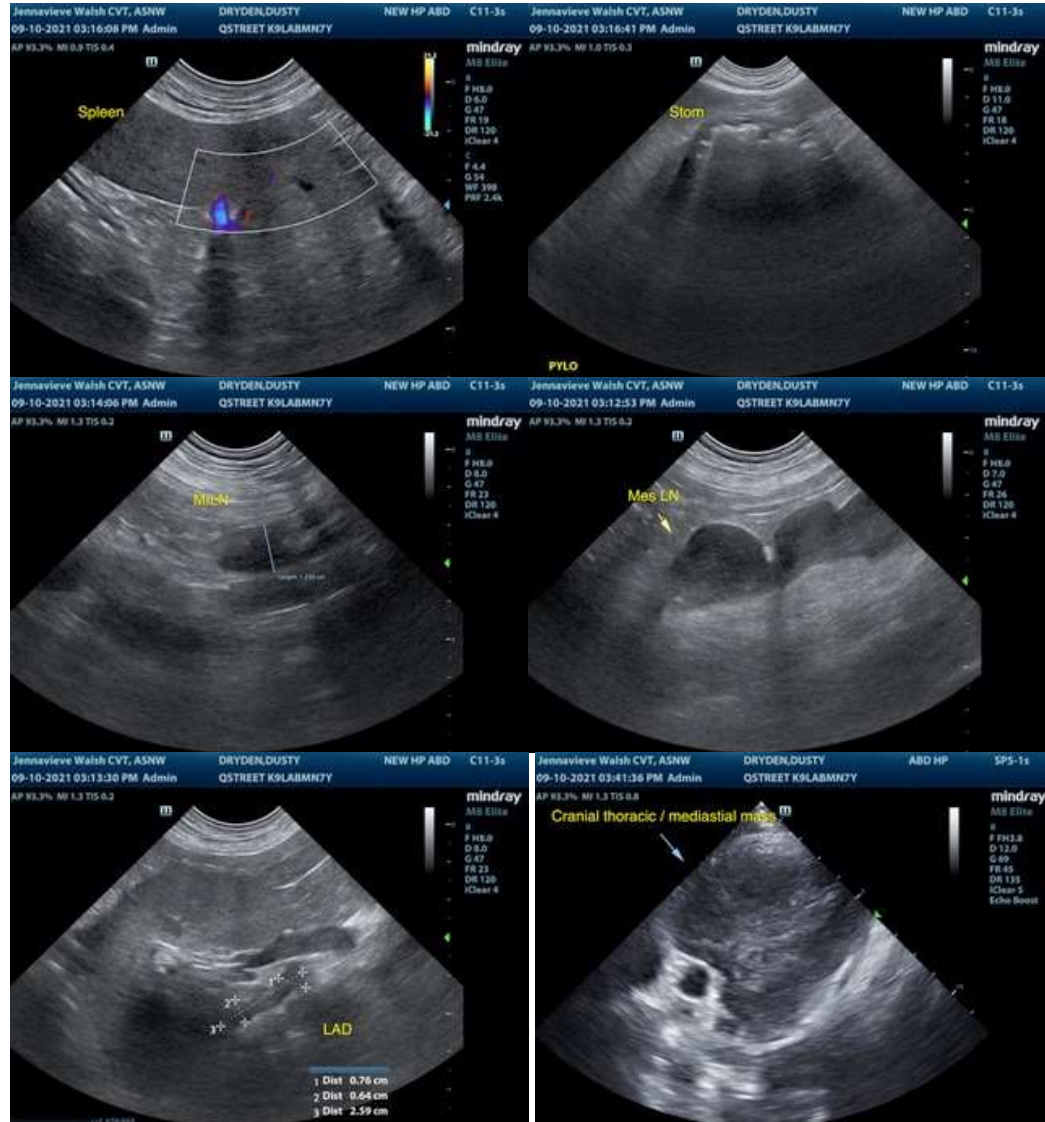
Dr. Bretschneider

INVOICE

12210

DATE

9/10/21



The information and recommendations provided are based on the images presented by the referring veterinarian. No evaluation can be communicated regarding pathology that was not visible in the image/video clips provided.

Thank you for this referral. If the clinical or image interpretation does not parallel your findings or if I can be of any further assistance please contact me.

R. McKenzie Daniel, DVM, DABVP (Canine / Feline Practice)
info@SonoPath.com