

**PATIENT**

Beethoven Norton

**SPECIES**

Canine

**BREED**

Chihuahua Mix

**SEX**

Neutered Male

**AGE**

11 years

**WEIGHT**

14.7 lbs

**INTERPRETED BY**

R. McKenzie Daniel,  
DVM, DABVP  
(Canine and Feline)

**IMAGING PERFORMED BY**

Rachel Runnells, RVT

**HOSPITAL NAME**  
SVS Imaging Kansas  
City

**REFERRING VET**

Dr. Caitlin Klepper

**INVOICE**

13008

**DATE**

9/13/21

**PRESENTING CLINICAL SIGNS**

This patient was diagnosed with Cushing's in September 2019 and has been on Vetoryl 5mg 2 in am and 1 in pm. Presented on 9/9/21 for complaints of bloated abdomen that had resolved as well as lethargy and inappetence.

Abnormal PE/Chem/CBC/UA Results: Area of alopecia and black pigmented skin on the dorsal cranial tail surface Tense abdominal palpation but does not seem painful New anemia and worsening of liver values. CBC: RBC 5.06 (L), HGB 10.5 (L), HCT 32.91% (L), PLT 526,000 (H). Rest WNL.  
Chem17/Electrolytes: BUN 36 (H) with normal creat, ALP 1967 (H), GGT 13 (H), CI 100 (L) Rest WNL.  
U/A free catch: Protein: ++, pH 6.0, Ascorbic Acid: 40 Specific Gravity: 1.005. Rest WNL.

**ULTRASONOGRAPHIC EXAMINATION OF THE ABDOMEN**

**Urinary System**

The urinary bladder, trigone, cystourethral junction, and visible pelvic urethra to a depth of 3.0 cm exhibited normal thickness and tone. Anechoic urine was present in the lumen with no uroliths or sediment. The ureteral papillae were normal. The ureters were not visible which is normal. No evidence of inflammatory or neoplastic changes was noted.

The residual prostate was symmetrically normal in size with uniform parenchyma and slight coarse echotexture measuring 0.95 cm in diameter.

The area of the aortic trifurcation was free of pathology.

Normal size and margination were present in the kidneys. A normal 1:3 cortex / medulla ratio was maintained. The medulla and cortices were uniform in texture with some moderate increased echogenicity and loss of corticomedullary symmetry and definition expected for the age of the patient. No evidence of pelvic dilation was present. The left kidney measured 4.8 cm in length. The right kidney measured 4.6 cm in length.

**Adrenal Glands**

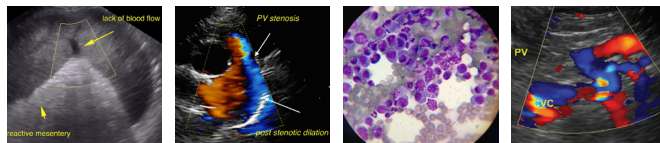
Bilateral symmetrical adrenal gland enlargement with uniformly hypoechoic parenchyma was present. The left adrenal gland measured 0.65 cm width at the caudal pole and 0.73 cm width at the cranial pole. The right adrenal gland measured 0.98 cm width at the cranial pole and 0.85 cm width at the caudal pole.

**Spleen**

The spleen exhibited primarily finely textured parenchyma which was hyperechoic to the liver and renal cortical parenchyma. Mild generalized parenchyma heterogeneity was present without evidence of nodular changes. The capsule was smooth and regular without apparent expansion. The splenic vasculature at the hilus was normal in volume with no evidence of congestion or thrombosis. The parenchymal heterogeneity is likely consistent with benign changes such as extramedullary hematopoiesis or age-related remodeling with minor potential for inflammatory or neoplastic disease.

**Liver/ Gallbladder**

The liver was exhibiting moderate generalized enlargement. The liver parenchyma was mildly nonuniform and hypoechoic to the spleen with a moderate coarse echotexture and subjective mild to benign parenchymal remodeling. The hepatic and portal vasculature were normal in appearance without signs of congestion. A non-homogenous to mixed echogenic mass occupying the right medial to lateral liver lobes. The mass appeared to mildly distort the ventral and cranial hepatic contour. The mass measured approximately 7.5 cm x 7.0 cm. The gallbladder was displaced ventral medially owing to the liver mass



**PATIENT**

Beethoven Norton

with normal overall size containing moderate inspissated yet non-organized echogenic luminal debris. The common bile duct was normal. Mild regional perihepatic reactive mesentery was present. No effusion or overt evidence of lymphadenopathy.

**SPECIES**

Canine

**Gastrointestinal**

The stomach presented intact wall layering with a normal wall layer ratio. The lumen of the stomach was empty with no signs of ileus, obstruction, or foreign material.

**BREED**

Chihuahua Mix

The small intestine presented intact wall layering with 1:3 muscularis/mucosa ratio. The lumen of the small intestine was empty with no signs of ileus, obstruction, or foreign material.

**SEX**

Neutered Male

Normal visible colon wall layers were present with apparent formed feces in lumen.

**AGE**

11 years

**Pancreas**

The pancreas was normal in size and contour with isoechoic to heterogeneous parenchyma compared to adjacent omentum. No signs of active inflammation or neoplasia.

**WEIGHT**

14.7 lbs

**Free Abdomen**

No overt lymphadenopathy or peritoneal effusion was present.

**ULTRASONOGRAPHIC FINDINGS**

- Chronic hepatopathy with right medial to lateral non-homogenous mass
- Displaced gallbladder with moderate inspissated luminal debris
- Bilateral chronic renal changes
- Bilateral prominent adrenal glands- consistent with PDH
- Heterogeneous pancreas- age-related pancreatic changes likely, minor potential for low-grade inflammation

**INTERPRETED BY**

R. McKenzie Daniel,  
DVM, DABVP  
(Canine and Feline)

**INTERPRETATION OF THE FINDINGS & FURTHER RECOMMENDATIONS**

Assuming normal clotting status, ultrasound guided FNA of the liver mass warranted for screening cytology. Neoplasia is favored, although not definitive with hyperplasia, granuloma, hematopoiesis considered less likely differential diagnosis. Recheck ACTH stimulation test may be considered, if not recently done. Further renal staging to include urine C/S and protein: creatinine ratio on sterile urine sample may be considered.

**IMAGING PERFORMED BY**

Rachel Runnells, RVT

**HOSPITAL NAME**  
SVS Imaging Kansas  
City

**REFERRING VET**

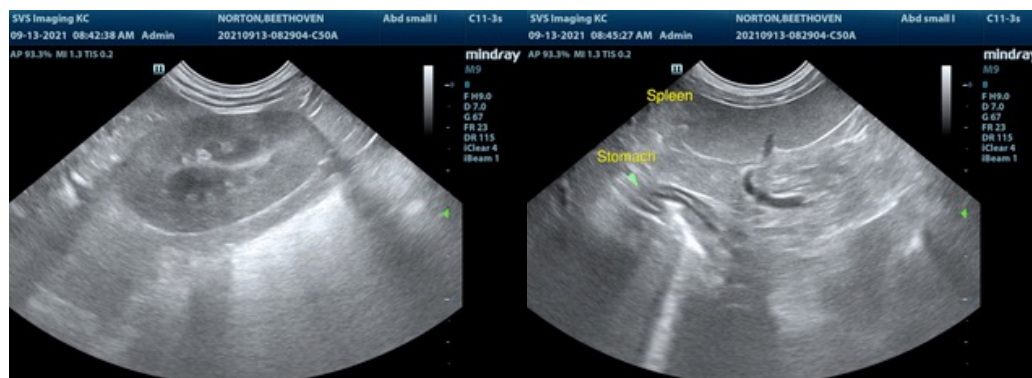
Dr. Caitlin Klepper

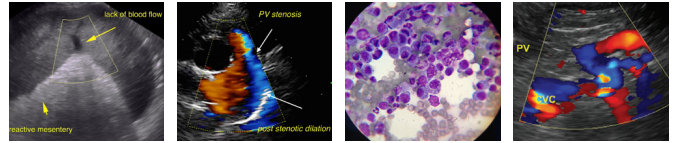
**INVOICE**

13008

**DATE**

9/13/21





**PATIENT**

Beethoven Norton

**SPECIES**

Canine

**BREED**

Chihuahua Mix

**SEX**

Neutered Male

**AGE**

11 years

**WEIGHT**

14.7 lbs

**INTERPRETED BY**

R. McKenzie Daniel,  
DVM, DABVP  
(Canine and Feline)

**IMAGING PERFORMED BY**

Rachel Runnells, RVT

**HOSPITAL NAME**

SVS Imaging Kansas  
City

**REFERRING VET**

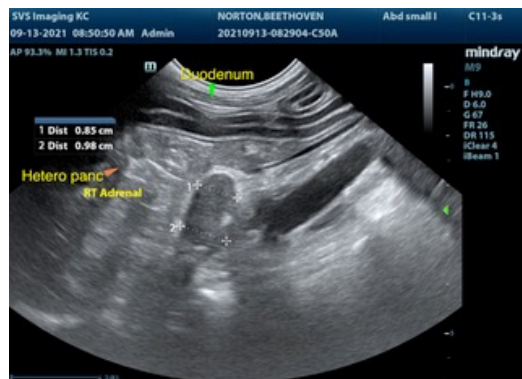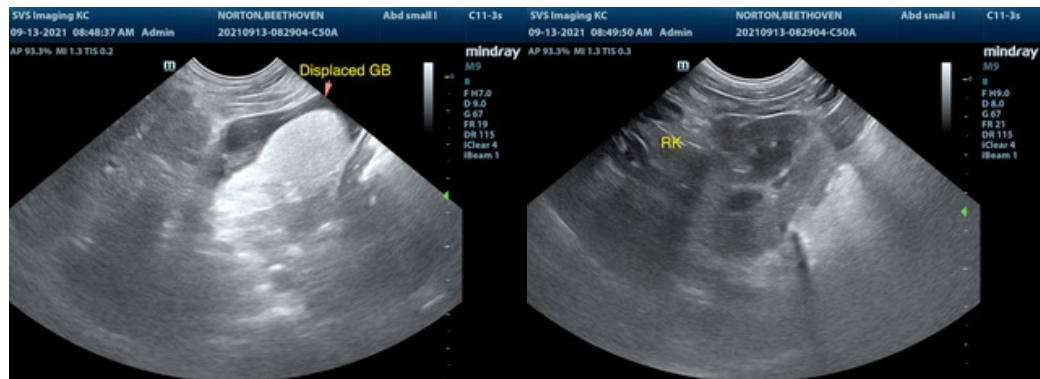
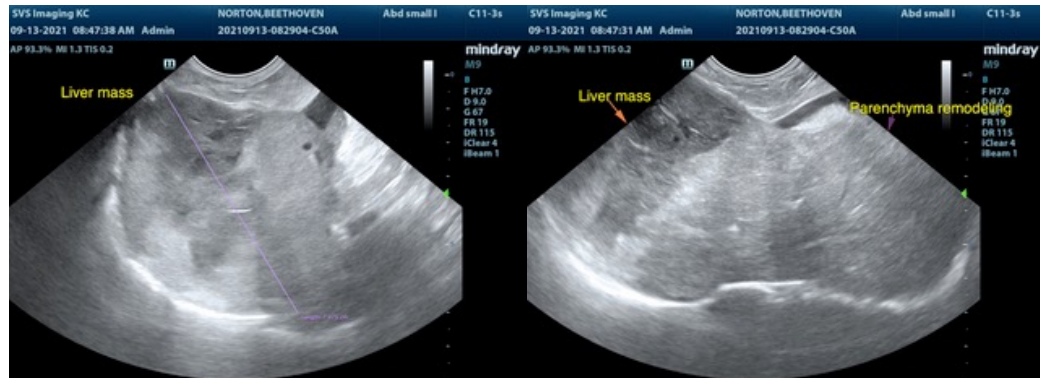
Dr. Caitlin Klepper

**INVOICE**

13008

**DATE**

9/13/21



The information and recommendations provided are based on the images presented by the referring veterinarian. No evaluation can be communicated regarding pathology that was not visible in the image/video clips provided.

Thank you for this referral. If the clinical or image interpretation does not parallel your findings or if I can be of any further assistance please contact me.

**R. McKenzie Daniel, DVM, DABVP (Canine / Feline Practice)**  
info@SonoPath.com