

**PATIENT PRESENTING CLINICAL SIGNS**

Flue Lebeau Flue has a golf-ball sized mass at the groin area. Would like to check if the mass is connected to the body wall for potential surgical removal and to check for any abdominal masses.

**SPECIES ULTRASONOGRAPHIC EXAMINATION OF THE ABDOMEN**

Feline **Urinary System**

**BREED** The urinary bladder, trigone, cystourethral junction, and visible pelvic urethra to a depth of 2.0 cm exhibited normal thickness and tone. Anechoic urine was present in the lumen with no uroliths or sediment. The ureteral papillae were normal. The ureters were not visible which is normal. No evidence of inflammatory or neoplastic changes were noted.

DSH

**SEX** Normal size and margination were present in the kidneys. A normal 1:3 cortex / medulla ratio was maintained. The medulla and cortices were uniform in texture with some increased echogenicity and loss of corticomedullary symmetry and definition expected for the age of the patient. No evidence of pelvic dilation was present. The left kidney measured 3.4 cm. The right kidney measured 3.7 cm.

Spayed Female

**AGE** **Adrenal Glands**

15 Years The adrenal glands were uniform in size and contour with a uniformly hypoechoic parenchyma. The left adrenal gland measured 0.42 cm in width. The right adrenal gland measured 0.43 cm in width.

**WEIGHT** **Spleen**

8.52 Pounds The spleen exhibited a finely textured and homogenous parenchyma which was hyperechoic to the liver and renal cortical parenchyma. The capsule was smooth and regular without apparent expansion. The splenic vasculature at the hilus was normal in volume with no evidence of congestion or thrombosis. Acute to chronic inflammatory, neoplastic, or benign parenchyma changes were not noted.

**INTERPRETED BY**

R. McKenzie Daniel, DVM, DABVP (Canine and Feline)

**IMAGING PERFORMED BY**

Pamela Harrigan, RDCS

**HOSPITAL NAME**

Airport AH

**REFERRING VET**

Dr. Asha Gudluru

**INVOICE**

41217

**DATE**

9/11/22

**Liver**

The liver was subjectively normal in size, structure, and contour. The liver parenchyma was uniform and hypoechoic to the spleen with a mild coarse echotexture. A solitary, discrete, isoechoic to subtly hypoechoic intraparenchymal nodule noted in the left liver, measuring 1.0 cm diameter. The hepatic and portal vasculature were normal in appearance without signs of congestion. The gallbladder was non-distended in size with thin walls and primarily anechoic luminal content. The cystic and common bile ducts were normal.

**Gastrointestinal**

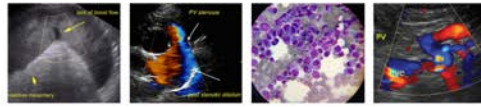
The stomach presented intact wall layering with a normal wall layer ratio. The lumen of the stomach was empty with no signs of ileus, obstruction or foreign material. Gastric body wall measured 0.24 cm.

The small intestine presented intact wall layering with segmental to generalized propensity for intact yet mildly prominent jejunal wall layering. Duodenum wall measured 0.25 cm. Jejunum wall measured up to 0.27 cm. No evidence of pathology at the level of the ileocolic junction, measuring 0.34 cm wall width.

Normal visible colon wall layers were present with apparent formed feces in lumen.

**Pancreas**

The parenchyma of the left limb, body and right limb of the pancreas presented isoechoic to the adjacent omental fat. A normal curvilinear capsule contour of the pancreas was present. The visible pancreatic duct was normal. No signs of active inflammation or neoplastic disease was evident.



**PATIENT** *Free Abdomen*

Flue Lebeau  
 A homogeneous mass was present in the inguinal area, which appeared to extend to the level of the inguinal body wall, yet did not overtly appear to originate from the abdominal cavity or compromise the associated inguinal wall, measuring approximately 5.0 cm x 2.6 cm. No evidence of mineralization, cavitation, cystic changes or peripheral mass free fluid.

**SPECIES**

Feline  
 No omental masses, lymphadenopathy, or peritoneal free fluid.

**BREED**

DSH

**SEX**

Spayed Female

**AGE**

15 Years

**WEIGHT**

8.52 Pounds

**ULTRASONOGRAPHIC FINDINGS**

- Homogeneous inguinal mass – sonographically consistent with fat echogenicity.
- Intact yet segmental to generalized prominent jejunal walls
- Minor chronic renal changes
- Non-specific, discrete, subjectively benign hepatic nodule

**INTERPRETATION OF THE FINDINGS & FURTHER RECOMMENDATIONS**

Sonographically, the inguinal mass is consistent with fat echogenicity and suggestive of lipoma. Correlation with ultrasound guided FNA of the mass for cytology could be considered. The mass appeared to extend to the level of the associated body wall yet did not appear to compromise or invade the body wall. Potential adherence to the body wall cannot be definitively excluded.

The small intestine, specifically the jejunum exhibited mildly prominent walls with potential for patient variant, although emerging inflammatory enteropathy such as IBD or less likely infiltrative neoplasia is possible. Given that there are no reported gastrointestinal signs, continued monitoring for the development of gastrointestinal signs and/or weight loss is recommended.

**INTERPRETED BY**

R. McKenzie Daniel, DVM,  
 DABVP (Canine and Feline)

**IMAGING PERFORMED BY**

Pamela Harrigan, RDCS

**HOSPITAL NAME**

Airport AH

**REFERRING VET**

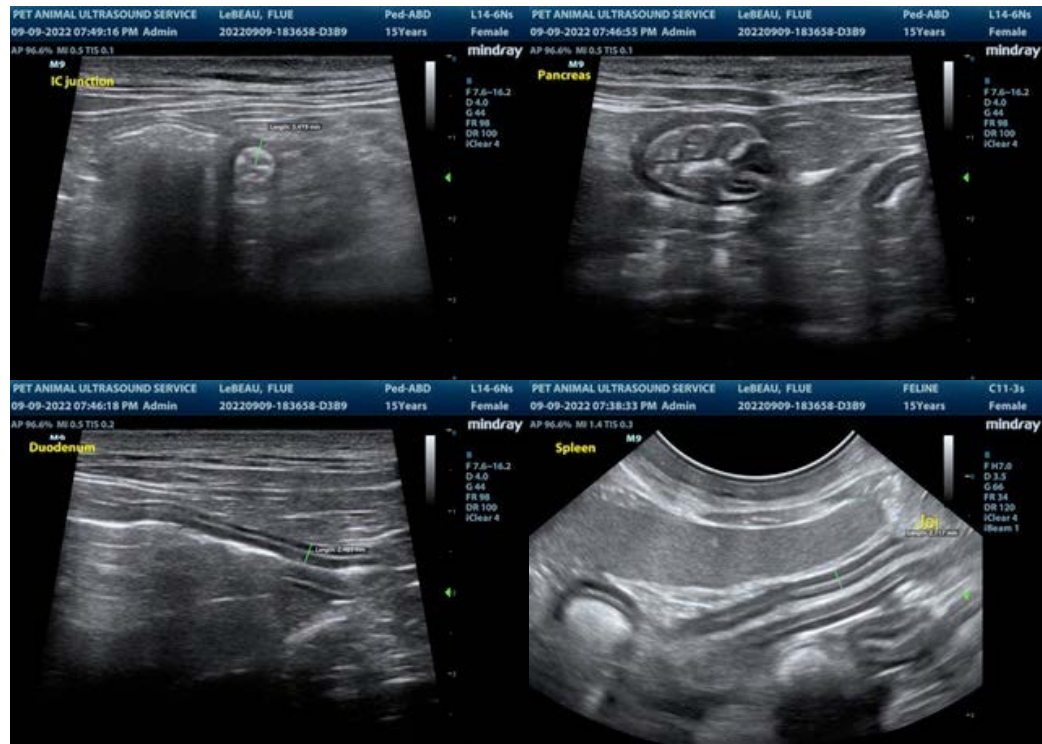Dr. Asha Gudluru

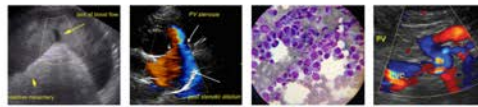
**INVOICE**

41217

**DATE**

9/11/22





**PATIENT**

Flue Lebeau

**SPECIES**

Feline

**BREED**

DSH

**SEX**

Spayed Female

**AGE**

15 Years

**WEIGHT**

8.52 Pounds

**INTERPRETED BY**

R. McKenzie Daniel, DVM,  
 DABVP (Canine and Feline)

**IMAGING PERFORMED BY**

Pamela Harrigan, RDCS

**HOSPITAL NAME**

Airport AH

**REFERRING VET**

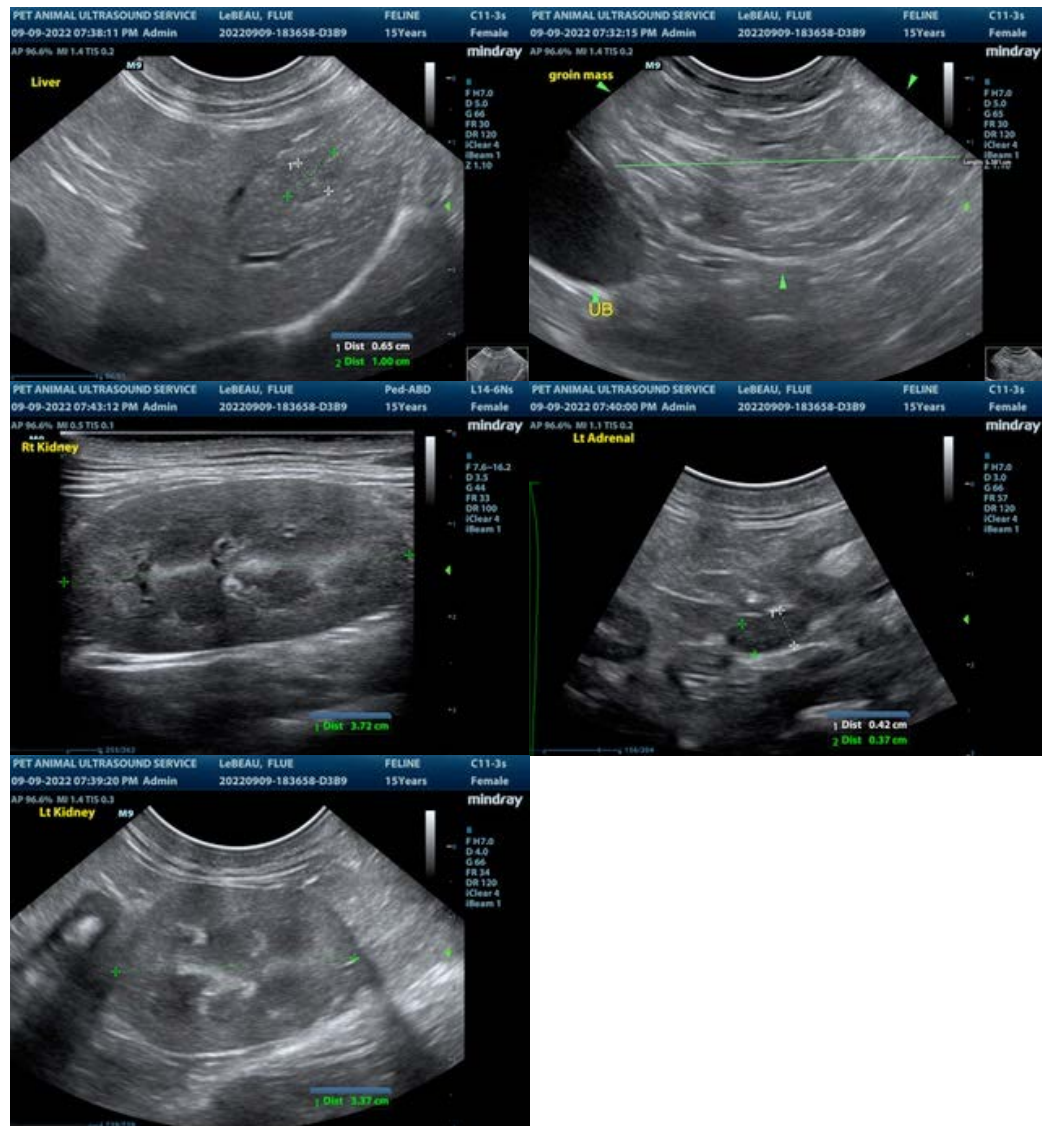
Dr. Asha Gudluru

**INVOICE**

41217

**DATE**

9/11/22



The information and recommendations provided are based on the images presented by the referring veterinarian. No evaluation can be communicated regarding pathology that was not visible in the image/video clips provided.

Thank you for this referral. If the clinical or image interpretation does not parallel your findings or if I can be of any further assistance please contact me.

**R. McKenzie Daniel, DVM, DABVP (Canine / Feline Practice)**  
 info@SonoPath.com