



## PATIENT PRESENTING CLINICAL SIGNS

Daisy Hines

History: Acute episode of labored breathing today, but abnormal breathing per O since yesterday which has worsened. Presented NOT dyspneic or hypoxic to us today however wheezing notated on exhale bilaterally, and tracheal palpation was normal. No murmur was noted.

## SPECIES

Canine

Abnormal PE/Chem/CBC/UA Results: See attached radiographs - abnormal opacity in L cranial med region. 4DX = 4 Neg; no other lab work performed at this time. ECG screening = normal with slight electrical axis deviation presumed to be normal variation

## BREED

Chinese Pug

## ULTRASONOGRAPHIC EXAMINATION OF THE HEART

## SEX

Spayed Female

## AGE

5 Years 9 Months

## WEIGHT

21.4 Pounds

## INTERPRETED BY

R. McKenzie Daniel,  
DVM, DABVP  
(Canine and Feline)

## IMAGING PERFORMED BY

Amanda Crook- SDEP  
Certified Clinical  
Sonographer

## HOSPITAL NAME

River's Edge PMC

## REFERRING VET

Dr. Julie Bernier

## INVOICE

17123

## DATE

9/1/22

CANINE CARDIAC PARAMETERS	MR VMAX (m/s)	TR VMAX (m/s)	LA/AO (Boon method)	LA/AO (Heart Base; Swe)	FS (%)	EF (%)	EPSS (cm)
NORMAL PARAMETER	4.5-5.5	<2.7	1.3	<1.3	28-40	40-100	<0.6
PATIENT	--	--	NM	1.28	53.9	87.2	0.15
CANINE CARDIAC PARAMETERS	HR (BPM)	AV VMAX (m/s)	PV MAX (m/s)	BODY WEIGHT (kg)	LA 2D short axis Base view (cm)	LVIDd Avg; 2D and m-mode short axis (cm)	LVIDs Avg; 2D and m-mode short axis (cm)
NORMAL PARAMETER	50-100	0.7-1.7	0.7-1.6				
PATIENT	NM	1.6	0.85	--	1.9	1.83	--

## Cardiac Presentation

The echocardiogram in this patient demonstrated normal **left atrial** size based on 3 separate methods of LA evaluation. The cranial and caudal **mitral** valve leaflets presented normal linear structure, extension in systole, and union in diastole with normal kinesis. The **left ventricle** presented thicknesses with linear contour and was not dilated nor restricted. The **myocardium** presented normal echogenicity without subjective evidence of significant fibrotic or ischemic disease.

**Contractility** of the ventricular walls was adequate and in normal range for this patient evidenced by the fractional shortening measurement and subjective evaluation of the different regions of the myocardium. The **left ventricular outflow** tract demonstrated normal laminar flow and subjective structural integrity. The **right atrium** and auricle revealed normal size, structure and content. No evidence of masses was noted. **Tricuspid** valvular assessment demonstrated adequate linear morphology and kinesis. The **right ventricle** was of normal size (1/3 diameter of LV), chordae structure, myocardial echogenicity and thickness. **Pulmonary outflow** tract assessment revealed normal valve structure, laminar flow, and diameter (approx. 1:1 pa/ao ratio). No visible **pericardial** or free pleura fluid was noted. The cranial **mediastinum, pericardial and extra-cardiac regions, including the area of the left cranial thorax and pulmonary parenchyma** were free of masses in the visible window.

## ULTRASONOGRAPHIC FINDINGS



**PATIENT**

- Normal echocardiogram

Daisy Hines

**INTERPRETATION OF THE FINDINGS & FURTHER RECOMMENDATIONS**

**SPECIES**

Canine

**BREED**

Chinese Pug

**SEX**

Spayed Female

No evidence of structural or functional cardiomyopathy, including no evidence of clinical issues, such as left or right heart chamber enlargement, LV systolic dysfunction or evidence of clinical pulmonary hypertension, which may indicate cardiogenic component to the patients respiratory abnormalities. The normal cardiac presentation indicates that the abnormal to labored breathing episodes in this patient are most likely secondary to primary upper or lower airway disease. Unfortunately, a definitive lesion in the area of the left cranial thorax was not visible. This is likely secondary to aerated lung surrounding a potential lesion in the left cranial thorax. Likewise, more diffuse primary lower airways disease could be present.

Further assessment may include lower airway sampling, such as BAL or TTW. As needed respiratory support with radiographic monitoring of the suspicious possible lesion in the left cranial thorax with potential for thoracic CT for further assessment if clinically indicated. No indication for cardiac medications.

**AGE**

5 Years 9 Months

**WEIGHT**

21.4 Pounds

**INTERPRETED BY**

R. McKenzie Daniel,  
DVM, DABVP  
(Canine and Feline)

**IMAGING PERFORMED BY**

Amanda Crook- SDEP  
Certified Clinical  
Sonographer

**HOSPITAL NAME**

River's Edge PMC

**REFERRING VET**

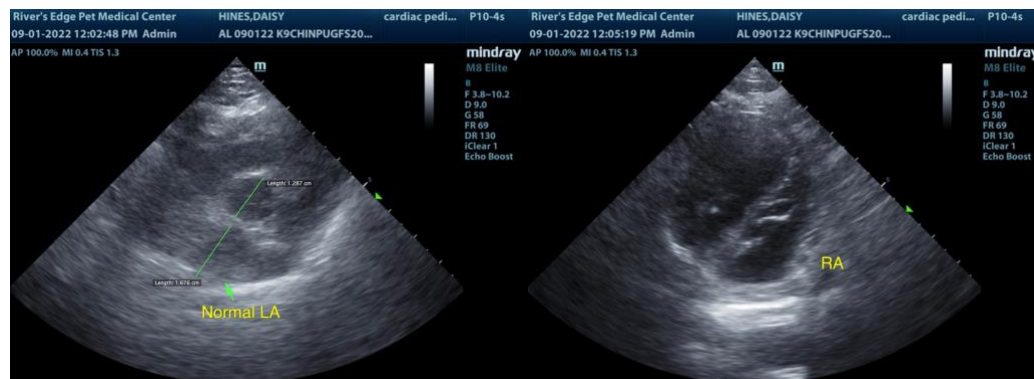
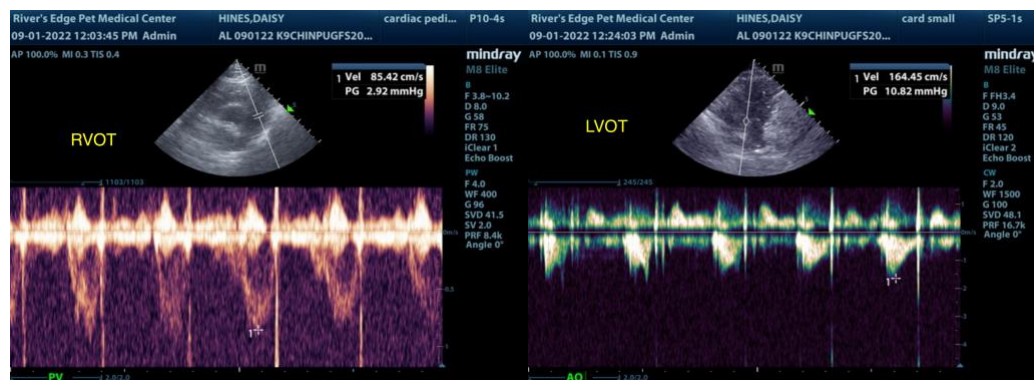
Dr. Julie Bernier

**INVOICE**

17123

**DATE**

9/1/22





**PATIENT**

Daisy Hines

**SPECIES**

Canine

**BREED**

Chinese Pug

**SEX**

Spayed Female

**AGE**

5 Years 9 Months

**WEIGHT**

21.4 Pounds

**INTERPRETED BY**

R. McKenzie Daniel,  
DVM, DABVP  
(Canine and Feline)

**IMAGING  
PERFORMED BY**

Amanda Crook - SDEP  
Certified Clinical  
Sonographer

**HOSPITAL NAME**

River's Edge PMC

**REFERRING VET**

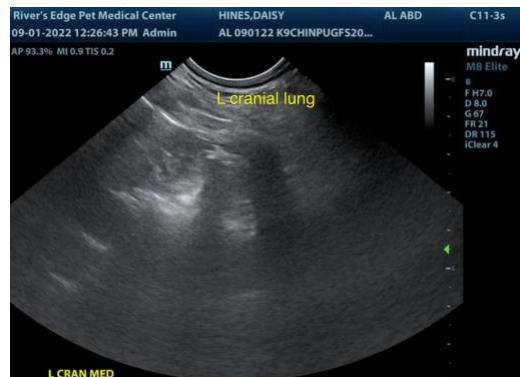
Dr. Julie Bernier

**INVOICE**

17123

**DATE**

9/1/22



The information and recommendations provided are based on the images presented by the referring veterinarian. No evaluation can be communicated regarding pathology that was not visible in the image/video clips provided.

Thank you for this referral. If the clinical or image interpretation does not parallel your findings or if I can be of any further assistance please contact me.

**R. McKenzie Daniel, DVM, DABVP (Canine / Feline Practice)**  
info@SonoPath.com