



**PATIENT PRESENTING CLINICAL SIGNS**

Joey Noyes History: Anorexia, concern for abdominal mass, PD, ataxia  
 Medication: Mirtazapine, B12

**SPECIES**

Feline

CBC - Hct 11.5, WBC 1.5 w/neutropenia and lymphopenia. Chem - Calcium 7.5, Glob 13.7, Alb 1.7, unremarkable liver enzymes, Amylase 7969, FELV/FIV neg.

**ULTRASONOGRAPHIC EXAMINATION OF THE ABDOMEN**

**BREED**

Domestic Shorthair

**Urinary System**

The urinary bladder, trigone, cystourethral junction, and visible pelvic urethra to a depth of 2.0 cm exhibited normal thickness and tone. Primarily anechoic urine was present in the lumen. Echogenic to mineralized dependent to non-dependent sediment was present without evidence of calculus formation. The ureteral papillae were normal. The ureters were not visible which is normal. No evidence of inflammatory or neoplastic mural changes were noted.

**SEX**

Neutered Male

Normal size and margination were present in the kidneys. A normal 1:3 cortex / medulla ratio was maintained. The medulla and cortices were uniform in texture with some increased echogenicity and loss of corticomedullary symmetry and definition expected for the age of the patient. No evidence of pelvic dilation was present. The left kidney measured 4.0 cm. The right kidney measured 3.8 cm.

**AGE**

11 years

The area of the aortic trifurcation was free of pathology.

**WEIGHT**

10.9 Pounds

**Adrenal Glands**

The adrenal glands were uniform in size and contour with a uniformly hypoechoic parenchyma. The left adrenal gland measured 0.29 cm in width. The right adrenal gland measured 0.28 cm in width.

**INTERPRETED BY**

R. McKenzie Daniel,  
 DVM, DABVP  
 (Canine and Feline)

**Spleen**

The spleen exhibited generalized subtle decreased splenic parenchyma echogenicity with asymmetrical lateral and primarily medial capsule contour. Mild generalized parenchyma heterogeneity was present without evidence of nodular changes. The splenic vasculature at the hilus was normal in volume with no evidence of congestion or thrombosis. The parenchymal heterogeneity is likely consistent with benign changes such as extramedullary hematopoiesis or age related remodeling with minor potential for inflammatory or neoplastic disease. The spleen measured 0.9 cm in width.

**IMAGING PERFORMED BY**

Rebekah Jakum, CVT  
 ARDMS/RVT

**Liver**

The liver exhibited generalized enlargement with echogenic to non-uniform parenchyma. The gallbladder was non distended in size with mild, echogenic, nonmineralized biliary sludge. The cystic duct and common bile ducts were normal without evidence of dilation.

**HOSPITAL NAME**

Community VP

**REFERRING VET**

Dr. Hulshizer

**Gastrointestinal**

The stomach presented intact wall layering with a normal wall layer ratio. The lumen of the stomach was empty with no signs of ileus, obstruction or foreign material.

**INVOICE**

25137

The intestinal walls demonstrated intact wall layering with subjective propensity for mildly prominent segmental duodenojejunal muscularis layer. The mucosa exhibited mild decreased echogenicity with occasional mucosal speckling. A segmental to diffuse ileus pattern consisting of mild fluid accumulation in the intestinal lumen was present without obstruction or foreign material. Duodenum wall measured 0.30 cm. Jejunum wall measured 0.28 cm.

**DATE**

9.1.2021

Normal visible colon wall layers were present with apparent formed feces in lumen.



**PATIENT** *Pancreas*

Joey Noyes The pancreas was normal in size. The left limb, right limb, and base of the pancreas presented hypoechoic to heterogeneous echogenicity compared to adjacent omental fat. Mild asymmetrical capsule margination was present with mild variable parenchymal swelling and mild peripancreatic inflammation. No overt evidence of neoplasia.

**SPECIES**

Feline *Free Abdomen*

**BREED**

Generalized mildly non-uniform increased omental echogenicity was noted. Mild subjectively cellular peritoneal free fluid was present.

Domestic Shorthair

Intermittent mildly prominent to hypoechoic pancreaticoduodenal and jejunal lymphadenopathy noted. Example of lymph node measured 0.39 cm in width.

**SEX**

**PRIMARY FINDINGS**

Neutered Male

- Mild chronic renal changes
- Asymmetrical splenic contour with mild decreased splenic parenchyma echogenicity
- Hepatomegaly with non-uniform echogenic parenchyma
- Mild gallbladder debris
- Suspect mild chronic active pancreatitis
- Non-specific enteropathy
- Mild cellular peritoneal free fluid and generalized echogenic mesentery

**AGE**

11 years

**WEIGHT**

10.9 Pounds

**SECONDARY FINDINGS**

- Mild urinary bladder mineral

**INTERPRETED BY**

**INTERPRETATION OF THE FINDINGS & FURTHER RECOMMENDATIONS**

R. McKenzie Daniel,  
DVM, DABVP  
(Canine and Feline)

The free fluid may indicate hemorrhage, non-septic (increased vascular permeability, decreased hydrostatic pressure), septic or neoplastic effusion. Further assessment including effusion analysis, cytology +/- C/S if evidence of inflammatory cells is recommended. Assuming normal clotting status, hepatosplenic FNA using 25-gauge needle recommended for screening cytology. Given the significant hyperglobulinemia, neoplasia is favored in this case, although not definitive. FIP is technically a potential as well, yet considered less likely given the age of the patient. CBC pathology review and protein electrophoresis may be considered. Guarded prognosis pending additional diagnostics.

**IMAGING PERFORMED BY**

Rebekah Jakum, CVT  
ARDMS/RVT

**HOSPITAL NAME**

Community VP

**REFERRING VET**

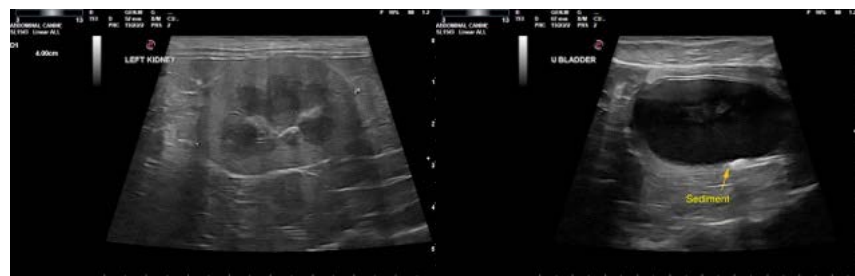Dr. Hulshizer

**INVOICE**

25137

**DATE**

9.1.2021





**PATIENT**

Joey Noyes

**SPECIES**

Feline

**BREED**

Domestic Shorthair

**SEX**

Neutered Male

**AGE**

11 years

**WEIGHT**

10.9 Pounds

**INTERPRETED BY**

R. McKenzie Daniel,  
DVM, DABVP  
(Canine and Feline)

**IMAGING PERFORMED BY**

Rebekah Jakum, CVT  
ARDMS/RVT

**HOSPITAL NAME**

Community VP

**REFERRING VET**

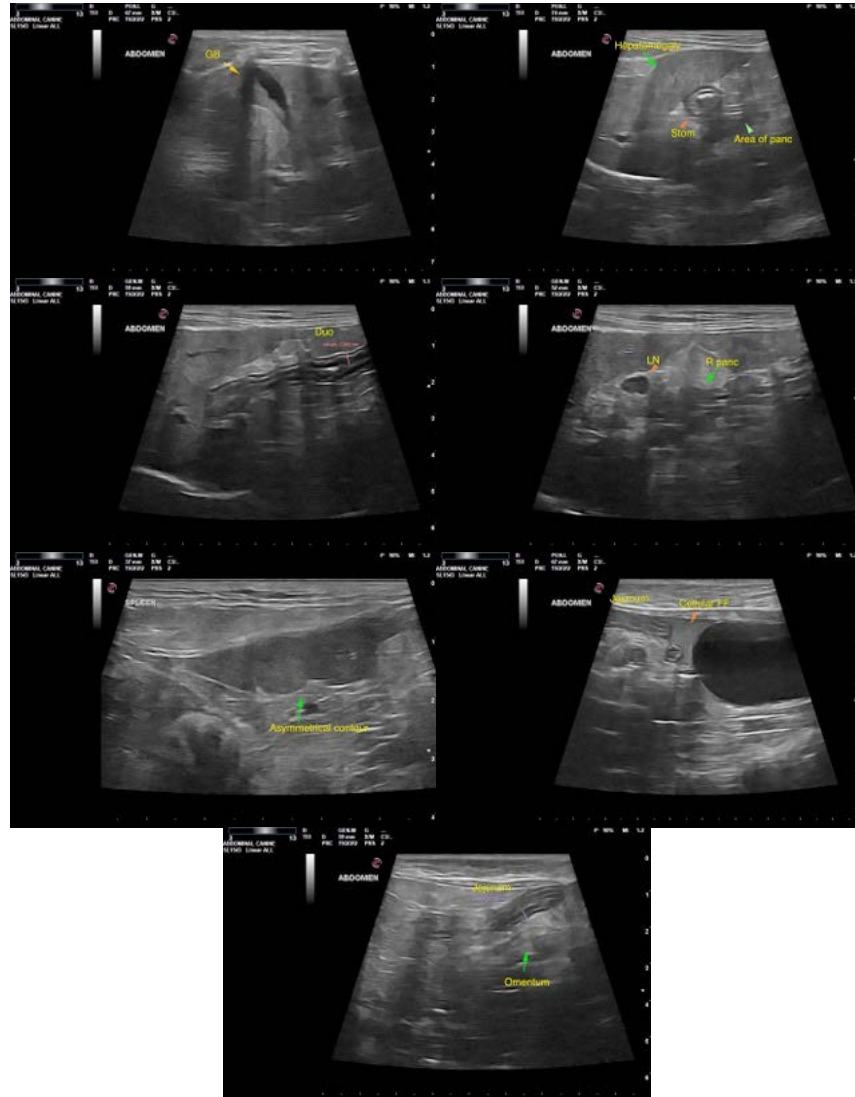
Dr. Hulshizer

**INVOICE**

25137

**DATE**

9.1.2021



The information and recommendations provided are based on the images presented by the referring veterinarian. No evaluation can be communicated regarding pathology that was not visible in the image/video clips provided.

Thank you for this referral. If the clinical or image interpretation does not parallel your findings or if I can be of any further assistance please contact me.

R. McKenzie Daniel, DVM, DABVP (Canine/Feline Practice)  
[mac.daniel@sonopath.com](mailto:mac.daniel@sonopath.com)