



**PATIENT**

Sophie Vickery

**SPECIES**

Feline

**BREED**

DLH

**SEX**

Spayed Female

**AGE**

15

**WEIGHT**

5.9 kg

**INTERPRETED BY**

R. McKenzie Daniel,  
DVM, DABVP  
(Canine and Feline)

**IMAGING PERFORMED BY**

Dr. Alastair Westcott

**HOSPITAL NAME**

Dr. Alastair Westcott,  
DVM

**REFERRING VET**

Dr. Alastair Westcott

**INVOICE**

23857

**DATE**

8/9/23

**PRESENTING CLINICAL SIGNS**

History: Was initially seen at the end of May this year with significant pyuria/cystitis/bacteriuria [cultured as E. coli]. Was treated at that time with subcutaneous fluids, maropitant and convenia. The urine demonstrated adequate concentration. 2 months later the signs return and once again a bacteriuria/pyuria was noted. Was treated with gabapentin and potentiated amoxicillin at that time. This did not adequately resolve and the pink-tinged urine/cystitis is continuing.

Abnormal PE/Chem/CBC/UA Results: Chronic, recurring cystitis over the last 3 months Moderately overweight Dental disease Blood work taken yearly in July demonstrated stress based hyperglycemia and was otherwise unremarkable. Significant pyuria with many rods and multiple translucent filaments which are reminiscent of fungal hyphae such as Candida. Gross glucosuria and proteinuria likely associated with a UTI Urine sample sent for culture and sensitivity.

**ULTRASONOGRAPHIC EXAMINATION OF THE ABDOMEN**

**Urinary System**

The urinary bladder was normal in size and tone. Minor prominent ventral to ventroapical urinary bladder wall was noted, exhibiting symmetrical luminal surface contour and homogenous mural echogenicity. Ventral apical urinary bladder wall measured 0.18 cm. Anechoic urine was present. No sediment, mineral or calculi was noted. No urinary bladder tumors were noted. The urethra was normal in tone to a depth of 2.0 cm.

The area of the aortic trifurcation was free of pathology.

Normal size and margination were present in the kidneys. A normal 1:3 cortex / medulla ratio was maintained. The medulla and cortices were uniform in texture with some increased echogenicity and loss of corticomedullary symmetry and definition expected for the age of the patient. Minor pyelectasia was noted in the left kidney. The left kidney measured 3.6 cm in length. The right kidney measured 3.7 cm in length.

**Adrenal Glands**

The left adrenal gland was uniform in size and contour with a uniformly hypoechoic parenchyma. The left adrenal gland measured 0.22 cm.

The right adrenal gland was uniform in size and contour with a uniformly hypoechoic parenchyma. The right adrenal gland measured 0.29 cm.

**Spleen**

The spleen exhibited a finely textured and homogenous parenchyma which was hyperechoic to the liver and renal cortical parenchyma. The capsule was smooth and regular without apparent expansion. The splenic vasculature at the hilus was normal in volume with no evidence of congestion or thrombosis. Acute to chronic inflammatory, neoplastic, or benign parenchyma changes were not noted.

**Liver**

The liver was subjectively normal in size, structure, and contour. The liver parenchyma was uniform and hypoechoic to the spleen with a mild coarse echotexture. The hepatic and portal vasculature were normal in appearance without signs of congestion.

The gallbladder was non-distended in size with thin walls and primarily anechoic luminal content. The cystic and common bile ducts were normal.



**PATIENT**

***Gastrointestinal***

Sophie Vickery

The stomach presented intact wall layering with a normal wall layer ratio. The lumen of the stomach was empty with no signs of ileus, obstruction or foreign material.

**SPECIES**

Feline

The small intestine exhibited generalized intact segmental borderline prominent jejunal wall layering. Jejunum wall measured 0.25 cm in wall width. The ileocolic wall measured 0.31 cm.

Normal visible colon wall layers were present with apparent formed feces in lumen.

**BREED**

***Pancreas***

DLH

The pancreas exhibited variable prominent size with mild capsule asymmetry. Generalized nonhomogenous hypoechoic indistinctly nodular pancreatic parenchyma was noted. Mild left and right limb pancreatic duct dilation was noted.

**SEX**

Spayed Female

***Free Abdomen***

**AGE**

15

Subtle evidence of peripancreatic hyperechoic omentum was noted. No omental masses or peritoneal effusion was present. Intermittent, minor homogeneous peripancreatic and pericolic mesenteric lymphadenopathy was noted. An example of lymph node size measured 0.5 cm in diameter.

**ULTRASONOGRAPHIC FINDINGS**

**WEIGHT**

5.9 kg

- Overall, sonographically unremarkable urinary bladder- possible minor cystitis
- Mild to moderate chronic renal changes with minor left kidney pyelectasia.
- Variably enlarged, asymmetrical nonhomogenous hypoechoic to nodular pancreas- chronic to chronic active pancreatitis and nodular hyperplasia are potentials. Potential for emerging non-exfoliating pancreatic neoplasia is possible yet thought less likely.
- Intact segmental borderline prominent small bowel wall- nonspecific
- Intermittent minor sonographically benign/reactive mesenteric lymph nodes

**INTERPRETED BY**

R. McKenzie Daniel,  
DVM, DABVP  
(Canine and Feline)

**IMAGING PERFORMED BY**

Dr. Alastair Westcott

**HOSPITAL NAME**

Dr. Alastair Westcott,  
DVM

**REFERRING VET**

Dr. Alastair Westcott

**INTERPRETATION OF THE FINDINGS & FURTHER RECOMMENDATIONS**

No evidence of significant upper or lower urinary tract pathology as a definitive contributing factor or nidus to recurrent cystitis or infection. No evidence of urinary tract neoplastic criteria. Correlation with pending urine culture and sensitivity is recommended. Monitoring for evidence of cranial abdominal or subxiphoid discomfort on palpation, which may allude to chronic to chronic active pancreatitis, is suggested. Spec FPL may be considered if clinical signs consistent with pancreatitis are present or arise.

The small intestine exhibited subtle mural changes, which although potential for patient variant, given no reported gastrointestinal signs, may suggest emerging to low grade inflammatory criteria. Monitoring for gastrointestinal signs and weight loss, going forward, is suggested with sonographic reassessment or serum cobalamin and folate levels, if clinically indicated, would be reasonable.

**INVOICE**

23857

**DATE**

8/9/23



**PATIENT**

Sophie Vickery

**SPECIES**

Feline

**BREED**

DLH

**SEX**

Spayed Female

**AGE**

15

**WEIGHT**

5.9 kg

**INTERPRETED BY**

R. McKenzie Daniel,  
DVM, DABVP  
(Canine and Feline)

**IMAGING PERFORMED BY**

Dr. Alastair Westcott

**HOSPITAL NAME**

Dr. Alastair Westcott,  
DVM

**REFERRING VET**

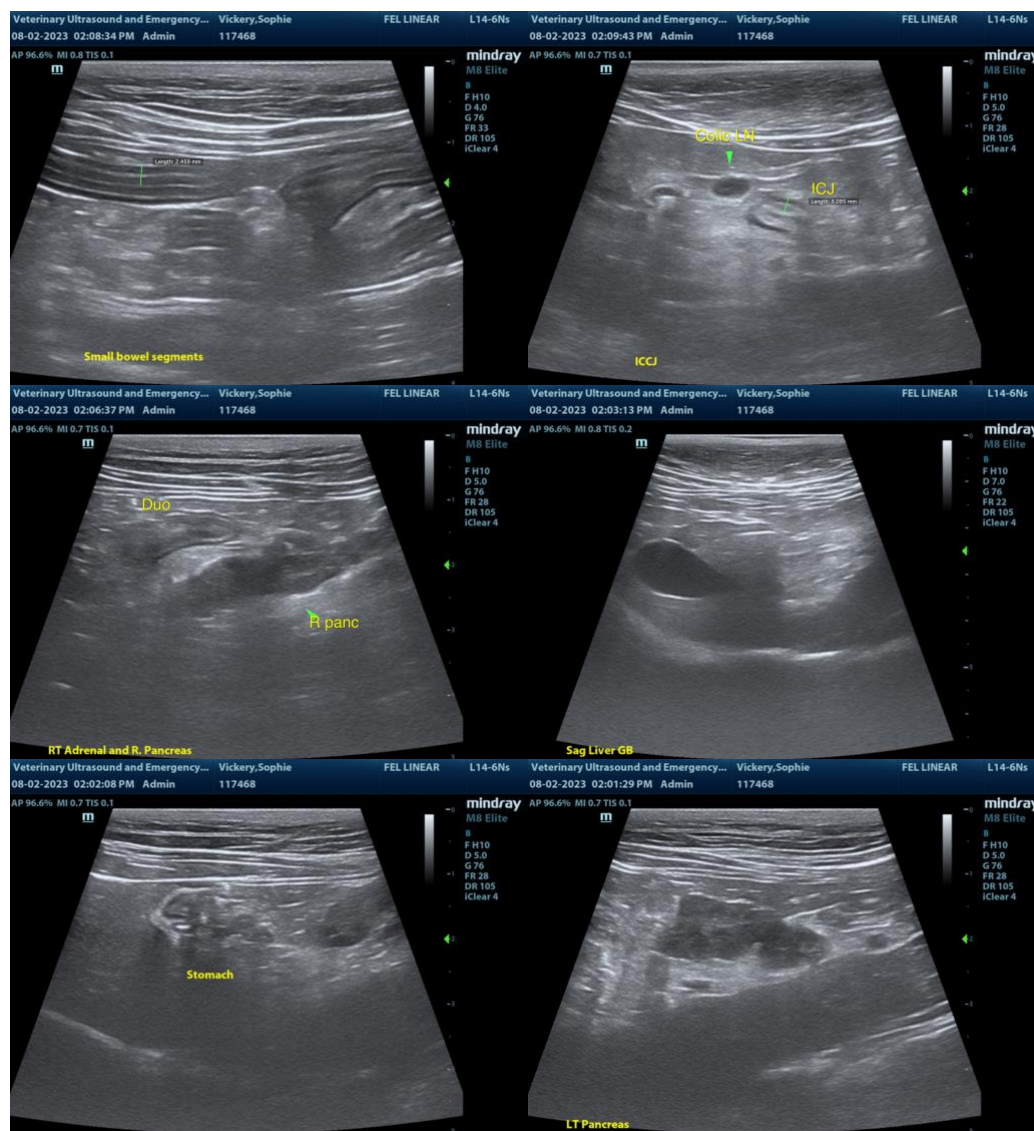
Dr. Alastair Westcott

**INVOICE**

23857

**DATE**

8/9/23





**PATIENT**

Sophie Vickery

**SPECIES**

Feline

**BREED**

DLH

**SEX**

Spayed Female

**AGE**

15

**WEIGHT**

5.9 kg

**INTERPRETED BY**

R. McKenzie Daniel,  
DVM, DABVP  
(Canine and Feline)

**IMAGING PERFORMED BY**

Dr. Alastair Westcott

**HOSPITAL NAME**

Dr. Alastair Westcott,  
DVM

**REFERRING VET**

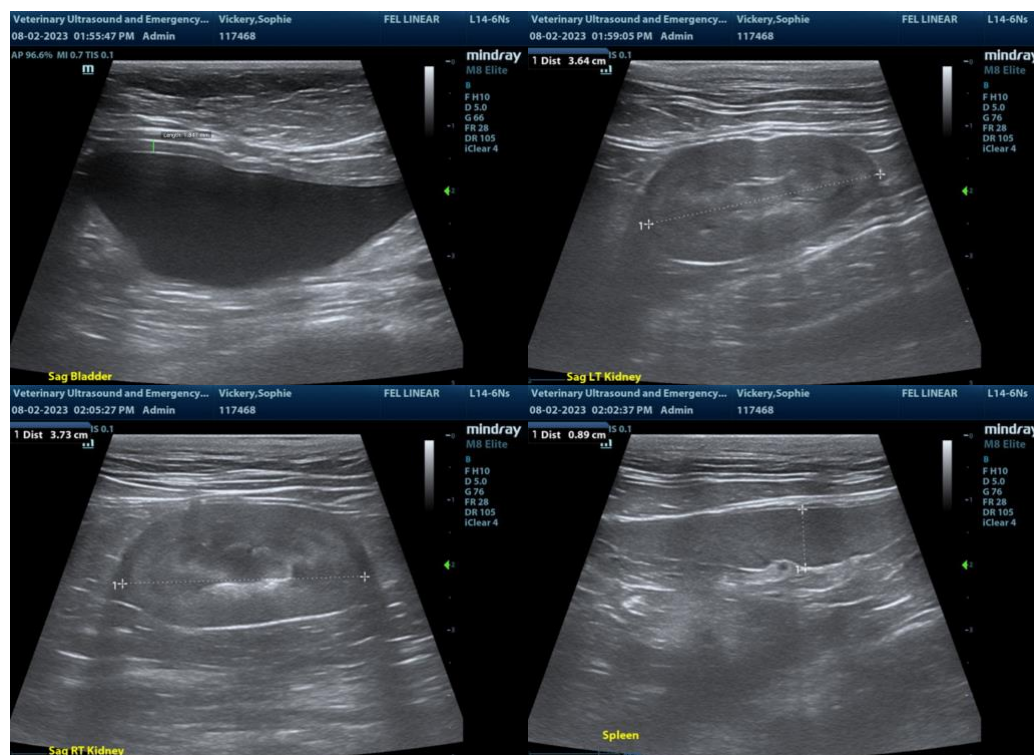
Dr. Alastair Westcott

**INVOICE**

23857

**DATE**

8/9/23



The information and recommendations provided are based on the images presented by the referring veterinarian. No evaluation can be communicated regarding pathology that was not visible in the image/video clips provided.

Thank you for this referral. If the clinical or image interpretation does not parallel your findings or if I can be of any further assistance please contact me.

R. McKenzie Daniel, DVM, DABVP (Canine / Feline Practice)  
info@SonoPath.com