



PATIENT

Waffles Grey

SPECIES

Canine

BREED

Miniature Schnauzer

SEX

Female Spayed

AGE

7 years

WEIGHT

17.4 lbs.

INTERPRETED BY

R. McKenzie Daniel,
DVM, DABVP
(Canine and Feline)

IMAGING PERFORMED BY

Dr. Meredith Swart

HOSPITAL NAME

Swart Veterinary
Imaging

REFERRING VET

Dr. Meredith Swart

INVOICE

14527

DATE

8/9/22

PRESENTING CLINICAL SIGNS

Recheck echo from January. Patient still not having any clinical signs of CHF. Patient in need of anesthesia so rDVM requested recheck echo

Abnormal PE/Chem/CBC/UA Results: none reported

ULTRASONOGRAPHIC EXAMINATION OF THE HEART

CANINE CARDIAC PARAMETERS	MR VMAX (m/s)	TR VMAX (m/s)	LA/AO (Boon method)	LA/AO (Heart Base; Swe)	FS (%)	EF (%)	EPSS (cm)
NORMAL PARAMETER	4.5-5.5	<2.7	1.3	<1.3	28-40	40-100	<0.6
PATIENT	~5.0			1.35	50	85	0.21
CANINE CARDIAC PARAMETERS	HR (BPM)	AV VMAX (m/s)	PV MAX (m/s)	BODY WEIGHT (kg)	LA 2D short axis Base view (cm)	LVIDd Avg; 2D and m- mode short axis (cm)	LVIDs Avg; 2D and m-mode short axis (cm)
NORMAL PARAMETER	50-100	0.7-1.7	0.7-1.6				
PATIENT	NM	1.5	1.1		2.7	2.75	

Cardiac Presentation

The echocardiogram in this patient demonstrated normal **left atrial** size based on 3 different LA measurement methods. Chamber volumes and echogenicity were normal. The cranial and caudal **mitral** valve leaflets mildly thickened, which may suggest early onset mild endocardiosis. Doppler indicated mild eccentric insufficiency. The **left ventricle** presented thicknesses with linear contour and was not dilated nor restricted. The **myocardium** presented normal echogenicity without subjective evidence of significant fibrotic or ischemic disease. **Contractility** of the ventricular walls was adequate and in normal range for this patient evidenced by the fractional shortening measurement and subjective evaluation of the different regions of the myocardium. The **left ventricular outflow** tract demonstrated normal laminar flow and subjective structural integrity. The **right atrium** and auricle revealed normal size, structure and content. No evidence of masses was noted or chamber overload. **Tricuspid** valvular assessment demonstrated adequate linear morphology. The **right ventricle** was of normal size (1/3 diameter of LV), chordae structure, myocardial echogenicity and thickness. **Pulmonic** tract assessment revealed normal valve structure, laminar flow, and diameter (approx. 1:1 pa/ao ratio). No visible **pericardial** or free pleura fluid was noted. No echographically detectable evidence of infiltrative disease was visible. The cranial **mediastinum and pericardial regions** were free of masses in the visible window.



PATIENT

Waffles Grey

SPECIES

Canine

BREED

Miniature Schnauzer

SEX

Female Spayed

AGE

7 years

WEIGHT

17.4 lbs.

INTERPRETED BY

R. McKenzie Daniel,
DVM, DABVP
(Canine and Feline)

IMAGING PERFORMED BY

Dr. Meredith Swart

HOSPITAL NAME

Swart Veterinary
Imaging

REFERRING VET

Dr. Meredith Swart

INVOICE

14527

DATE

8/9/22

ULTRASONOGRAPHIC FINDINGS

- Compensated mitral valve insufficiency
- Normal left atrium

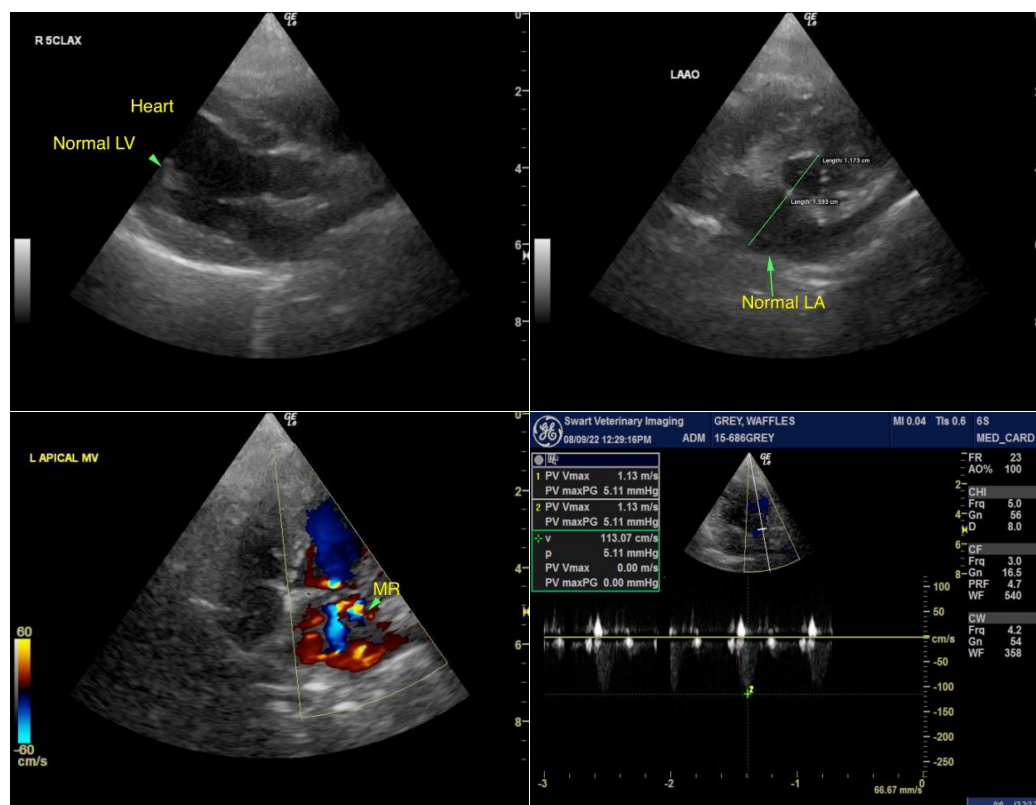
INTERPRETATION OF THE FINDINGS & FURTHER RECOMMENDATIONS

This study is consistent with the previous diagnosis of eccentric mitral valve insufficiency. The persistent lack of chamber enlargement associated with the mitral insufficiency indicates that the hemodynamic effects of the mitral valve Insufficiency remain low. No other clinical issues such as LV systolic dysfunction or obvious evidence of clinical pulmonary hypertension were present.

Given the overall static and compensated presentation of the heart without evidence of chamber enlargement and lack of clinical signs, no overt indication for medications at this stage. Serial sonographic monitoring, as well as conservative monitoring of the murmur, is recommended.

Recheck echocardiogram is suggested in 6 months, sooner if clinical signs arise. Based on this study and overall cardiac presentation, no anesthetic contraindications. The following anesthetic protocol, as previously recommended, is suggested.

Suggested anesthetic protocol may include opioid or Benzodiazepine pre-med, induction with Propofol or Alfaxalone, and appropriate gas anesthesia with avoidance of alpha 2 agonists.





PATIENT

Waffles Grey

SPECIES

Canine

BREED

Miniature Schnauzer

SEX

Female Spayed

AGE

7 years

WEIGHT

17.4 lbs.

INTERPRETED BY

R. McKenzie Daniel,
DVM, DABVP
(Canine and Feline)

IMAGING PERFORMED BY

Dr. Meredith Swart

HOSPITAL NAME

Swart Veterinary
Imaging

REFERRING VET

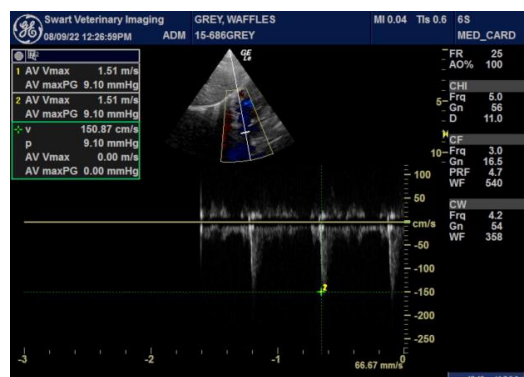
Dr. Meredith Swart

INVOICE

14527

DATE

8/9/22



The information and recommendations provided are based on the images presented by the referring veterinarian/sonographer. No evaluation can be communicated regarding pathology that was not visible in the image/video clips provided.

Thank you for this referral. If the clinical or image interpretation does not parallel your findings or if I can be of any further assistance please contact me.

R. McKenzie Daniel, DVM, DABVP (Canine / Feline Practice)
info@SonoPath.com