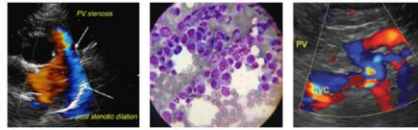


IMAGING PERFORMED BYSVS Mobile Imaging CT 262 - 366 - 5970
fredgromalak@gmail.com**PATIENT**

Truman McSweeny

SPECIES

Canine

BREEDPortugese Water
Dog**SEX**

Male Neutered

AGE

11Y 7M

WEIGHT

53 lbs.

INTERPRETED BYR. McKenzie Daniel,
DVM, DABVP
(Canine and Feline)**IMAGING PERFORMED BY**

Tom McNeill

HOSPITAL NAME

SVS Imaging CT

REFERRING VETAll Creatures Small
Animal Hospital- Dr.
McSweeny**INVOICE**

14534

DATE

8/9/22

PRESENTING CLINICAL SIGNS

Lack of appetite, slowing down, owner noticing lumps.
 Abnormal PE/Chem/CBC/UA Results: Palpable abdominal mass, suspected splenic in origin.

ULTRASONOGRAPHIC EXAMINATION OF THE ABDOMEN**Urinary System**

The urinary bladder, trigone, and cystourethral junction exhibited normal thickness and tone. Mild asymmetrical luminal surface to micropolyploid changes were present primarily in ventroapical to dorsoapical urinary bladder wall, likely associated with age-related mural changes. The ventroapical urinary bladder wall width measured 0.50 cm. Anechoic urine was present in the lumen with no uroliths or sediment. The ureteral papillae were normal. The ureters were not visible which is normal. No evidence of inflammatory changes or urinary bladder neoplastic criteria were noted. Potential for minor cystitis is possible.

The residual prostate exhibited subjective mild prominent size with maintained symmetrical capsule contour and homogeneous parenchyma measuring 1.7 cm in diameter. No evidence of residual prostatic parenchymal mineralization was noted. This is likely a normal residual prostate presentation for this patient without evidence of prostatic pathology.

Visualized medial iliac lymph nodes exhibited normal size, position, and shape without isoechoic parenchyma and width:length ratio (<0.5). An example measured 2.3 cm x 0.46 cm. This is likely incidental. No evidence of medial iliac or omental lymphatic pathology was noted.

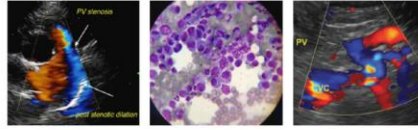
Normal size and margination were present in the kidneys. A normal 1:3 cortex / medulla ratio was maintained. The medulla and cortices were uniform in texture with some increased echogenicity and mild loss of corticomedullary symmetry and definition expected for the age of the patient. No evidence of pelvic dilation was present. A small left kidney corticomedullary border cyst measuring 0.26 cm in diameter was present. The left kidney measured 5.8 cm in length. The right kidney measured 6.5 cm in length.

Adrenal Glands

The left adrenal gland was uniform in size and contour with a uniformly hypoechoic parenchyma. The left adrenal gland measured 0.73 cm width at the caudal pole and 0.65 cm width at the cranial pole. The right adrenal gland was uniform in size and contour with a uniformly hypoechoic parenchyma. The right adrenal gland measured 0.61 cm width at the caudal pole and 0.92 cm width at the cranial pole.

Spleen

A large, expansive, nonhomogeneous to mixed echogenic splenic mass was present measuring approximately 10.0 cm in diameter with associated splenic capsule distortion. Concurrent, separate, mildly expansive nonhomogeneous splenic nodule measuring 2.7 cm in diameter was present with mild associated capsule distortion. The spleen not involved with the mass or nodule exhibited mild parenchyma heterogeneity.

IMAGING PERFORMED BYSVS Mobile Imaging CT 262 - 366 - 5970
fredgromalak@gmail.com**PATIENT**

Truman McSweeny

SPECIES

Canine

BREEDPortugese Water
Dog**SEX**

Male Neutered

AGE

11Y 7M

WEIGHT

53 lbs.

INTERPRETED BYR. McKenzie Daniel,
DVM, DABVP
(Canine and Feline)**IMAGING PERFORMED BY**

Tom McNeill

HOSPITAL NAME

SVS Imaging CT

REFERRING VETAll Creatures Small
Animal Hospital- Dr.
McSweeny**INVOICE**

14534

DATE

8/9/22

Liver/ Gallbladder

The liver was subjectively normal in size, structure, and contour. The liver parenchyma was mildly nonuniform and hypoechoic to the spleen with a moderate coarse echotexture and mild parenchymal remodeling. A solitary discrete nondisruptive hyperechoic intraparenchymal nodule measuring 0.52 cm in diameter was present. The hepatic and portal vasculature were normal in appearance without signs of congestion. The gallbladder was non-distended in size with thin walls and primarily anechoic luminal content. The cystic and common bile ducts were normal.

Gastrointestinal

The stomach presented intact wall layering with a normal wall layer ratio. The lumen of the stomach was empty with no signs of ileus, obstruction, or foreign material.

The small intestine presented intact wall layering with 1:3 muscularis/mucosa ratio. The lumen of the small intestine was empty with no signs of ileus, obstruction, or foreign material.

Normal visible colon wall layers were present with apparent formed feces in lumen.

Pancreas

The pancreas was normal in size and contour with isoechoic to heterogeneous parenchyma compared to adjacent omentum. No signs of active inflammation or neoplasia.

Free Abdomen

Mild regional splenic hyperechoic mesentery and a small pocket of scant perisplenic free fluid was present.

Rapid view of the heart revealed no overt evidence of pericardial effusion or overt cardiac / pericardial masses.

ULTRASONOGRAPHIC FINDINGS

- Large mixed echogenic splenic mass with concurrent separate mildly expansive splenic nodule
- Minor hepatic parenchymal remodeling with solitary discrete hyperechoic Intraparenchymal nodule - nodule suggestive of focal discrete nodular hyperplasia or small lipogranuloma
- Regional mild perisplenic hyperechoic mesentery and small pocket of scant perisplenic free fluid
- Mild age-related renal changes.

INTERPRETATION OF THE FINDINGS & FURTHER RECOMMENDATIONS

The splenic mass and concurrent nodule were not specific yet likely suggestive of neoplastic criteria such as sarcoma or other. Benign pathologies are possible i.e., hyperplasia, hematopoiesis, granuloma, splenitis, etc., yet considered less likely differential diagnoses.

No overt or definitive evidence of intraabdominal metastasis yet, in these cases, potential for non-sonographically evident metastasis / micrometastasis cannot be definitively excluded. Assuming no

IMAGING PERFORMED BY

SVS Mobile Imaging CT 262 - 366 - 5970
fredgromalak@gmail.com



PATIENT

Truman McSweeny

SPECIES

Canine

BREED

Portugese Water Dog

SEX

Male Neutered

AGE

11Y 7M

WEIGHT

53 lbs.

INTERPRETED BY

R. McKenzie Daniel,
DVM, DABVP
(Canine and Feline)

IMAGING PERFORMED BY

Tom McNeill

HOSPITAL NAME

SVS Imaging CT

REFERRING VET

All Creatures Small
Animal Hospital- Dr.
McSweeny

INVOICE

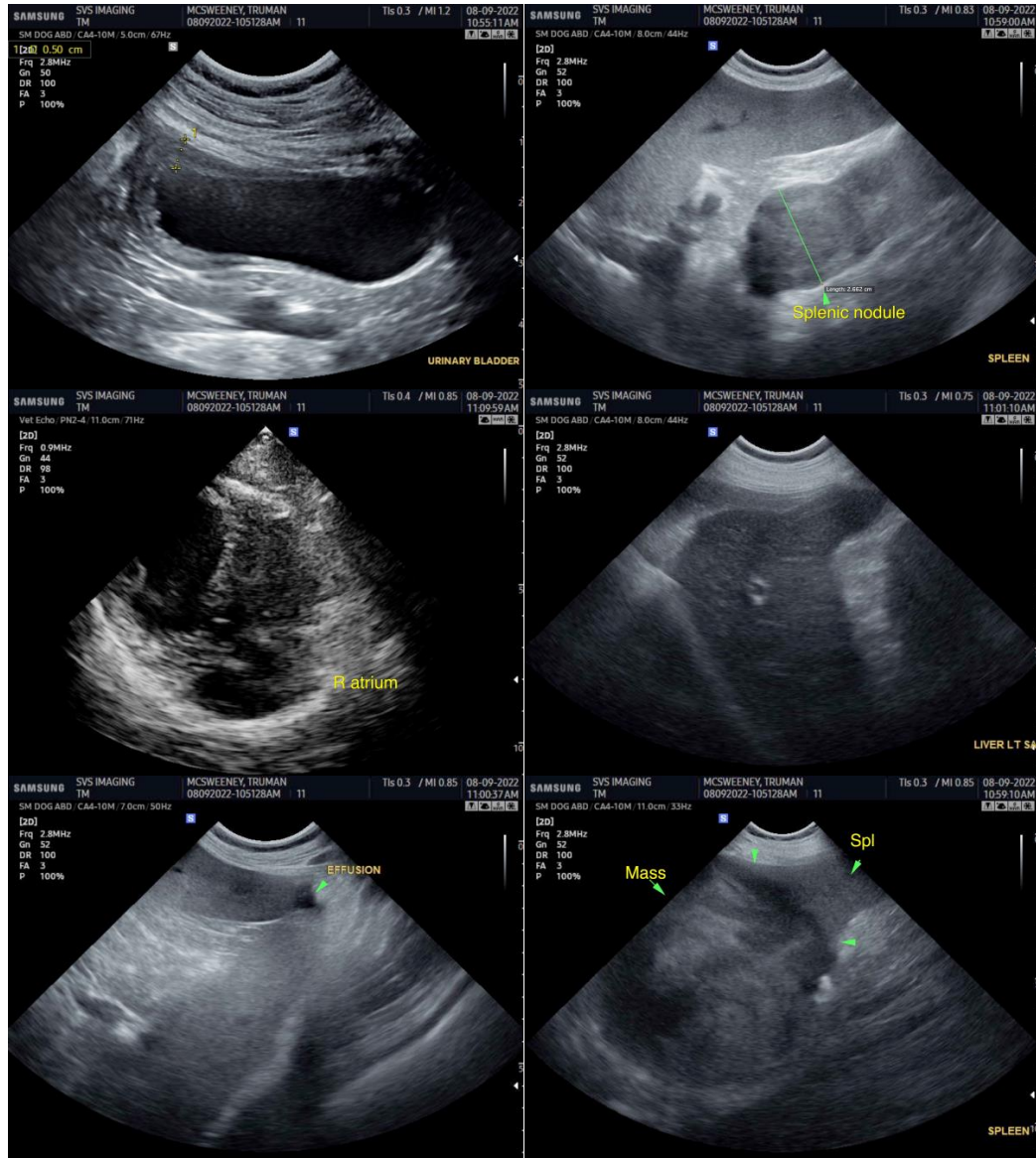
14534

DATE

8/9/22

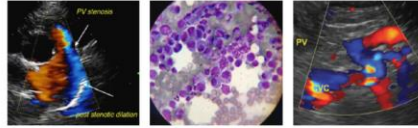
evidence of pathology on three view chest radiographs, laparotomy with expectation towards splenectomy, gross inspection of the perisplenic omentum, and liver is warranted.

A guarded prognosis pending splenic histopathology.



IMAGING PERFORMED BY

SVS Mobile Imaging CT 262 - 366 - 5970
fredgromalak@gmail.com



PATIENT

Truman McSweeney

SPECIES

Canine

BREED

Portugese Water Dog

SEX

Male Neutered

AGE

11Y 7M

WEIGHT

53 lbs.

INTERPRETED BY

R. McKenzie Daniel,
DVM, DABVP
(Canine and Feline)

IMAGING PERFORMED BY

Tom McNeill

HOSPITAL NAME

SVS Imaging CT

REFERRING VET

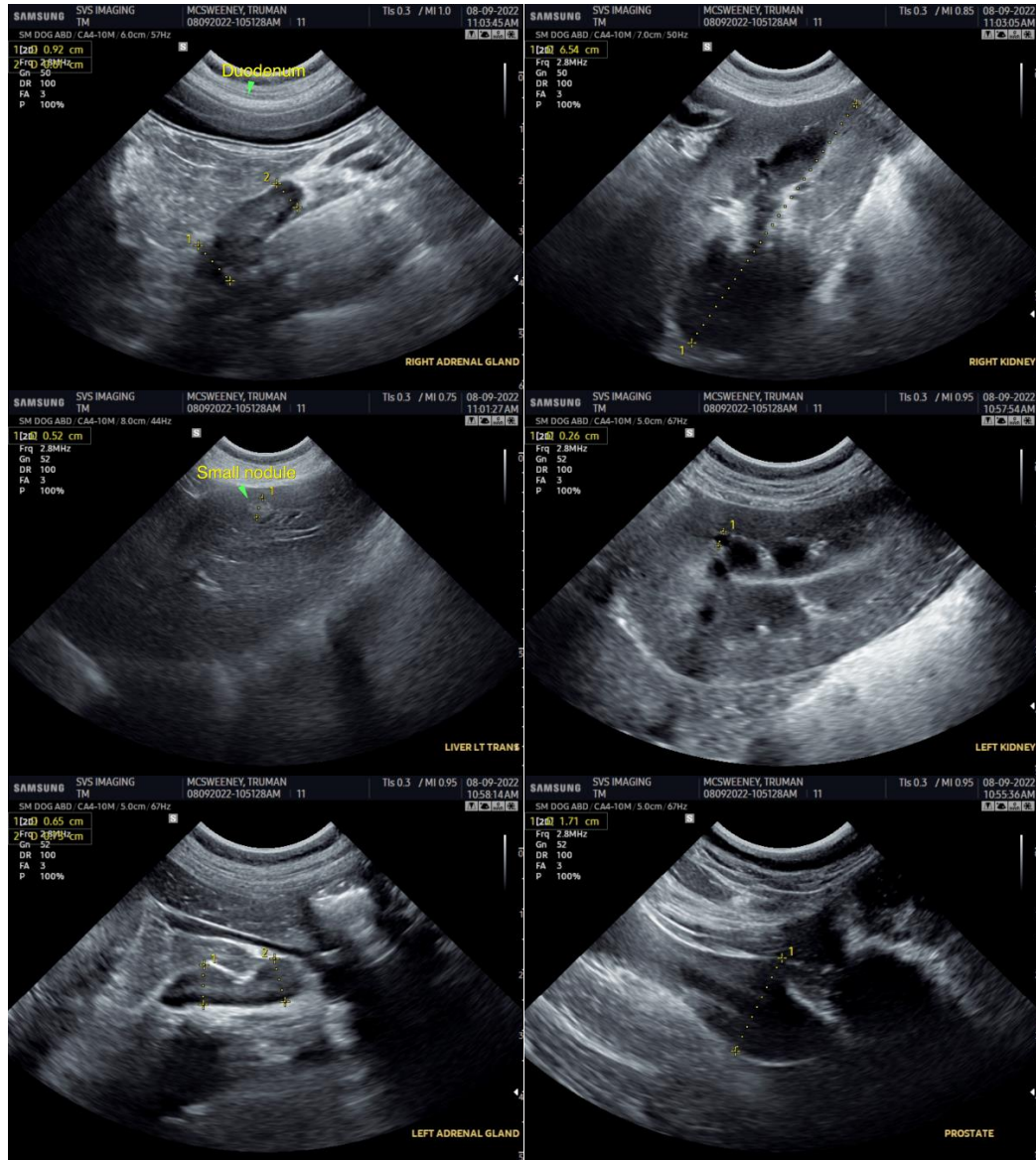
All Creatures Small
Animal Hospital- Dr.
McSweeney

INVOICE

14534

DATE

8/9/22



The information and recommendations provided are based on the images presented by the referring veterinarian/sonographer. No evaluation can be communicated regarding pathology that was not visible in the image/video clips provided.

Thank you for this referral. If the clinical or image interpretation does not parallel your findings or if I can be of any further assistance please contact me.

R. McKenzie Daniel, DVM, DABVP (Canine / Feline Practice)
info@SonoPath.com