



PATIENT

Chewie Young

SPECIES

Canine

BREED

Golden Doodle

SEX

MN

AGE

5 Years

WEIGHT

74 lbs.

PRESENTING CLINICAL SIGNS

frequent vomiting since puppy, r/o IBD, etc Current meds: Doxycycline

Abnormal PE/Chem/CBC/UA Results: mod mature neutrophilia + monocytosis, glob 4.1, (+Lyme, CI 78, +Anoplasma 7/14/22)

ULTRASONOGRAPHIC EXAMINATION OF THE ABDOMEN

Urinary System

The urinary bladder, trigone, and cystourethral junction exhibited normal thickness and tone. Anechoic urine was present in the lumen with no uroliths or sediment. The ureteral papillae were normal. The ureters were not visible which is normal. No evidence of inflammatory or neoplastic changes was noted.

The area of the aortic trifurcation was free of pathology.

Normal size and margination were present in the kidneys. A normal 1:3 cortex / medulla ratio and normal corticomedullary definition were maintained. The echogenicity of the cortex was similar to or slightly less than normal liver parenchyma while the medulla echogenicity was hypoechoic to the cortex with no evidence of pelvic dilation. The left kidney measured 6.6 cm in length. The right kidney measured 6.7 cm in length.

INTERPRETED BY

R. McKenzie Daniel,
DVM, DABVP
(Canine and Feline)

Adrenal Glands

The left adrenal gland was uniform in size and contour with a uniformly hypoechoic parenchyma. The left adrenal gland measured 2.6 cm length x 0.49 cm width at the caudal pole. The right adrenal gland was uniform in size and contour with a uniformly hypoechoic parenchyma. The right adrenal gland measured 3.4 cm length x 0.49 cm width at the caudal pole.

IMAGING PERFORMED BY

Jessica Miller

Spleen

The spleen exhibited a finely textured and homogenous parenchyma which was hyperechoic to the liver and renal cortical parenchyma. The capsule was smooth and regular without apparent expansion. The splenic vasculature at the hilus was normal in volume with no evidence of congestion or thrombosis. Acute to chronic inflammatory, neoplastic, or benign parenchyma changes were not noted.

HOSPITAL NAME

Ringwood AH

Liver/ Gallbladder

REFERRING VET

Dr. Despirito

The liver was subjectively normal in size, structure, and contour. The liver parenchyma was uniform and hypoechoic to the spleen with a mild coarse echotexture. The hepatic and portal vasculature were normal in appearance without signs of congestion. The gallbladder was non-distended in size with thin walls and primarily anechoic luminal content. The cystic and common bile ducts were normal.

INVOICE

14525

Gastrointestinal

DATE

8/9/22

The stomach presented intact wall layering with a normal wall layer ratio. The lumen of the stomach was empty with no signs of ileus, obstruction, or foreign material. The gastric body wall width measured 0.40 cm.



PATIENT

Chewie Young

The small intestine presented intact wall layering with 1:3 muscularis/mucosa ratio. The lumen of the small intestine was empty with no signs of ileus, obstruction, or foreign material. The duodenum wall measured 0.47 cm width. The jejunum wall measured 0.41 cm width.

SPECIES

Canine

Normal visible colon wall layers were present with apparent formed feces in lumen.

BREED

Golden Doodle

Pancreas

The parenchyma of the left limb, body, and right limb of the pancreas presented isoechoic to the adjacent omental fat. A normal curvilinear capsule contour of the pancreas was present. The visible pancreatic duct was normal. No signs of active inflammation or neoplastic disease were evident.

SEX

MN

Free Abdomen

No overt lymphadenopathy or peritoneal effusion was present.

AGE

5 Years

ULTRASONOGRAPHIC FINDINGS

- Sonographically unremarkable abdomen

WEIGHT

74 lbs.

INTERPRETATION OF THE FINDINGS & FURTHER RECOMMENDATIONS

No evidence of abdominal visceral, specifically gastrointestinal or pancreatic, pathology as an obvious cause of the patient's frequent vomiting. Dietary intolerance / food allergy, occult parasitism, or structurally insignificant inflammatory gastroenteropathy are possible. Hydrolyzed diet trial with potential long-term dietary therapy, broad-spectrum deworming i.e., Panacur 50 mg/kg PO SID for at least 5 consecutive days, and as-needed gastrointestinal support with an assessment of clinical response would be reasonable.

INTERPRETED BY

R. McKenzie Daniel,
DVM, DABVP
(Canine and Feline)

Although considered unlikely, resting cortisol level to rule out occult Addison's Disease, could be considered. Three-view chest radiographs, if not done, are suggested to rule out occult thoracic or esophageal pathology as a contributing factor.

IMAGING PERFORMED BY

Jessica Miller

HOSPITAL NAME

Ringwood AH

REFERRING VET

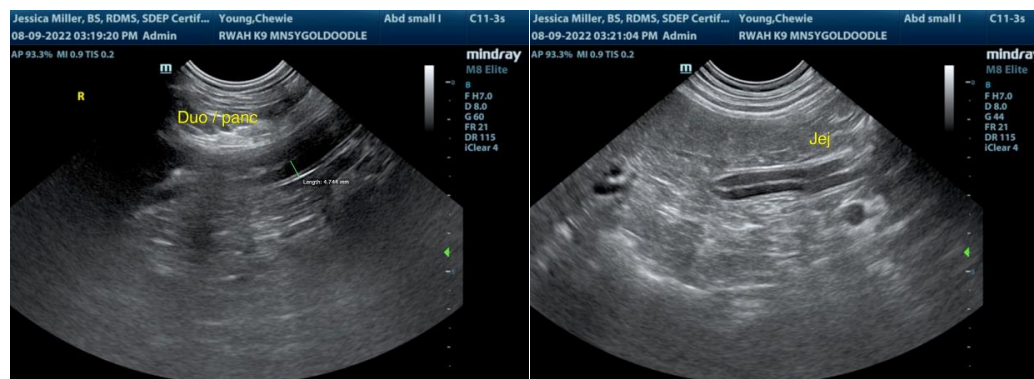
Dr. Despirito

INVOICE

14525

DATE

8/9/22





PATIENT

Chewie Young

SPECIES

Canine

BREED

Golden Doodle

SEX

MN

AGE

5 Years

WEIGHT

74 lbs.

INTERPRETED BY

R. McKenzie Daniel,
DVM, DABVP
(Canine and Feline)

IMAGING PERFORMED BY

Jessica Miller

HOSPITAL NAME

Ringwood AH

REFERRING VET

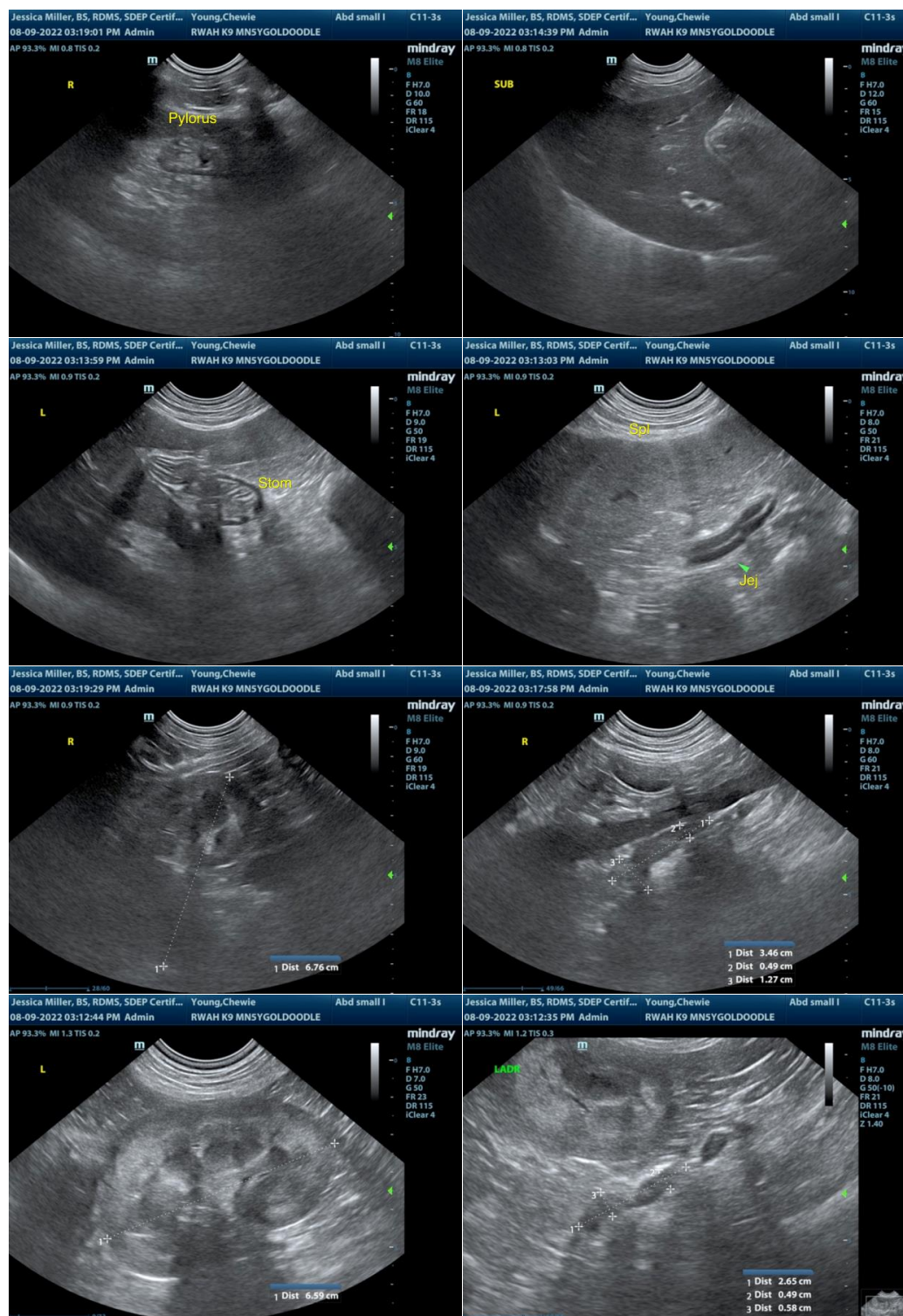
Dr. Despirito

INVOICE

14525

DATE

8/9/22



The information and recommendations provided are based on the images presented by the referring veterinarian/sonographer. No evaluation can be communicated regarding pathology that was not visible in the image/video clips provided.



PATIENT

Chewie Young

Thank you for this referral. If the clinical or image interpretation does not parallel your findings or if I can be of any further assistance please contact me.

SPECIES

Canine

R. McKenzie Daniel, DVM, DABVP (Canine / Feline Practice)
info@SonoPath.com

BREED

Golden Doodle

SEX

MN

AGE

5 Years

WEIGHT

74 lbs.

INTERPRETED BY

R. McKenzie Daniel,
DVM, DABVP
(Canine and Feline)

**IMAGING
PERFORMED BY**

Jessica Miller

HOSPITAL NAME

Ringwood AH

REFERRING VET

Dr. Despirito

INVOICE

14525

DATE

8/9/22