



**PATIENT**

Zeus Tadros

**PRESENTING CLINICAL SIGNS**

liquid stool, not eating, gave pumpkin-vomited

**SPECIES**

Canine

**ULTRASONOGRAPHIC EXAMINATION OF THE ABDOMEN**

**Urinary System**

The urinary bladder, trigone, cystourethral junction, and visible pelvic urethra exhibited normal thickness and tone. Anechoic urine was present in the lumen with no uroliths or sediment. The ureteral papillae were normal. The ureters were not visible which is normal. No evidence of inflammatory or neoplastic changes were noted.

**BREED**

Retriever Mix

Normal size and margination were present in the kidneys. A normal 1:3 cortex / medulla ratio and normal corticomedullary definition were maintained. The echogenicity of the cortex was similar to or slightly less than normal liver parenchyma while the medulla echogenicity was hypoechoic to the cortex with no evidence of pelvic dilation. The left kidney measured 7.0 cm in length. The right kidney measured 7.8 cm in length.

**SEX**

MN

**AGE**

2

The area of the aortic trifurcation was free of pathology.

The area of the residual prostate appeared normal and free of pathology.

**Adrenal Glands**

The left adrenal gland was uniform in size and contour with a uniformly hypoechoic parenchyma. The left adrenal gland measured 0.44 cm width at the caudal pole and 2.7 cm length. The right adrenal gland was uniform in size and contour with a uniformly hypoechoic parenchyma. The right adrenal gland measured 0.65 cm width at the caudal pole and 2.2 cm length.

**WEIGHT**

83

**INTERPRETED BY**

R. McKenzie Daniel,  
DVM, DABVP  
(Canine and Feline)

**Spleen**

The spleen exhibited a finely textured and homogenous parenchyma which was hyperechoic to the liver and renal cortical parenchyma. The capsule was smooth and regular without apparent expansion. The splenic vasculature at the hilus was normal in volume with no evidence of congestion or thrombosis. Acute to chronic inflammatory, neoplastic, or benign parenchyma changes were not noted.

**IMAGING PERFORMED BY**

Jenn

**Liver/Gallbladder**

The liver was subjectively normal in size, structure, and contour. The liver parenchyma was uniform and hypoechoic to the spleen with a mild coarse echotexture. Normal vascular volume. The hepatic and portal vasculature were normal in appearance without signs of congestion. The gallbladder was non-distended in size with thin walls and primarily anechoic luminal content. The cystic and common bile ducts were normal.

**HOSPITAL NAME**

Rockaway Animal  
Hospital

**REFERRING VET**

Dr. Maniar

**Gastrointestinal**

The stomach presented intact wall layering with a normal wall layer ratio. The lumen of the stomach contained mild retained anechoic fluid with no signs of ileus, obstruction or overt foreign material.

**INVOICE**

14497ag

The small intestine presented intact wall layering with 1:3 muscularis/mucosa ratio. The lumen of the small intestine was empty with no signs of ileus, obstruction or foreign material.

**DATE**

08/08/2023



**PATIENT**

Normal visible colon wall layers were present with apparent formed feces in lumen.

Zeus Tadros

**Pancreas**

**SPECIES**

The parenchyma of the left limb, body and right limb of the pancreas presented isoechoic to the adjacent omental fat. A normal curvilinear capsule contour of the pancreas was present. The visible pancreatic duct was normal. No signs of active inflammation or neoplastic disease was evident.

Canine

**Free Abdomen**

**BREED**

No omental masses, overt lymphadenopathy or peritoneal effusion was present.

Retriever Mix

**ULTRASONOGRAPHIC FINDINGS**

**SEX**

- Mild hypomotile stomach.
- Sonographically unremarkable small bowel/colon.

MN

**AGE**

**INTERPRETATION OF THE FINDINGS & FURTHER RECOMMENDATIONS**

2

Overall, there is no overt evidence of significant abdominal visceral, specifically GI pathology, as a definitive cause of the patient's clinical signs. No evidence of GI foreign body or obstructive pattern. Dietary indiscretion / food hypersensitivity, occult parasitism, enterotoxic insult, infectious disease, occult Addison's disease, structurally insignificant inflammatory gastroenteropathy or low grade to chronic pancreatitis both of which may appear sonographically normal are all potentials.

**WEIGHT**

83

A GI panel to include PLI/TLI/Cobalamin/Folate is recommended. Although considered unlikely considering normal adrenal presentation, a resting cortisol level to rule out occult Addison's disease is recommended.

**INTERPRETED BY**

R. McKenzie Daniel,  
DVM, DABVP  
(Canine and Feline)

Empirically, a limited antigen or hydrolyzed diet trial with potential long term dietary therapy, prophylactic deworming (Panacur 50 mg/kg SID x 5 consecutive days with repeat protocol in 3 weeks even if fecal testing is negative), high colony count probiotic (Provable or Visbiome), +/- antibiotic trial and as needed GI support with assessment of clinical response may prove beneficial.

**IMAGING PERFORMED BY**

Jenn

Sonographic reassessment may be considered if persistent/progressive GI signs despite supportive care and/or weight loss.

**HOSPITAL NAME**

Rockaway Animal  
Hospital

**REFERRING VET**

Dr. Maniar

**INVOICE**

14497ag

**DATE**

08/08/2023



**PATIENT**

Zeus Tadros

**SPECIES**

Canine

**BREED**

Retriever Mix

**SEX**

MN

**AGE**

2

**WEIGHT**

83

**INTERPRETED BY**

R. McKenzie Daniel,  
DVM, DABVP  
(Canine and Feline)

**IMAGING PERFORMED BY**

Jenn

**HOSPITAL NAME**

Rockaway Animal  
Hospital

**REFERRING VET**

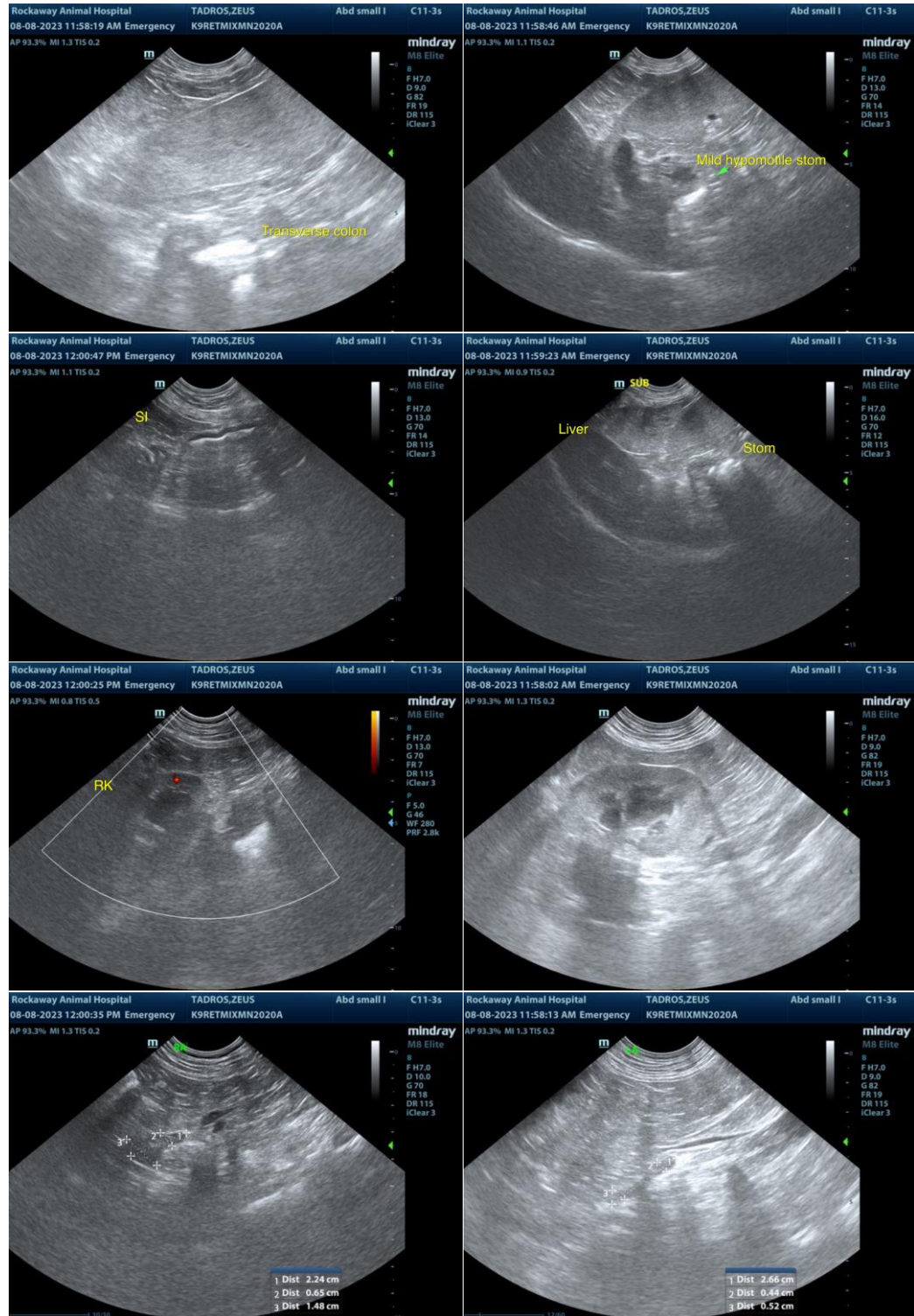
Dr. Maniar

**INVOICE**

14497ag

**DATE**

08/08/2023





**PATIENT**

Zeus Tadros

The information and recommendations provided are based on the images presented by the referring veterinarian/sonographer. No evaluation can be communicated regarding pathology that was not visible in the image/video clips provided.

**SPECIES**

Canine

Thank you for this referral. If the clinical or image interpretation does not parallel your findings or if I can be of any further assistance, please contact me.

**BREED**

Retriever Mix

R. McKenzie Daniel, DVM, DABVP (Canine/Feline Practice)  
[info@sonopath.com](mailto:info@sonopath.com)

**SEX**

MN

**AGE**

2

**WEIGHT**

83

**INTERPRETED BY**

R. McKenzie Daniel,  
DVM, DABVP  
(Canine and Feline)

**IMAGING PERFORMED BY**

Jenn

**HOSPITAL NAME**

Rockaway Animal  
Hospital

**REFERRING VET**

Dr. Maniar

**INVOICE**

14497ag

**DATE**

08/08/2023