



PATIENT

Mia Resciniti

PRESENTING CLINICAL SIGNS

History: Grade II-III/VI murmur

SPECIES

Canine

BREED

Yorkie

SEX

FS

AGE

8yr

WEIGHT

8lb

INTERPRETED BY

R. McKenzie Daniel,
DVM, DABVP
(Canine and Feline)

IMAGING PERFORMED BY

Jessica Miller

HOSPITAL NAME

Willowbrook AC

REFERRING VET

Dr. Palescandolo

INVOICE

11317ag

DATE

08/08/2022

ULTRASONOGRAPHIC EXAMINATION OF THE HEART

CANINE CARDIAC PARAMETERS	MR VMAX (m/s)	TR VMAX (m/s)	LA/AO (Boon method)	LA/AO (Heart Base; Swe)	FS (%)	EF (%)	EPSS (cm)
NORMAL PARAMETER	4.5-5.5	<2.7	1.3	<1.3	28-40	40-100	<0.6
PATIENT	5.1	2.2		1.3	40	73.1	0.15
CANINE CARDIAC PARAMETERS	HR (BPM)	AV VMAX (m/s)	PV MAX (m/s)	BODY WEIGHT (kg)	LA 2D short axis Base view (cm)	LVIDd Avg; 2D and m-mode short axis (cm)	LVIDs Avg; 2D and m-mode short axis (cm)
NORMAL PARAMETER	50-100	0.7-1.7	0.7-1.6				
PATIENT	171	1.2	1.2		2.1	2.15	

Cardiac Presentation

The echocardiogram in this patient demonstrated normal left atrial size based on 3 different LA measurement methods. Chamber volumes and echogenicity were normal. The cranial and caudal mitral valve leaflets presented mild vegetative thickening consistent with mild endocardiosis. Doppler indicated measurable mild eccentric insufficiency. The left ventricle presented thicknesses with linear contour and was not dilated nor restricted. The myocardium presented normal echogenicity without subjective evidence of significant fibrotic or ischemic disease. Contractility of the ventricular walls was adequate and in normal range for this patient evidenced by the fractional shortening measurement and subjective evaluation of the different regions of the myocardium. The left ventricular outflow tract demonstrated normal laminar flow and subjective structural integrity. The right atrium and auricle revealed normal size, structure and content. No evidence of masses was noted or chamber overload. Tricuspid valvular assessment demonstrated adequate linear morphology. Mild TR present on Doppler. The right ventricle was of normal size (1/3 diameter of LV), chordae structure, myocardial echogenicity and thickness. Pulmonic tract assessment revealed normal valve structure, laminar flow, and diameter (approx.1:1 pa/ao ratio). No visible pericardial or free pleura fluid was noted. No echographically detectable evidence of infiltrative disease was visible. The cranial mediastinum and pericardial regions were free of masses in the visible window.

ULTRASONOGRAPHIC FINDINGS

- Chronic mitral valve disease (ACVIM B1)
- Mild TR-no evidence of clinical pulmonary hypertension

INTERPRETATION OF THE FINDINGS & FURTHER RECOMMENDATIONS

The cause of the murmur is chronic degenerative valvular changes with secondary eccentric mitral valve insufficiency. The lack of left atrial enlargement implies that the risk of complication secondary to mitral valve insufficiency is low at this time and, without current clinical signs, indicates that medical therapy is not required. Prognosis at this stage is highly variable and serial sonographic monitoring is



PATIENT

Mia Resciniti

required for further assessment. Conservative monitoring with a recheck echocardiogram in 6-12 months, sooner if clinical signs suggestive of heart disease develop.

No anesthetic contraindications if anesthesia is required.

SPECIES

Canine

BREED

Yorkie

SEX

FS

AGE

8yr

WEIGHT

8lb

INTERPRETED BY

R. McKenzie Daniel,
DVM, DABVP
(Canine and Feline)

IMAGING PERFORMED BY

Jessica Miller

HOSPITAL NAME

Willowbrook AC

REFERRING VET

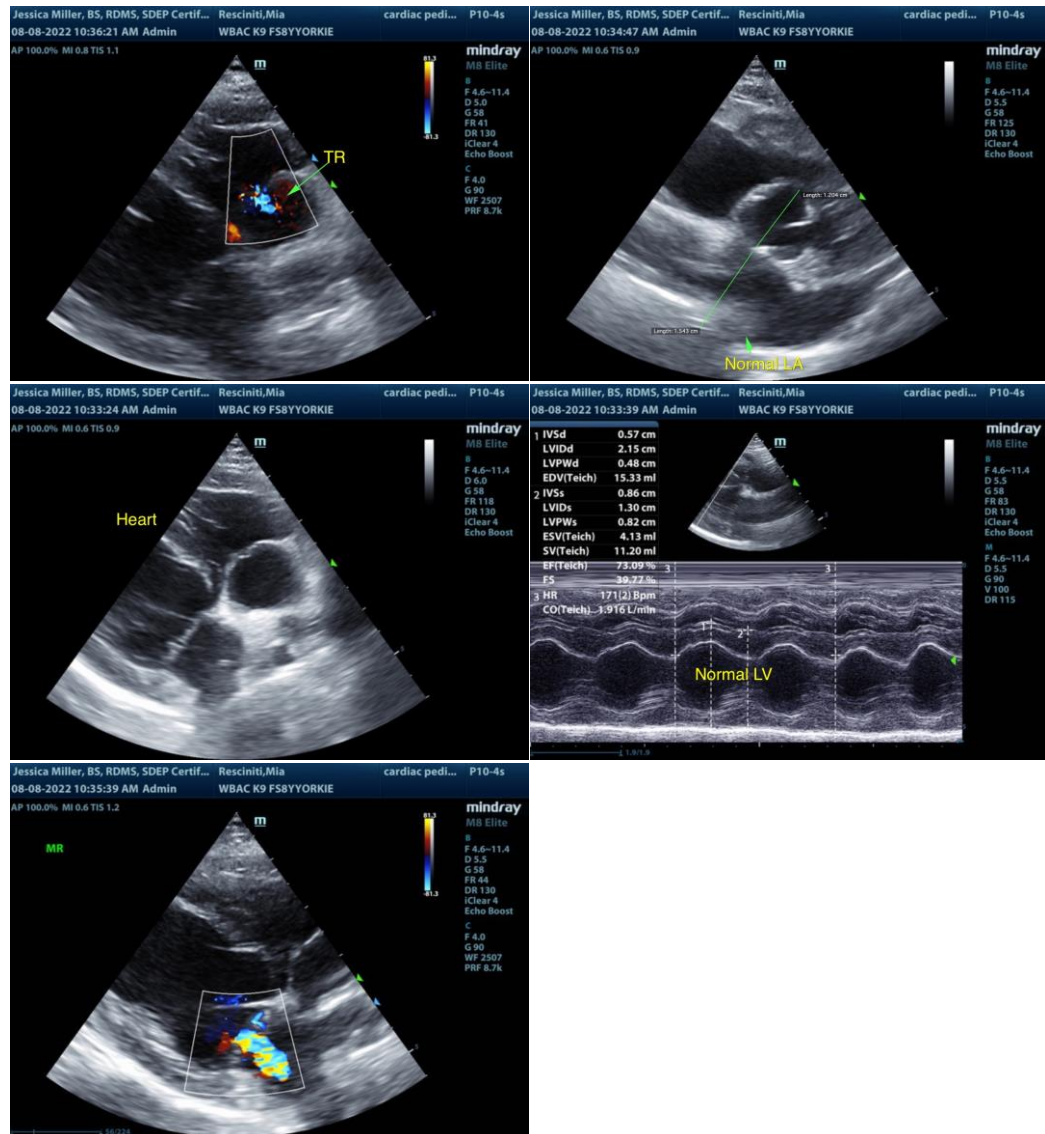
Dr. Palescandolo

INVOICE

11317ag

DATE

08/08/2022





PATIENT

Mia Resciniti

SPECIES

Canine

BREED

Yorkie

SEX

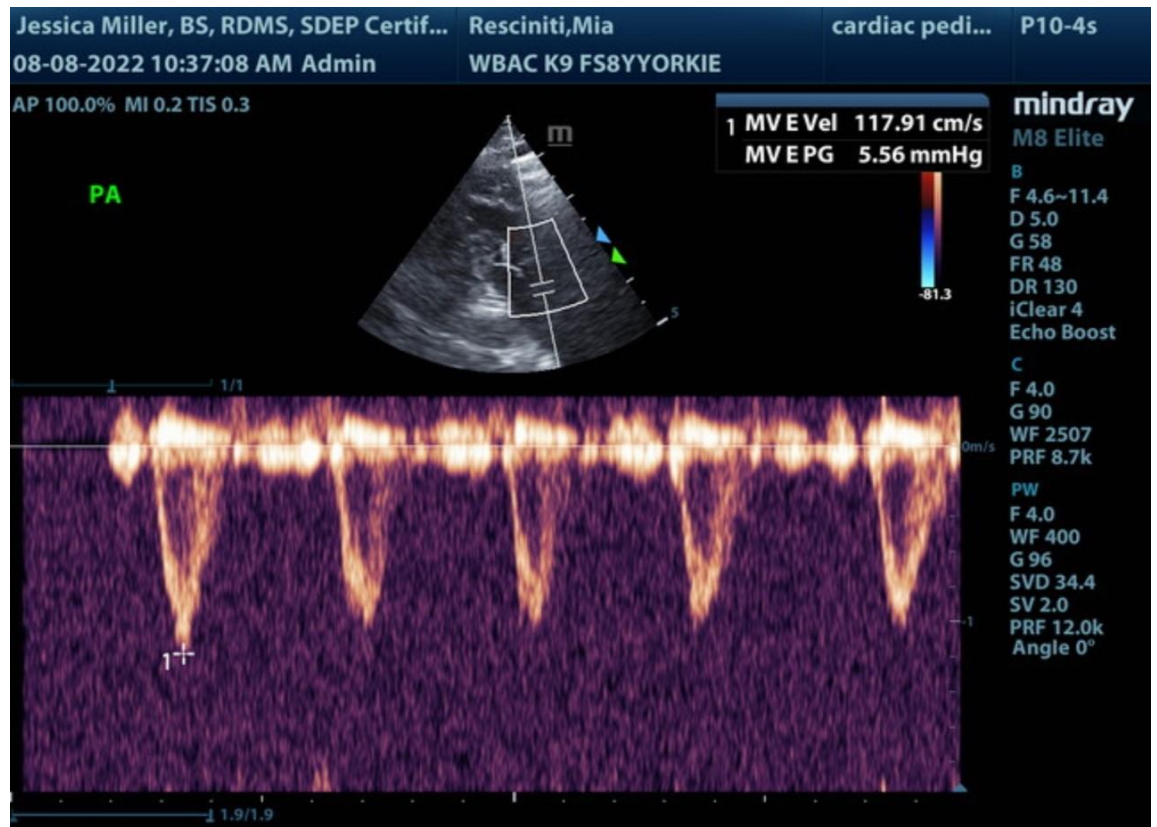
FS

AGE

8yr

WEIGHT

8lb



INTERPRETED BY

R. McKenzie Daniel,
DVM, DABVP
(Canine and Feline)

IMAGING PERFORMED BY

Jessica Miller

HOSPITAL NAME

Willowbrook AC

REFERRING VET

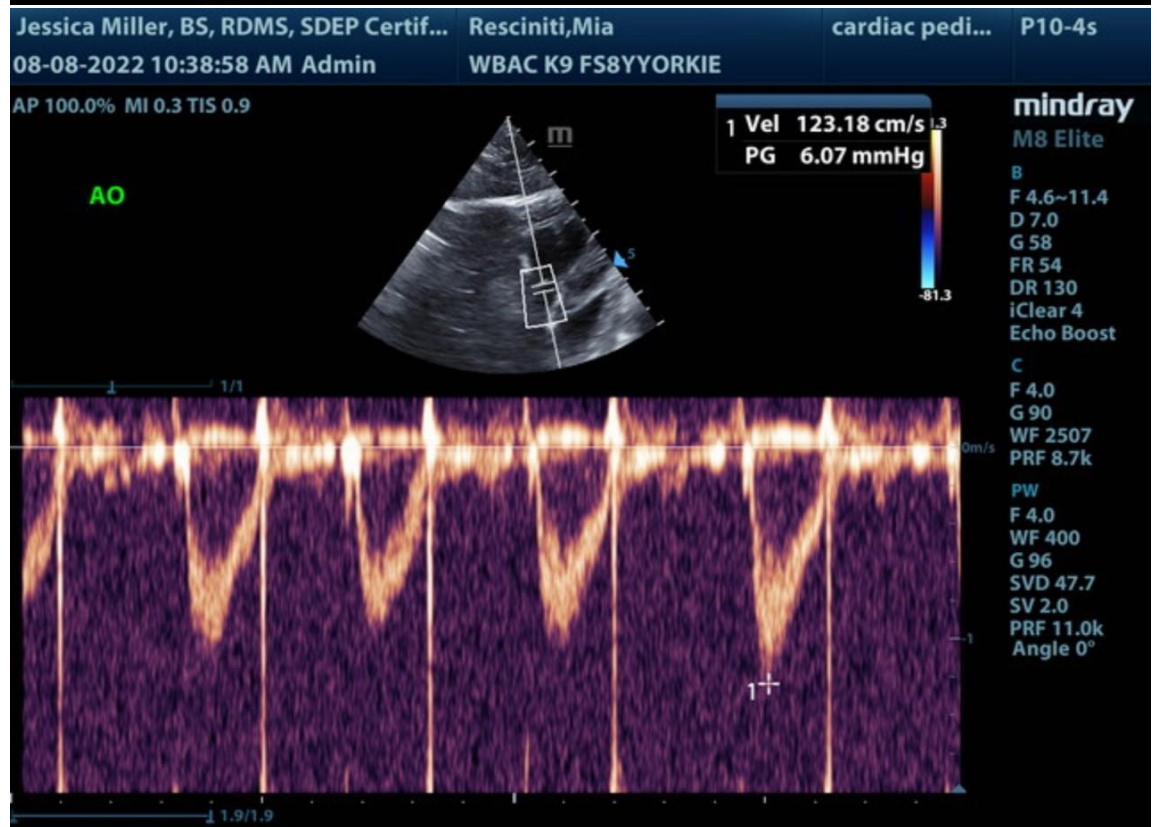
Dr. Palescandolo

INVOICE

11317ag

DATE

08/08/2022





PATIENT

Mia Resciniti

The information and recommendations provided are based on the images presented by the referring veterinarian/sonographer. No evaluation can be communicated regarding pathology that was not visible in the image/video clips provided.

SPECIES

Canine

Thank you for this referral. If the clinical or image interpretation does not parallel your findings or if I can be of any further assistance please contact me.

R. McKenzie Daniel, DVM, DABVP (Canine / Feline Practice)

BREED

Yorkie

info@SonoPath.com

SEX

FS

AGE

8yr

WEIGHT

8lb

INTERPRETED BY

R. McKenzie Daniel,
DVM, DABVP
(Canine and Feline)

**IMAGING
PERFORMED BY**

Jessica Miller

HOSPITAL NAME

Willowbrook AC

REFERRING VET

Dr. Palescandolo

INVOICE

11317ag

DATE

08/08/2022