



**PATIENT PRESENTING CLINICAL SIGNS**

Persephone McAllister

History: PE 07/29/22 findings: Acute elevation in ALT: toxin exposure (NSAIDs, ant bait), leptospirosis, ascending bacterial cholangiohepatitis, neoplasia unlikely, Cushing's less likely given ALT > ALP, liver function ok >> should not be seizing or PU/PD due to hepatopathy, USG is not low enough to be diabetes insipidus Recommended additional diagnostics -- AUS to rule out cancer, biliary mucocele PE 07/15/22 Findings: Distended abdomen - Suspect hepatomegaly, Very elevated ALT/ALP: r/o hepatitis, hepatopathy, HAC, Lepto, other viral/bacterial infection, neoplasia, other Elevated globulins, Abdominal palpation Soft - Non-painful, no organomegaly, masses, or fluid wave appreciated

**SPECIES**

Canine

**BREED**

Mixed

**SEX**

FS

**AGE**

7yr

**WEIGHT**

43.6lb

Abnormal PE/Chem/CBC/UA Results: Current Medications Gabapentin, keppra

**ULTRASONOGRAPHIC EXAMINATION OF THE ABDOMEN**

**Urinary System**

The urinary bladder was mildly distended in size. The trigone, cystourethral junction, and visible pelvic urethra to a depth of 2 cm exhibited normal thickness and tone. Anechoic urine was present in the lumen with no uroliths or sediment. The ureteral papillae were normal. The ureters were not visible which is normal. No evidence of inflammatory or neoplastic changes were noted.

Normal size and margination were present in the kidneys. A normal 1:3 cortex / medulla ratio and mild indistinct corticomedullary border were present. Pinpoint areas of medullary mineral were noted. No evidence of pyelectasia or retroperitoneal inflammation. The left kidney measured 6.7 cm in length. The right kidney measured 6.7 cm in length.

The area of the aortic trifurcation was free of pathology.

**Adrenal Glands**

The left adrenal gland was uniform in size and contour with a uniformly hypoechoic parenchyma. The left adrenal gland measured 0.87 cm width at the caudal pole and 2.7 cm length. No overt pathology in the area of the right adrenal gland.

**Spleen**

The spleen exhibited subjective mild to moderate generalized enlargement with symmetrical capsule contour and a finely textured and homogenous parenchyma. The splenic vasculature at the hilus was normal in volume with no evidence of congestion or thrombosis. Acute to chronic inflammatory, neoplastic, or benign parenchyma changes were not noted.

**Liver**

The discernable liver exhibited normal parenchyma echogenicity with mild to moderate coarse echotexture. The hepatic and portal vasculature were normal in appearance without signs of congestion. The gallbladder was non-distended in size with thin walls and primarily anechoic luminal content with very minor hyperechoic luminal debris. The cystic and common bile ducts were normal.

**Gastrointestinal**

The stomach presented intact wall layering with a normal wall layer ratio. The lumen of the stomach was empty with no signs of ileus, obstruction or foreign material.

**INTERPRETED BY**

R. McKenzie Daniel,  
DVM, DABVP  
(Canine and Feline)

**IMAGING PERFORMED BY**

Sara Hansen

**HOSPITAL NAME**

Vca Westmoreland

**REFERRING VET**

Dr. Baxter

**INVOICE**

11286ag

**DATE**

08/05/2022



**PATIENT**

Persephone McAllister

The small intestine presented intact wall layering with 1:3 muscularis/mucosa ratio. The lumen of the small intestine was empty with no signs of ileus, obstruction or foreign material.

Normal visible colon wall layers were present with apparent formed feces in lumen.

**SPECIES**

Canine

**Pancreas**

The parenchyma of the left limb, body and right limb of the pancreas presented isoechoic to the adjacent omental fat. A normal curvilinear capsule contour of the pancreas was present. The visible pancreatic duct was normal. No signs of active inflammation or neoplastic disease was evident.

**BREED**

Mixed

**Free Abdomen**

**SEX**

FS

No overt lymphadenopathy or peritoneal effusion was present.

**AGE**

7yr

A large nonhomogeneous cystic appearing mass was present in the cranial abdomen directly adjacent to the mid to left liver as well as the cranial aspect of the spleen measuring approximately 12-13 cm in diameter.

Rapid view of the heart revealed no evidence of pericardial masses or effusion in the visible window.

**WEIGHT**

43.6lb

**ULTRASONOGRAPHIC FINDINGS**

- A large nonhomogeneous mass in the cranial abdomen-suspect hepatic origin-cystic biliary adenoma, adenocarcinoma or other
- Splenomegaly-nonspecific
- Mild loss of renal corticomedullary border distinction

**INTERPRETED BY**

R. McKenzie Daniel,  
DVM, DABVP  
(Canine and Feline)

**INTERPRETATION OF THE FINDINGS & FURTHER RECOMMENDATIONS**

Given the size of the cranial abdominal mass potential for splenic origin cannot be definitively excluded yet hepatic origin is suspected. Potential for concurrent acute on chronic hepatopathy.

Assuming normal clotting status an ultrasound guided FNA of the mass using a 25g needle could be considered for screening cytology as well as a hepatosplenic FNA if accessible. Leptospirosis titers/PCR are recommended if endemic to the area. Three view chest radiographs are recommended. An abdominal CT is likely ideal for further assessment and surgical planning.

**IMAGING PERFORMED BY**

Sara Hansen

**HOSPITAL NAME**

Vca Westmoreland

**REFERRING VET**

Dr. Baxter

**INVOICE**

11286ag

**DATE**

08/05/2022



**PATIENT**

Persephone McAllister

**SPECIES**

Canine

**BREED**

Mixed

**SEX**

FS

**AGE**

7yr

**WEIGHT**

43.6lb

**INTERPRETED BY**

R. McKenzie Daniel,  
DVM, DABVP  
(Canine and Feline)

**IMAGING PERFORMED BY**

Sara Hansen

**HOSPITAL NAME**

Vca Westmoreland

**REFERRING VET**

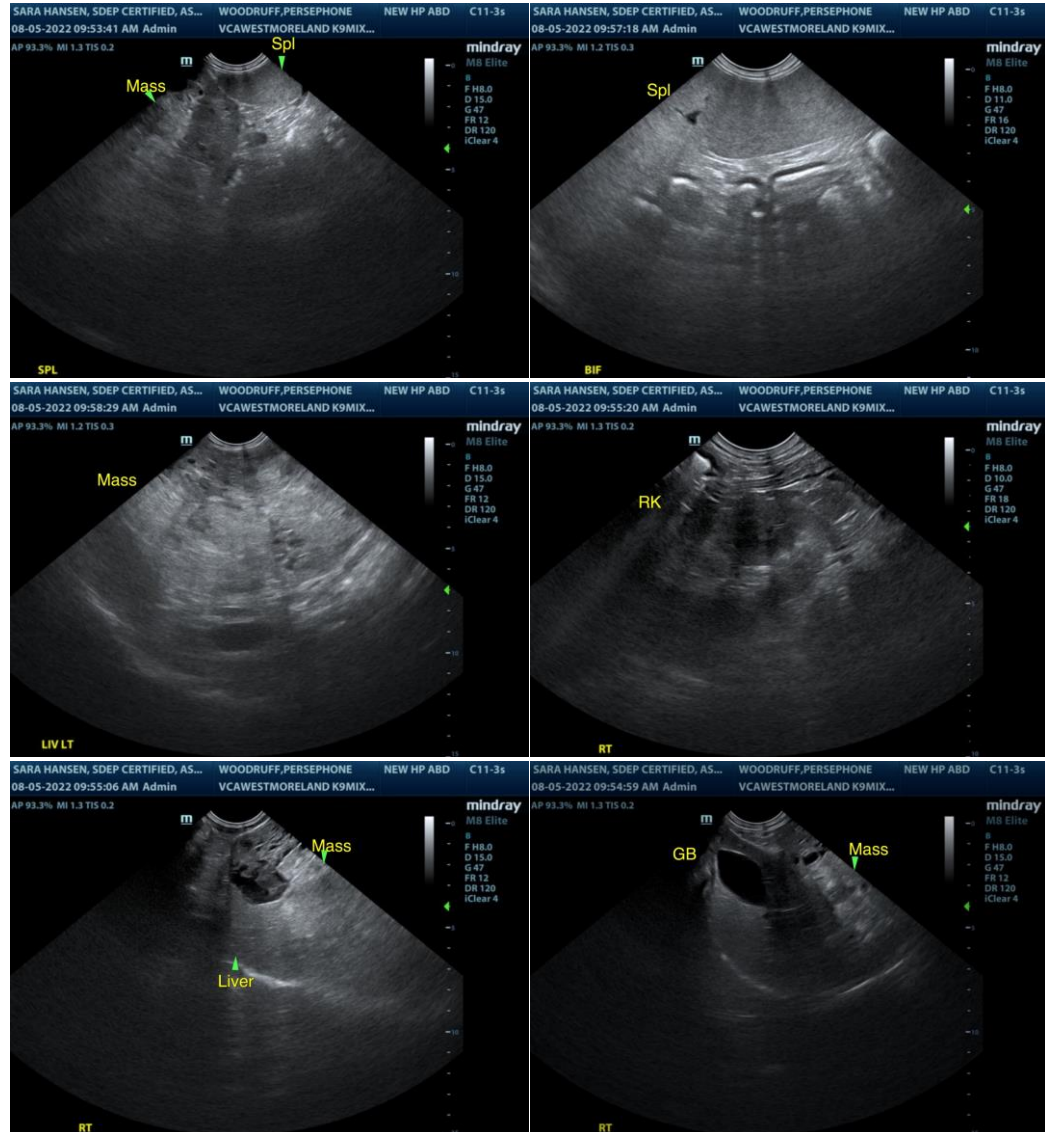
Dr. Baxter

**INVOICE**

11286ag

**DATE**

08/05/2022





**PATIENT**

Persephone McAllister

**SPECIES**

Canine

**BREED**

Mixed

**SEX**

FS

**AGE**

7yr

**WEIGHT**

43.6lb

**INTERPRETED BY**

R. McKenzie Daniel,  
DVM, DABVP  
(Canine and Feline)

**IMAGING PERFORMED BY**

Sara Hansen

**HOSPITAL NAME**

Vca Westmoreland

**REFERRING VET**

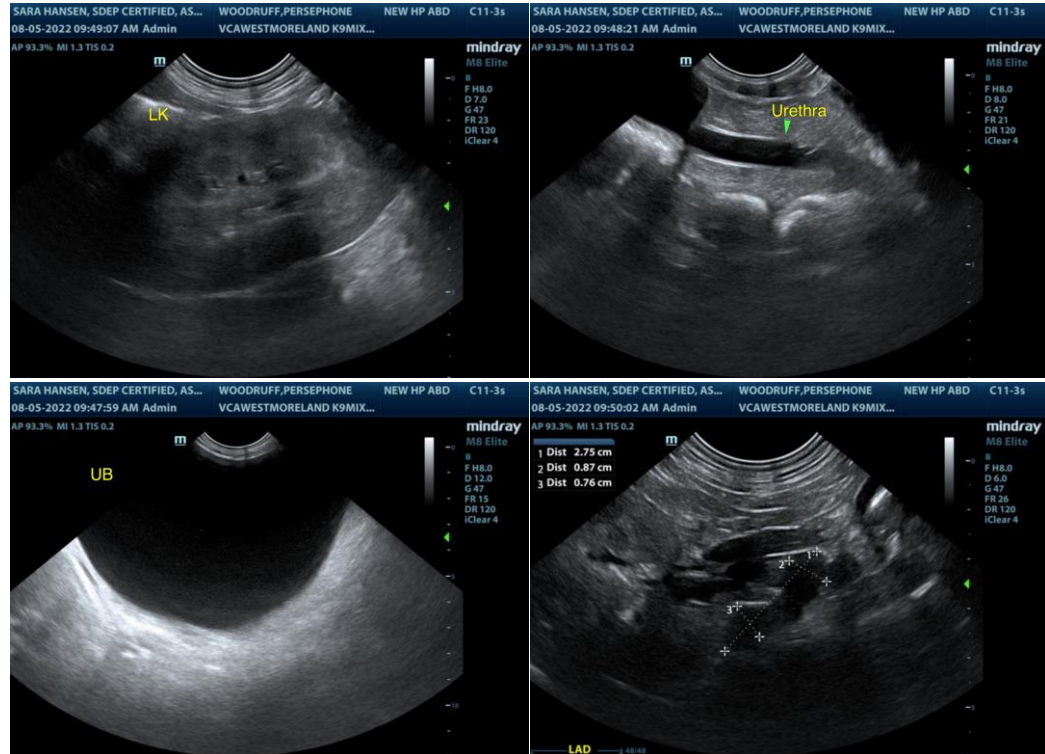
Dr. Baxter

**INVOICE**

11286ag

**DATE**

08/05/2022



The information and recommendations provided are based on the images presented by the referring veterinarian/sonographer. No evaluation can be communicated regarding pathology that was not visible in the image/video clips provided.

Thank you for this referral. If the clinical or image interpretation does not parallel your findings or if I can be of any further assistance please contact me.

R. McKenzie Daniel, DVM, DABVP (Canine / Feline Practice)

info@SonoPath.com