

**PATIENT**

Ruby Flaherty

SPECIES

Canine

BREED

Boxer

SEX

FS

AGE

11 Yr

WEIGHT

64.4 lbs.

INTERPRETED BYR. McKenzie Daniel,
DVM, DABVP (Canine
and Feline)**IMAGING
PERFORMED BY**

Rachel Runnells, RVT

HOSPITAL NAME

SVS Imaging KC

REFERRING VET

Dr. Elizabeth Wilcox

INVOICE

14504

DATE

8/4/22

PRESENTING CLINICAL SIGNS

PU/PD, anorexia, lethargy, and vomiting. Years ago had a MCT removed on ear (removed ear flap). .
 Abnormal PE/Chem/CBC/UA Results: Painful abdomen or back. Labs mostly normal.

ULTRASONOGRAPHIC EXAMINATION OF THE ABDOMEN**Urinary System**

The urinary bladder, trigone, cystourethral junction, and visible pelvic urethra to a depth of 2.0 cm exhibited overtly normal thickness and tone. Anechoic urine was present in the lumen with no uroliths or sediment. The ureteral papillae were normal. The ureters were not visible which is normal. No evidence of inflammatory or neoplastic changes was noted.

The area of the aortic trifurcation was free of pathology.

Normal size and margination were present in the kidneys. A normal 1:3 cortex / medulla ratio was maintained. The medulla and cortices were uniform in texture with some increased echogenicity and mild to moderate loss of corticomedullary symmetry and definition expected for the age of the patient. No evidence of pelvic dilation was present. The left kidney measured 6.8 cm in length. The right kidney measured 7.2 cm in length.

Adrenal Glands

The bilateral adrenal glands were normal in size. Mild parenchyma heterogeneity and mild capsule asymmetry was present without suspicion for overt neoplasia. The left adrenal gland measured 0.68 cm width in the cranial pole and 0.77 cm width in the caudal pole. The right adrenal gland measured 0.77 cm width in the cranial pole and 0.87 cm width in the caudal pole.

Spleen

The spleen exhibited primarily finely textured parenchyma which was hyperechoic to the liver and renal cortical parenchyma. Mild generalized parenchyma heterogeneity was present without evidence of nodular changes. The capsule was smooth and regular without apparent expansion. The splenic vasculature at the hilus was normal in volume with no evidence of congestion or thrombosis. The parenchymal heterogeneity is likely consistent with benign changes such as extramedullary hematopoiesis or age-related remodeling with minor potential for inflammatory or neoplastic disease.

Liver/ Gallbladder

The liver was subjectively normal in size, structure, and contour. The liver parenchyma was mildly nonuniform and hypoechoic to the spleen with a moderate coarse echotexture and subjective mild to benign parenchymal remodeling. The hepatic and portal vasculature were normal in appearance without signs of congestion. The gallbladder was non-distended in size with primarily dependent, nonorganized, mildly hyperechoic gallbladder debris. The gallbladder and common bile duct was normal.

Gastrointestinal

The stomach presented intact yet mildly thickened wall layering with a normal wall layer ratio. The lumen of the stomach contained a mild to moderate amount of retained echogenic fluid and non-shadowing chyme. No obvious evidence of obstructive pyloric mural pathology was noted.

**PATIENT**

Ruby Flaherty

SPECIES

Canine

BREED

Boxer

SEX

FS

AGE

11 Yr

WEIGHT

64.4 lbs.

The small intestine exhibited primarily intact yet thickened wall layering owing to propensity for generalized prominent mucosa and mildly prominent submucosa layers. A segment of small intestine suspected to be in the distal small intestine, likely distal jejunum and ileum exhibited moderate yet variable mural hypertrophy exhibiting decreased mural echogenicity and loss of discernable wall layering to the approximate level of the ileocolic junction. Intact jejunal wall width measured 0.5 cm. The segmental intestine exhibited decreased mural echogenicity and loss of discernable wall layering measured up to 0.8 cm wall width.

The colon exhibited intact and overtly normal wall layering. The colon exhibited moderate yet variable distention with non-formed fecal matter. The descending colon wall width measured 0.2 cm.

Pancreas

The parenchyma of the left limb, body, and right limb of the pancreas presented isoechoic to the adjacent omental fat. A normal curvilinear capsule contour of the pancreas was present. The visible pancreatic duct was normal. No signs of active inflammation or neoplastic disease were evident.

Free Abdomen

Multiple, variably sized, hypoechoic, mesenteric lymph nodes were present. The lymph nodes exhibited symmetrical to rounded margination with abnormal width: length ratio (>0.5). The enlarged lymph nodes were bordered by echogenic to reactive mesentery. The largest of the mesenteric lymph nodes measured 5.1 cm x 2.6 cm. Perilymphatic to peri intestinal hyperechoic mesentery was noted. Small pockets of scant perilymphatic and peri intestinal free fluid were present.

ULTRASONOGRAPHIC FINDINGS***Primary Findings***

- Generalized thickened gastrointestinal tract exhibiting mild gastric hypomotility, segmental intestinal decreased mural echogenicity, and loss of discernable wall layering, likely distal jejunum and ileum
- Hypoechoic to swollen mesenteric lymphadenopathy
- Perilymphatic and peri intestinal hyperechoic mesentery, scant associated free fluid

Secondary Findings

- Bilateral chronic renal changes
- Mild hepatic parenchymal remodeling
- Mild gallbladder debris (non-mucocele)

INTERPRETATION OF THE FINDINGS & FURTHER RECOMMENDATIONS

The enlarged mesenteric lymph nodes meet neoplastic criteria which is of primary concern. Likewise, concurrent segmental to generalized infiltrative intestinal neoplasia is considered a primary differential diagnosis. Significant segmental to generalized Inflammatory enteropathy with associated significant mesenteric lymphadenitis is also possible.

Assuming normal clotting status, ultrasound-guided FNA of an enlarged mesenteric lymph node for screening cytology is recommended. Intestinal and lymphatic biopsies may be required for a

INTERPRETED BYR. McKenzie Daniel,
DVM, DABVP (Canine
and Feline)**IMAGING
PERFORMED BY**

Rachel Runnells, RVT

HOSPITAL NAME

SVS Imaging KC

REFERRING VET

Dr. Elizabeth Wilcox

INVOICE

14504

DATE

8/4/22



PATIENT

Ruby Flaherty

definitive diagnosis. A very guarded prognosis pending sampling, which is considered essential in this case. Empirically, continued as-needed gastrointestinal support is recommended.

SPECIES

Canine

BREED

Boxer

SEX

FS

AGE

11 Yr

WEIGHT

64.4 lbs.

INTERPRETED BY

R. McKenzie Daniel,
DVM, DABVP (Canine
and Feline)

**IMAGING
PERFORMED BY**

Rachel Runnells, RVT

HOSPITAL NAME

SVS Imaging KC

REFERRING VET

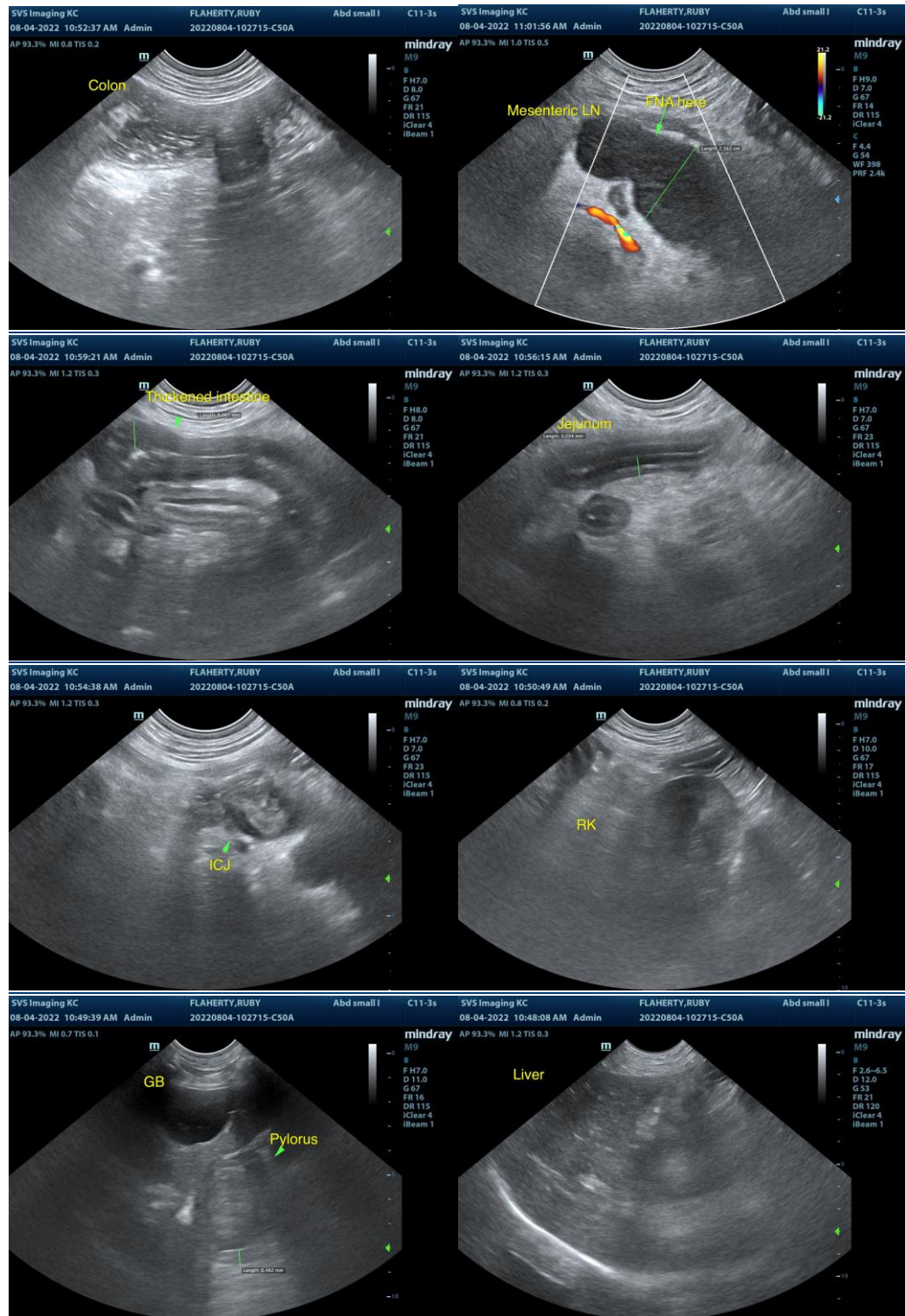
Dr. Elizabeth Wilcox

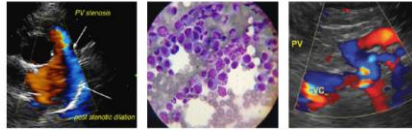
INVOICE

14504

DATE

8/4/22





PATIENT

Ruby Flaherty

SPECIES

Canine

BREED

Boxer

SEX

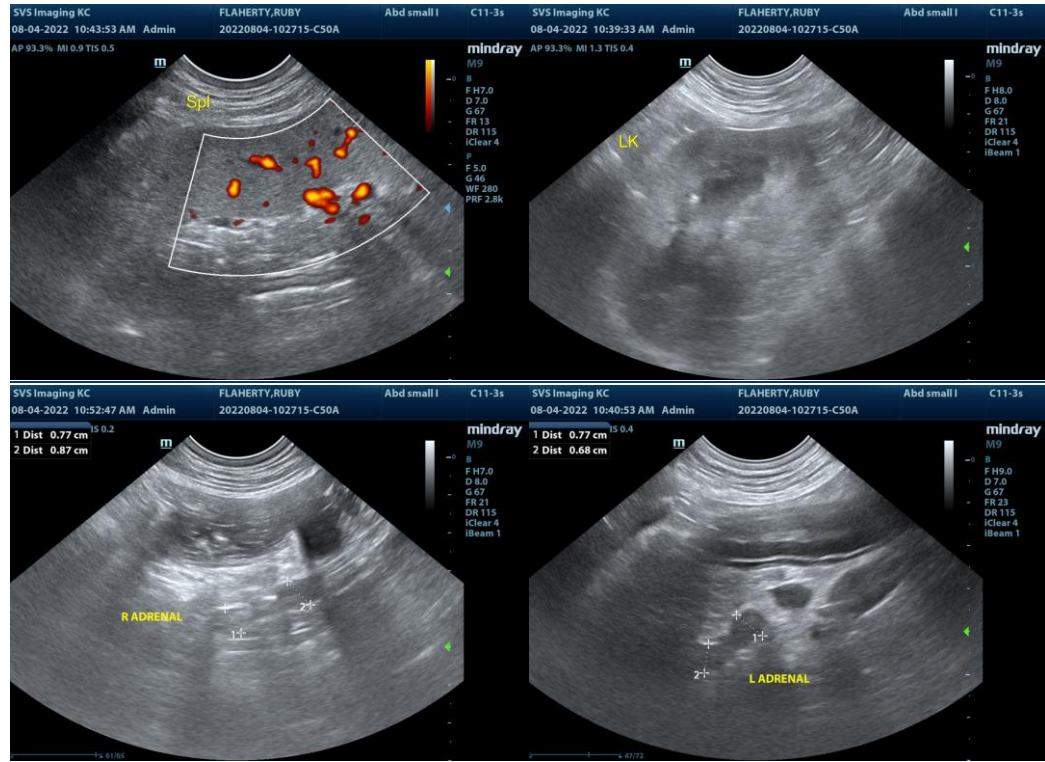
FS

AGE

11 Yr

WEIGHT

64.4 lbs.



INTERPRETED BY

R. McKenzie Daniel, DVM, DABVP (Canine and Feline)

IMAGING PERFORMED BY

Rachel Runnells, RVT

HOSPITAL NAME

SVS Imaging KC

REFERRING VET

Dr. Elizabeth Wilcox

INVOICE

14504

DATE

8/4/22

The information and recommendations provided are based on the images presented by the referring veterinarian/sonographer. No evaluation can be communicated regarding pathology that was not visible in the image/video clips provided.

Thank you for this referral. If the clinical or image interpretation does not parallel your findings or if I can be of any further assistance please contact me.

R. McKenzie Daniel, DVM, DABVP (Canine / Feline Practice)
info@SonoPath.com