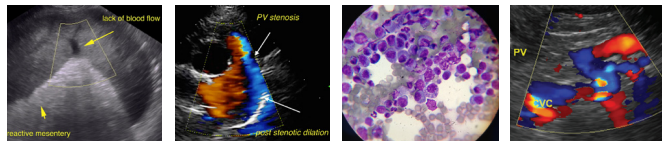


<b>PATIENT</b>	<b>PRESENTING CLINICAL SIGNS</b>
Millie Bloomfield	V+, lethargic. Abnormal PE/Chem/CBC/UA Results: Elevated GGT, Lyme +
<b>SPECIES</b>	<b>ULTRASONOGRAPHIC EXAMINATION OF THE ABDOMEN</b>
Canine	<b>Urinary System</b>
<b>BREED</b>	The urinary bladder, trigone, cystourethral junction, and visible pelvic urethra to a depth of 3.0 cm exhibited normal thickness and tone. Anechoic urine was present in the lumen with no uroliths or sediment. The ureteral papillae were normal. The ureters were not visible which is normal. No evidence of inflammatory or neoplastic changes were noted.
Cattle Dog	
<b>SEX</b>	No evidence of pathology in the area of the uterus or bilateral ovaries.
Female	
<b>AGE</b>	Normal size and margination were present in the kidneys. A normal 1:3 cortex / medulla ratio and normal corticomedullary definition were maintained. The echogenicity of the cortex was similar to or slightly less than normal liver parenchyma while the medulla echogenicity was hypoechoic to the cortex with no evidence of pelvic dilation. The left kidney measured 6.7 cm. The right kidney measured 7.3 cm.
5 Years	The area of the aortic trifurcation was free of pathology.
<b>WEIGHT</b>	<b>Adrenal Glands</b>
78 Pounds	The adrenal glands were uniform in size and contour with a uniformly hypoechoic parenchyma. The left adrenal gland measured 2.3 cm length x 0.59 cm at the caudal pole. The right adrenal gland measured 2.7 cm length x 0.72 cm at the caudal pole.
<b>INTERPRETED BY</b>	<b>Spleen</b>
R. McKenzie Daniel, DVM, DABVP (Canine and Feline)	The spleen exhibited a finely textured and homogenous parenchyma which was hyperechoic to the liver and renal cortical parenchyma. The capsule was smooth and regular without apparent expansion. The splenic vasculature at the hilus was normal in volume with no evidence of congestion or thrombosis. Acute to chronic inflammatory, neoplastic, or benign parenchyma changes were not noted.
<b>IMAGING PERFORMED BY</b>	<b>Liver</b>
Shari Reffi, CVT	The liver was subjectively normal in size, structure, and contour. The liver parenchyma was uniform and hypoechoic to the spleen with a mild coarse echotexture. The hepatic and portal vasculature were normal in appearance without signs of congestion. The gallbladder was non distended in size with mild, echogenic, nonmineralized biliary sludge. The cystic duct and common bile ducts were normal without evidence of dilation.
<b>HOSPITAL NAME</b>	<b>Gastrointestinal</b>
Rockaway AH	The stomach presented intact wall layering with a normal wall layer ratio. The lumen of the stomach contained primarily echogenic ingesta with areas of subtle progressive distal acoustic shadowing. The ingesta extended into the area of the pylorus without evidence of mechanical pyloric outflow obstruction. Pylorus wall measured 0.60 cm. Gastric body wall measured 0.36 cm.
<b>REFERRING VET</b>	
Dr. Maniar	
<b>INVOICE</b>	
25087	The small intestine presented intact wall layering with 1:3 muscularis/mucosa ratio. No evidence of mechanical small intestinal ileus, obstruction or foreign material. Jejunum wall measured 0.41 cm.
<b>DATE</b>	Normal visible colon wall layers were present with apparent formed feces in lumen.
8/31/21	



**PATIENT**

**Pancreas**

Millie Bloomfield

The parenchyma of the left limb, body and right limb of the pancreas presented isoechoic to the adjacent omental fat. A normal curvilinear capsule contour of the pancreas was present. The visible pancreatic duct was normal. No signs of active inflammation or neoplastic disease was evident.

**SPECIES**

Canine

**ULTRASONOGRAPHIC FINDINGS**

**BREED**

Cattle Dog

- Gastric ingesta
- Sonographically unremarkable small bowel – no evidence of mechanical ileus or foreign material.
- Mild gallbladder debris

**SEX**

Female

The presence of gastric ingesta is nonspecific and may indicate post-prandial presentation. Correlation with most recent meal ingestion is suggested. However, given the patient’s reported vomiting, and assuming NPO, the presence of gastric ingesta may indicate some degree of gastric stasis or hypomotility. Subjectively, the ingesta was most suggestive of food without evidence of overt foreign material. However, technically the possibility of intermixed mild foreign material within the ingesta cannot be excluded.

**AGE**

5 Years

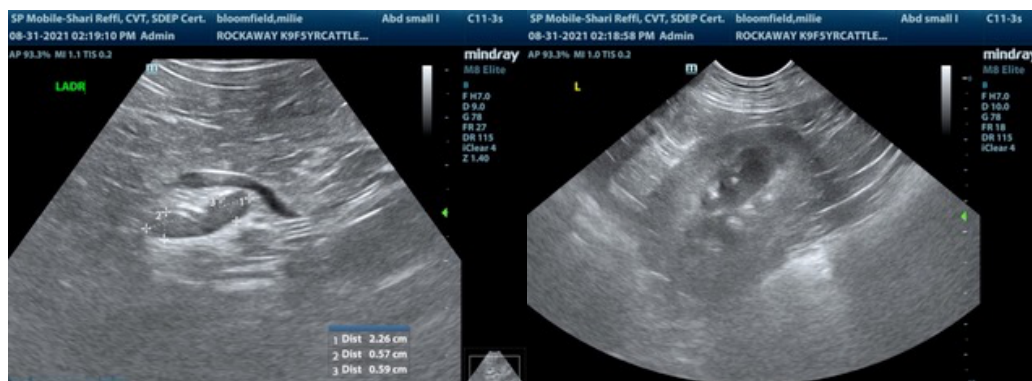
Hospitalization with 24 hour IV fluid and supportive care with either radiographic or sonographic monitoring for evidence of normal gastric emptying recommended. No evidence of post-hepatic stasis or obstruction. Baseline urine protein/creatinine ratio may be considered if not recently done.

**WEIGHT**

78 Pounds

**INTERPRETED BY**

R. McKenzie Daniel,  
DVM, DABVP  
(Canine and Feline)

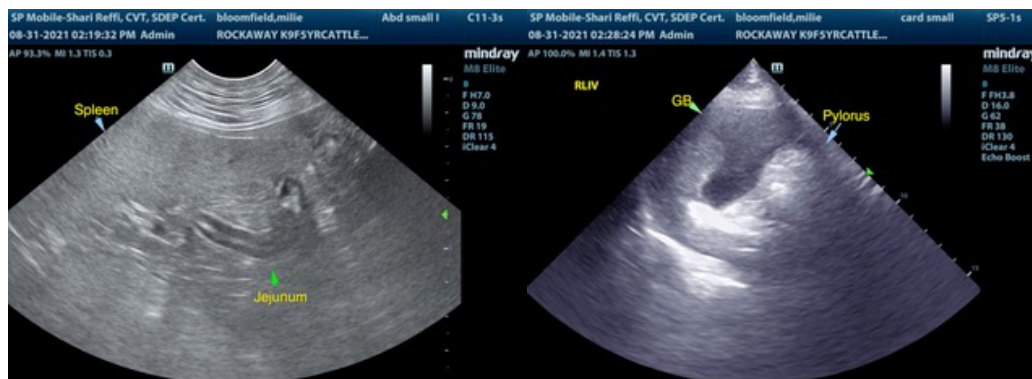


**IMAGING PERFORMED BY**

Shari Reffi, CVT

**HOSPITAL NAME**

Rockaway AH



**REFERRING VET**

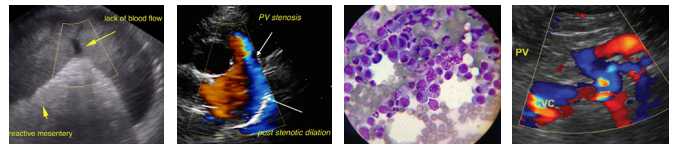
Dr. Maniar

**INVOICE**

25087

**DATE**

8/31/21



**PATIENT**

Millie Bloomfield

**SPECIES**

Canine

**BREED**

Cattle Dog

**SEX**

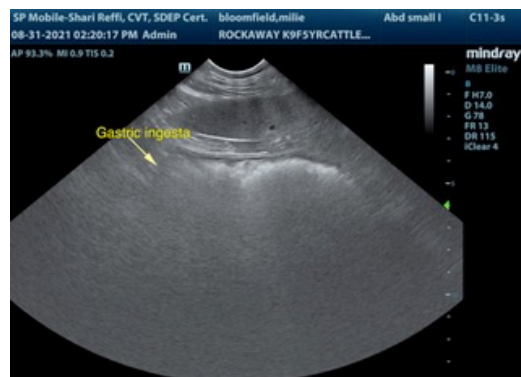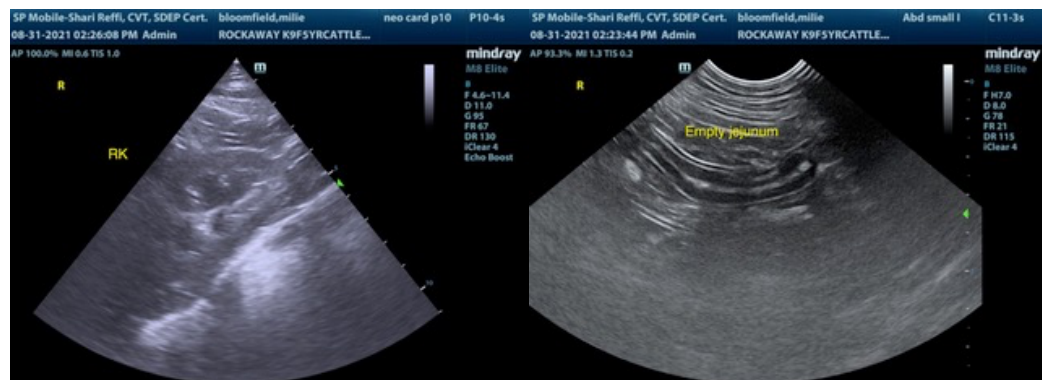
Female

**AGE**

5 Years

**WEIGHT**

78 Pounds



**INTERPRETED BY**

R. McKenzie Daniel,  
DVM, DABVP  
(Canine and Feline)

**IMAGING PERFORMED BY**

Shari Reffi, CVT

**HOSPITAL NAME**

Rockaway AH

**REFERRING VET**

Dr. Maniar

**INVOICE**

25087

**DATE**

8/31/21

The information and recommendations provided are based on the images presented by the referring veterinarian. No evaluation can be communicated regarding pathology that was not visible in the image/video clips provided.

Thank you for this referral. If the clinical or image interpretation does not parallel your findings or if I can be of any further assistance please contact me.

R. McKenzie Daniel, DVM, DABVP (Canine / Feline Practice)  
info@SonoPath.com