



PATIENT

Poseidon Arguin

SPECIES

Feline

BREED

Schinx

SEX

MN

AGE

5 YO

WEIGHT

11 lbs.

INTERPRETED BY

R. McKenzie Daniel,
DVM, DABVP
(Canine and Feline)

IMAGING PERFORMED BY

Dr. Meredith Swart

HOSPITAL NAME

Swart Veterinary
Imaging

REFERRING VET

Dr. Meredith Swart

INVOICE

14757

DATE

8/30/22

PRESENTING CLINICAL SIGNS

Patient was fractious so received injectable ace/ketamine prior to echo. No clinical signs of heart disease. Echo is for screening as patient was recently neutered and is now breeders pet. No murmur. Abnormal PE/Chem/CBC/UA Results: none reported

ULTRASONOGRAPHIC EXAMINATION OF THE HEART

FELINE CARDIAC PARAMETERS	BODY WEIGHT (kg)	HR (BPM)	IVSd (cm)	LVIDd (cm)	LVWd (cm)	FS (%)	EF (%)
NORMAL PARAMETER	-----	150-240	0.3-0.6	1.0-2.1	0.25-0.6	35-67	80-100
PATIENT		NM	0.44	1.6	0.43	53.1	94
FELINE CARDIAC PARAMETERS	LA/AO (Boon)	LA/AO HEART BASE (Sisson)	LA 2D 4-chamber long axis AS to FW (Sisson) (cm)		LVOT VEL. (m/s)	RVOT VEL. (m/s)	IVRT (m/)
NORMAL PARAMETER	<1.5	0.88-1.79	0.7-1.7		<1.6	<1.3	40-60
PATIENT		1.5	1.2		1.0	1.0	NM
Adapted from June Boon, Veterinary Echocardiography, 1998							
Sisson D et al. JVIM 1991; 5: 232, Jacobs et al. Am J Vet Res 1985; 46:1705							

Cardiac Presentation

The echocardiogram in this patient demonstrated normal **left atrial** size based on 3 separate LA measurements. The cranial and caudal **mitral** valve leaflets presented normal linear structure and kinetics. The **left ventricle** presented normal thicknesses with linear contour and was not dilated nor restricted. The **myocardium** presented normal echogenicity without subjective evidence of significant fibrotic or ischemic disease. **Contractility** of the ventricular walls was adequate and in normal range for this patient evidenced by the fractional shortening measurement and subjective evaluation of the different regions and angles of the myocardium. The **left ventricular outflow** tract demonstrated normal laminar flow and subjective structural integrity. The **right atrium** and auricle revealed normal size, structure and content. No evidence of masses was noted or chamber overload. **Tricuspid** valvular assessment demonstrated adequate linear morphology and kinetics. The **right ventricle** was of normal size (1/3 diameter of LV), chordae structure, myocardial echogenicity and thickness. **Pulmonic** tract assessment revealed normal valve structure, laminar flow, and diameter (approx. 1:1 pa/ao ratio). No visible **pericardial** or free pleura fluid was noted or extra cardiac pathology in the visible planes. The cranial **mediastinum and pericardial regions** were free of masses in the visible window.

ULTRASONOGRAPHIC FINDINGS

- Normal echocardiogram



PATIENT

Poseidon Arguin

SPECIES

Feline

BREED

Schinx

SEX

MN

AGE

5 YO

WEIGHT

11 lbs.

INTERPRETED BY

R. McKenzie Daniel,
DVM, DABVP
(Canine and Feline)

IMAGING PERFORMED BY

Dr. Meredith Swart

HOSPITAL NAME

Swart Veterinary
Imaging

REFERRING VET

Dr. Meredith Swart

INVOICE

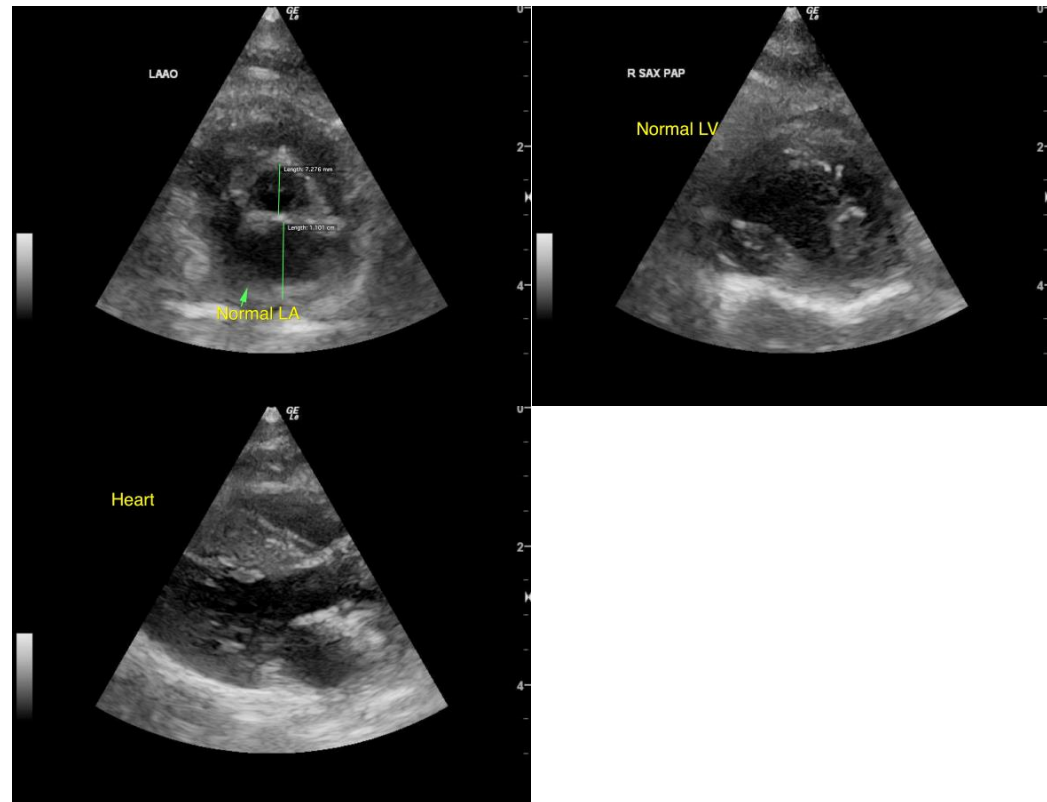
14757

DATE

8/30/22

INTERPRETATION OF THE FINDINGS & FURTHER RECOMMENDATIONS

No evidence of structural or functional cardiomyopathy was evident.



The information and recommendations provided are based on the images presented by the referring veterinarian/sonographer. No evaluation can be communicated regarding pathology that was not visible in the image/video clips provided.

Thank you for this referral. If the clinical or image interpretation does not parallel your findings or if I can be of any further assistance please contact me.

R. McKenzie Daniel, DVM, DABVP (Canine / Feline Practice)
info@SonoPath.com