SonoPath
Clinical Sonography & Telecytology
EDUCATIONAL TELECONSULTATION SERVICES™

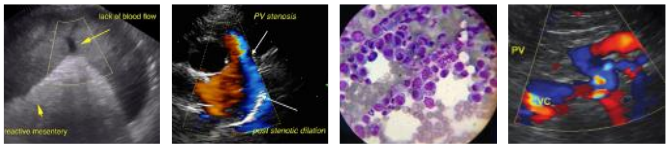

SonoPath.com™
1-800-838-4268 info@sonopath.com

PATIENT
Buddy Rather

SPECIES
Canine

BREED
Golden Retriever

SEX
MN

AGE
13

WEIGHT
34 kg

INTERPRETED BY
R. McKenzie Daniel, DVM, DABVP (Canine and Feline)

IMAGING PERFORMED BY
Dr. Belan

HOSPITAL NAME
Bowmont AH

REFERRING VET
Dr. Asemadahun

INVOICE
14761

DATE
8/30/22

PRESENTING CLINICAL SIGNS

Long term NSAID use non clinical for GI disease
Abnormal PE/Chem/CBC/UA Results: Moderate elevation of liver enzymes

ULTRASONOGRAPHIC EXAMINATION OF THE ABDOMEN

Urinary System

The urinary bladder, trigone, cystourethral junction, and visible pelvic urethra to a depth of 3.0 cm exhibited normal thickness and tone. Anechoic urine was present in the lumen with no uroliths or sediment. The ureteral papillae were normal. The ureters were not visible which is normal. No evidence of inflammatory or neoplastic changes was noted.

No evidence of pathology was noted associated with the residual prostate.

The area of the aortic trifurcation was free of pathology.

Normal size and margination were present in the kidneys. A normal 1:3 cortex / medulla ratio was maintained. The medulla and cortices were uniform in texture with some increased echogenicity and mild loss of corticomedullary symmetry and definition expected for the age of the patient. No evidence of pelvic dilation was present. The left kidney measured 6.5 cm in length. The right kidney measured 6.9 cm in length.

Adrenal Glands

The left adrenal gland was uniform in size and contour with a uniformly hypoechoic parenchyma. The left adrenal gland measured 0.65 cm width at the caudal pole and 0.67 cm width at the cranial pole. The right adrenal gland was uniform in size and contour with a uniformly hypoechoic parenchyma. The right adrenal gland measured 0.66 cm width at the caudal pole and 0.71 cm width at the cranial pole.

Spleen

The spleen exhibited a finely textured and homogenous parenchyma which was hyperechoic to the liver and renal cortical parenchyma. The capsule was smooth and regular without apparent expansion. The splenic vasculature at the hilus was normal in volume with no evidence of congestion or thrombosis. Acute to chronic inflammatory, neoplastic, or benign parenchyma changes were not noted.

Liver/ Gallbladder

The liver exhibited generalized enlargement more prominent in the mid to left liver with subjective caudal expansion of the left liver lobes to the level of or potentially past the level of the gastric axis. Areas of uniform normoechoic hepatic parenchyma combined with regional nonuniform to indistinctly nodular hepatic parenchyma were present in the mid to right liver. Solitary intraparenchymal thinly-walled cyst containing anechoic fluid was present in the left liver. Uniform indistinct mass was present in the subjective caudal aspect of the left ventral liver exhibiting isoechoic echogenicity compared to adjacent hepatic parenchyma, measuring 4.1 cm diameter.

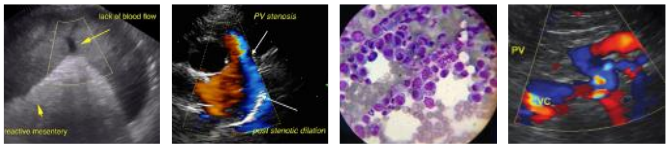

SonoPath.com™
1-800-838-4268 info@sonopath.com

PATIENT
Buddy Rather

SPECIES
Canine

BREED
Golden Retriever

SEX
MN

AGE
13

WEIGHT
34 kg

INTERPRETED BY
R. McKenzie Daniel, DVM, DABVP (Canine and Feline)

IMAGING PERFORMED BY
Dr. Belan

HOSPITAL NAME
Bowmont AH

REFERRING VET
Dr. Asemadahun

INVOICE
14761

DATE
8/30/22

The gallbladder was non-distended in size with sonographically normal gallbladder walls. No evidence of gallbladder inflammatory criteria was noted. Anechoic content was present primarily with minor echogenic luminal debris. No evidence of peripheral gallbladder inflammation was noted. The cystic and common bile ducts were normal.

Gastrointestinal

The stomach presented intact wall layering with a normal wall layer ratio. Mild nonshadowing ingesta / chyme was present.

The small intestine presented intact wall layering with 1:3 muscularis/mucosa ratio. The lumen of the small intestine was empty with no signs of ileus, obstruction, or foreign material.

Normal visible colon wall layers were present with apparent formed feces in lumen.

Pancreas

The pancreas was normal in size and contour with isoechoic to heterogeneous parenchyma compared to adjacent omentum. No signs of active inflammation or neoplasia.

Free Abdomen

No omental masses, lymphadenopathy, or evidence of peritoneal free fluid were noted.

ULTRASONOGRAPHIC FINDINGS

- Variable hepatomegaly exhibiting uniform to nonuniform indistinctly nodular parenchyma
- Suspect hepatoma-like mass caudal left liver
- Mild gallbladder debris (non-mucocele)
- Minor pancreatic remodeling - likely consistent with age-related pancreatic changes, incidental
- Mild chronic renal changes

INTERPRETATION OF THE FINDINGS & FURTHER RECOMMENDATIONS

The overall hepatomegaly and associated parenchymal changes were nonspecific with considerations including chronic vacuolar hepatopathy, inflammatory / immune-mediated disease, nodular to regenerative hyperplasia, hematopoiesis, potential areas of fibrosis, suspected hepatoma-like mass ventral caudal left liver, or other hepatopathy, with potential for malignant neoplasia.

Correlation with pending hepatic cytology is recommended. Hepatic core surgical biopsy Is likely required for a definitive histopathological diagnosis. Hepatosupportive medications including Denamarin and Ursodiol may prove beneficial. Overall hepatic functionality is suspected to be normal if normal albumin, glucose, BUN, and cholesterol levels.

SonoPath

Clinical Sonography & Telecytology

EDUCATIONAL TELECONSULTATION SERVICES™

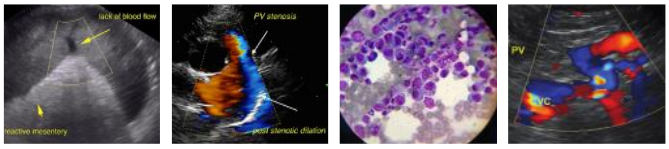

SonoPath.com™
1-800-838-4268 info@sonopath.com

PATIENT

Buddy Rather

SPECIES

Canine

BREED

Golden Retriever

SEX

MN

AGE

13

WEIGHT

34 kg

INTERPRETED BY

R. McKenzie Daniel, DVM, DABVP (Canine and Feline)

IMAGING PERFORMED BY

Dr. Belan

HOSPITAL NAME

Bowmont AH

REFERRING VET

Dr. Asemadahun

INVOICE

14761

DATE

8/30/22

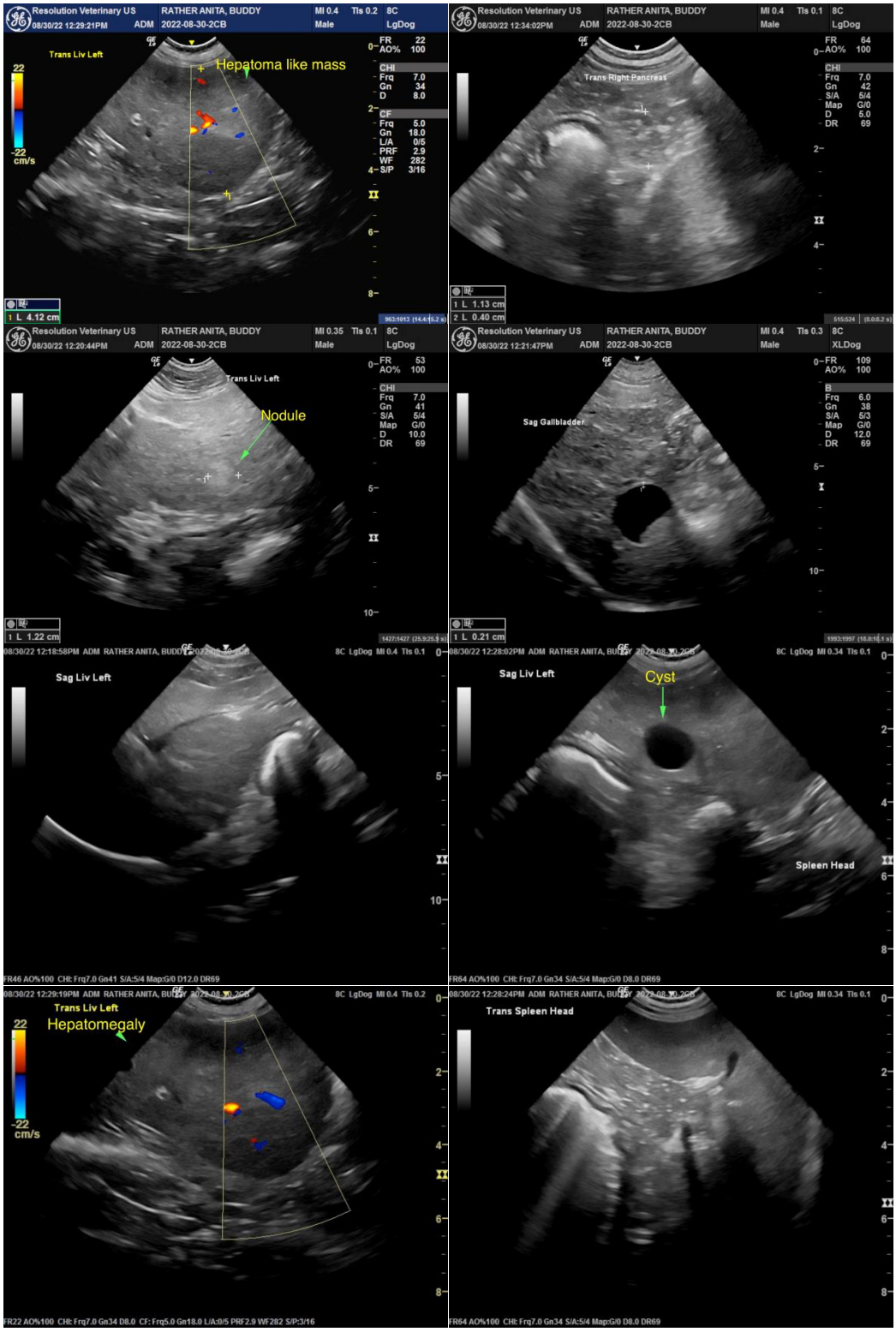

SonoPath

Clinical Sonography & Telecytology

EDUCATIONAL TELECONSULTATION SERVICES™

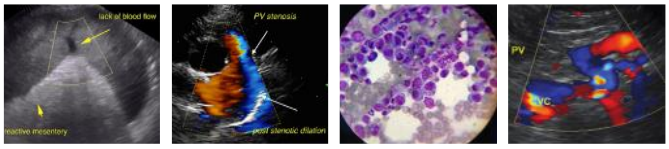

SonoPath.com™
1-800-838-4268 info@sonopath.com

PATIENT

Buddy Rather

SPECIES

Canine

BREED

Golden Retriever

SEX

MN

AGE

13

WEIGHT

34 kg

INTERPRETED BY

R. McKenzie Daniel, DVM, DABVP (Canine and Feline)

IMAGING PERFORMED BY

Dr. Belan

HOSPITAL NAME

Bowmont AH

REFERRING VET

Dr. Asemadahun

INVOICE

14761

DATE

8/30/22

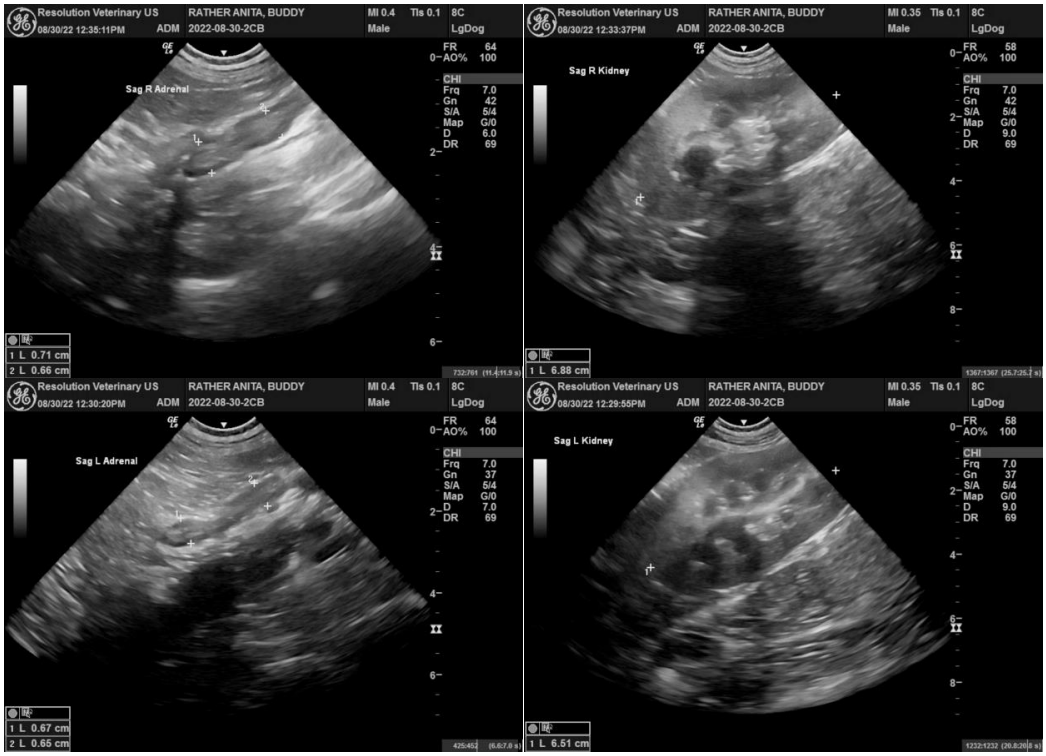

The information and recommendations provided are based on the images presented by the referring veterinarian/sonographer. No evaluation can be communicated regarding pathology that was not visible in the image/video clips provided.

Thank you for this referral. If the clinical or image interpretation does not parallel your findings or if I can be of any further assistance please contact me.

R. McKenzie Daniel, DVM, DABVP (Canine / Feline Practice)
info@SonoPath.com