

PATIENT PRESENTING CLINICAL SIGNS

Penny Martin Plan surgery to remove skin masses. Preop blood work revealed ALP 253.

SPECIES ULTRASONOGRAPHIC EXAMINATION OF THE ABDOMEN

Canine

Urinary System

The urinary bladder, trigone, cystourethral junction, and visible pelvic urethra to a depth of 2.0 cm exhibited normal thickness and tone. Anechoic urine was present in the lumen with no uroliths or sediment. The ureteral papillae were normal. The ureters were not visible which is normal. No evidence of inflammatory or neoplastic changes were noted.

BREED

Pug

Normal size and margination was present in the kidneys. A normal 1:3 cortex / medulla ratio was maintained. The medulla and cortices were uniform in texture with some increased echogenicity and loss of corticomedullary symmetry and definition expected for the age of the patient. No evidence of pelvic dilation was present. The left kidney measured 4.3 cm. The right kidney measured 4.45 cm.

SEX

Spayed Female

The area of the aortic trifurcation was free of pathology.

AGE

13 Years

Adrenal Glands

The adrenal glands were uniform in size and contour with a uniformly hypoechoic parenchyma. The left adrenal gland measured 0.40 cm at the cranial pole and 0.38 cm at the caudal pole.

WEIGHT

30.5 Pounds

A focal, well defined, hyperechoic nodule measuring 1.2 cm length x 0.77 cm in width was present in the right adrenal gland with mild associated symmetrical capsule expansion. The overall right adrenal gland measured 1.7 cm length x 0.82 cm mid adrenal width and 0.55 cm at the caudal pole. The nodule did not exhibit signs of mineralization or vascular invasion. This is likely suggestive of a benign process such as adenoma, granuloma or myelolipoma if no clinical signs of adrenal disease are currently present. Potential emerging aggressive neoplasia cannot be ruled out. Therefore, recheck ultrasound every 3-6 months is suggested to monitor for changes in size or appearance. A screening blood pressure is suggested.

INTERPRETED BY

R. McKenzie Daniel, DVM,
DABVP (Canine and Feline)

Spleen

The spleen exhibited a finely textured and homogenous parenchyma which was hyperechoic to the liver and renal cortical parenchyma. The capsule was smooth and regular without apparent expansion. The splenic vasculature at the hilus was normal in volume with no evidence of congestion or thrombosis. Acute to chronic inflammatory, neoplastic, or benign parenchyma changes were not noted.

IMAGING PERFORMED BY

Pamela Harrigan, RDCS

Liver

The liver was subjectively normal in size, structure, and contour. The liver parenchyma was mildly nonuniform and hypoechoic to the spleen with a moderate coarse echotexture and subjective mild to benign parenchymal remodeling. Subtle intermittent, non-expansive, hypoechoic nodular changes were present. Example of nodule measured 1.6 cm diameter. The hepatic and portal vasculature were normal in appearance without signs of congestion. The gallbladder was non distended in size with mild, echogenic, nonmineralized biliary sludge. The cystic duct and common bile ducts were normal without evidence of dilation.

HOSPITAL NAME

VCA Palmer AH

REFERRING VET

Dr. Michelle Haroules

INVOICE

25070

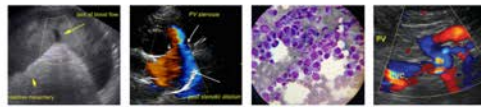
Gastrointestinal

The stomach presented intact wall layering with a normal wall layer ratio. The lumen of the stomach was empty with no signs of ileus, obstruction or foreign material.

DATE

8/30/21

The small intestine presented intact wall layering with 1:3 muscularis/mucosa ratio. The lumen of the small intestine was empty with no signs of ileus, obstruction or foreign material.



PATIENT

Normal visible colon wall layers were present with apparent formed feces in lumen.

Penny Martin

Pancreas

SPECIES

The parenchyma of the left limb, body and right limb of the pancreas presented isoechoic to the adjacent omental fat. A normal curvilinear capsule contour of the pancreas was present. The visible pancreatic duct was normal. No signs of active inflammation or neoplastic disease was evident.

Canine

ULTRASONOGRAPHIC FINDINGS

BREED

- Hepatic parenchymal remodeling with subtle intermittent parenchymal nodules
- Mild gallbladder debris (non-mucocele)
- Right adrenal nodule – suspect adenoma
- Mild age related kidneys

Pug

SEX

INTERPRETATION OF THE FINDINGS & FURTHER RECOMMENDATIONS

Spayed Female

The overall appearance of the liver was non-specific with considerations including vacuolar hepatitis, chronic active hepatitis, cholangiohepatitis (given the presence of minor concurrent gallbladder debris) with hepatic parenchymal remodeling and subtle areas of nodular to regenerative hyperplasia or hematopoiesis, early fibrosis, cirrhosis, or other hepatopathy. Neoplasia is considered a less likely differential diagnosis.

AGE

13 Years

The right adrenal nodule is non-specific, yet suspected to be an adenoma. However, the possibility of emerging right adrenal neoplasia such as pheochromocytoma or adenocarcinoma cannot be excluded. Screening blood pressure is suggested. Sonographic monitoring of the right adrenal nodule for evidence of progression with initial recheck in 4 weeks is suggested. No overt anesthetic contraindications assuming normal albumin, glucose, cholesterol and BUN levels. Hepatosupportive medications including Ursodiol may prove beneficial.

WEIGHT

30.5 Pounds

INTERPRETED BY

R. McKenzie Daniel, DVM,
 DABVP (Canine and Feline)

IMAGING PERFORMED BY

Pamela Harrigan, RDCS

HOSPITAL NAME

VCA Palmer AH

REFERRING VET

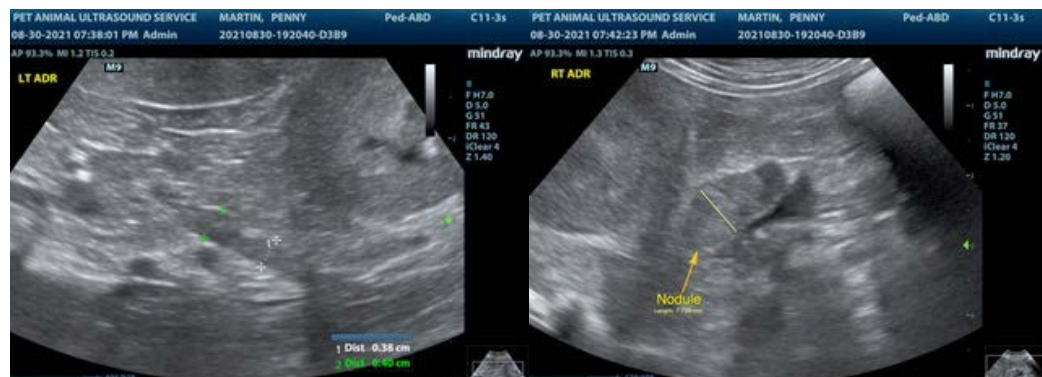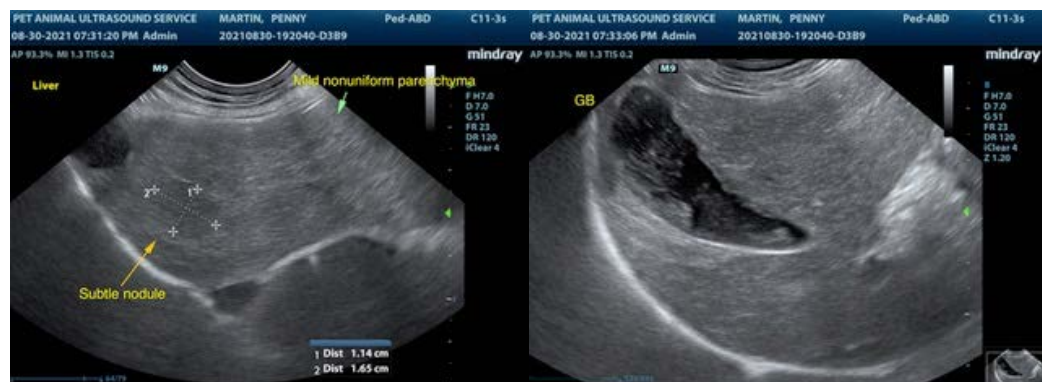
Dr. Michelle Haroules

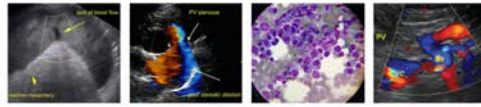
INVOICE

25070

DATE

8/30/21





PATIENT

Penny Martin

SPECIES

Canine

BREED

Pug

SEX

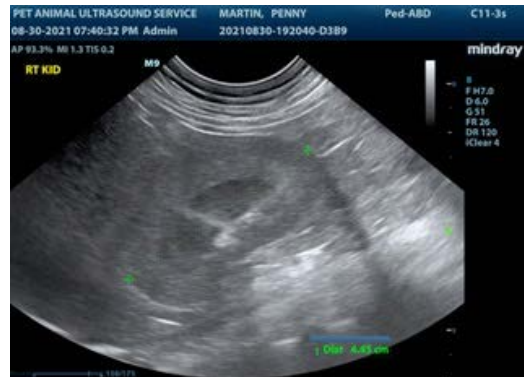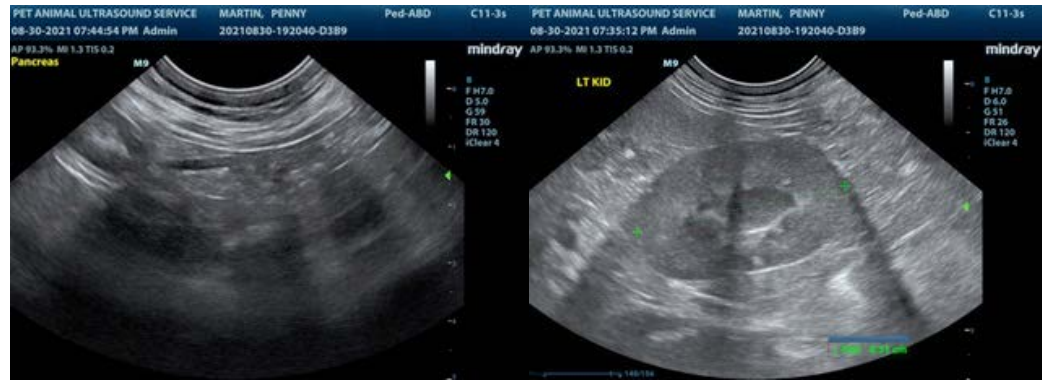
Spayed Female

AGE

13 Years

WEIGHT

30.5 Pounds



INTERPRETED BY

R. McKenzie Daniel, DVM,
 DABVP (Canine and Feline)

IMAGING PERFORMED BY

Pamela Harrigan, RDCS

HOSPITAL NAME

VCA Palmer AH

REFERRING VET

Dr. Michelle Haroules

INVOICE

25070

DATE

8/30/21

The information and recommendations provided are based on the images presented by the referring veterinarian. No evaluation can be communicated regarding pathology that was not visible in the image/video clips provided.

Thank you for this referral. If the clinical or image interpretation does not parallel your findings or if I can be of any further assistance please contact me.

R. McKenzie Daniel, DVM, DABVP (Canine / Feline Practice)
 info@SonoPath.com