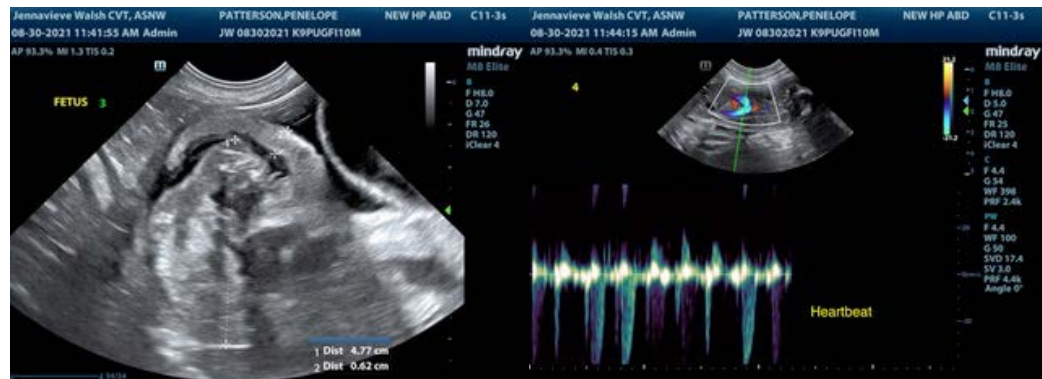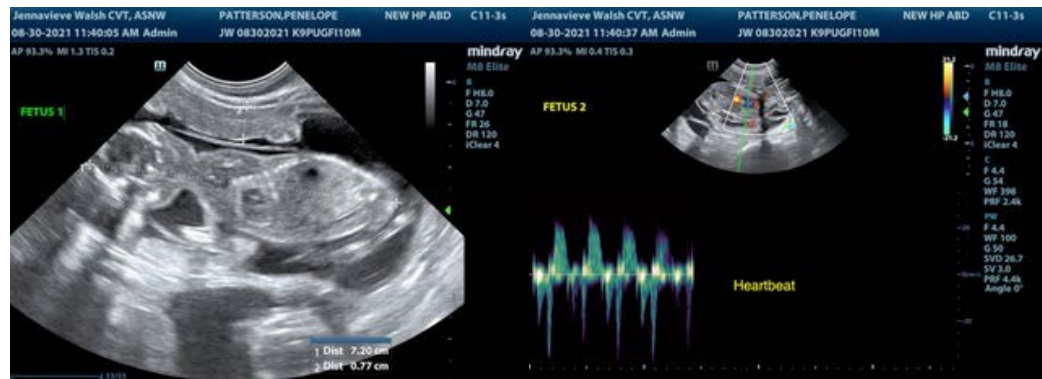




PATIENT	PRESENTING CLINICAL SIGNS
Penelope Patterson	Suspected pregnancy, 47days along. Unintended pregnancy.
SPECIES	LIMITED ULTRASONOGRAPHIC EXAMINATION
Canine	Sonographic assessment of the abdominal cavity and uterus revealed an estimated 4 viable fetuses exhibiting evidence of skeletal mineralization and subjective normal heart rates. The uterus was sonographically unremarkable in light of pregnancy. The visible bladder was normal with minor particulate sediment. The surrounding structures adjacent to the uterus including the small intestine were sonographically unremarkable.
BREED	
Pug	
SEX	ULTRASONOGRAPHIC FINDINGS
Female	<ul style="list-style-type: none"> Confirmed pregnancy – estimate 4 viable fetuses
AGE	INTERPRETATION OF THE FINDINGS & FURTHER RECOMMENDATIONS
10 Months	Radiographic assessment for more accurate count of the fetuses is recommended prior to parturition.
WEIGHT	
17.6	
INTERPRETED BY	
R. McKenzie Daniel, DVM, DABVP (Canine and Feline)	
IMAGING PERFORMED BY	
Jenna Walsh	
HOSPITAL NAME	
The Ark Vet Clinic	
REFERRING VET	
Dr. Sangl	
INVOICE	
25058	
DATE	
8/30/21	





PATIENT

Penelope Patterson

The information and recommendations provided are based on the images presented by the referring veterinarian. No evaluation can be communicated regarding pathology that was not visible in the image/video clips provided.

SPECIES

Canine

Thank you for this referral. If the clinical or image interpretation does not parallel your findings or if I can be of any further assistance please contact me.

BREED

Pug

R. McKenzie Daniel, DVM, DABVP (Canine / Feline Practice)
info@SonoPath.com

SEX

Female

AGE

10 Months

WEIGHT

17.6

INTERPRETED BY

R. McKenzie Daniel,
DVM, DABVP
(Canine and Feline)

**IMAGING
PERFORMED BY**

Jenna Walsh

HOSPITAL NAME

The Ark Vet Clinic

REFERRING VET

Dr. Sangl

INVOICE

25058

DATE

8/30/21