PAUS
Pet Animal Ultrasound Service

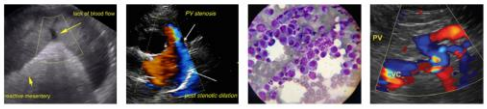

SonoPath
Clinical Sonography & Telecytology
EDUCATIONAL TELECONSULTATION SERVICES™
1-800-838-4268 info@sonopath.com SonoPath.com

PATIENT

Puma DaSilva

SPECIES

Feline

BREED

DMH

SEX

MN

AGE

12 years

WEIGHT

13.4 lbs.

INTERPRETED BY
R. McKenzie Daniel, DVM, DABVP (Canine and Feline)

IMAGING PERFORMED BY
Pamela Harrigan, RDCS

HOSPITAL NAME

Norfolk County Veterinary Service

REFERRING VET

Aurora Richards, DVM

INVOICE

14799

DATE

8/3/23

PRESENTING CLINICAL SIGNS

Off and on constipation, signs of asthma, weight loss. T4-3.4.

ULTRASONOGRAPHIC EXAMINATION OF THE ABDOMEN

Urinary System

The urinary bladder, trigone, cystourethral junction, and visible pelvic urethra to a depth of 2.0 cm exhibited normal thickness and tone. Anechoic urine was present in the lumen with no uroliths or sediment. The ureteral papillae were normal. The ureters were not visible which is normal. No evidence of inflammatory or neoplastic changes was noted.

The area of the aortic trifurcation was free of pathology.

The bilateral kidneys were enlarged in size, compared to normal renal size for felines, and exhibited symmetrical capsule contour. A 1:3 cortex/medulla ratio was maintained with mild uniform cortical hypertrophy and mildly enhanced corticomedullary border demarcation. Normal medullary volume was present. The left kidney measured 5.0 cm in length. The right kidney measured 5.0 cm in length.

Adrenal Glands

The left and right adrenal glands exhibited subjective borderline prominent size with maintained symmetrical capsule contour and mild nonhomogeneous parenchyma. The left adrenal gland measured 0.49 cm width and the right adrenal gland measured 0.57 cm width.

Spleen

The spleen exhibited subjective mild enlargement with a finely textured and homogenous parenchyma which was hyperechoic to the liver and renal cortical parenchyma. The capsule was smooth and regular without apparent expansion. The splenic vasculature at the hilus was normal in volume with no evidence of congestion or thrombosis. Acute to chronic inflammatory, neoplastic, or benign parenchyma changes were not noted. The spleen measured 1.1-1.2 cm width at the level of the mid spleen.

Liver/ Gallbladder

The liver presented generalized enlargement with prominent hepatic vasculature, consistent with mild congestion. The parenchyma of the liver was subjectively increased in echogenicity compared to the spleen and renal cortices. The echotexture of the liver parenchyma was uniform with a mild coarse echotexture. The capsule of the liver was symmetrical in margination. The gallbladder was non-distended in size containing primarily anechoic content with mild gallbladder sediment. The cystic and common bile ducts were normal.

Gastrointestinal

The stomach presented intact wall layering with a normal wall layer ratio. The lumen of the stomach was empty with no signs of ileus, obstruction, or foreign material.

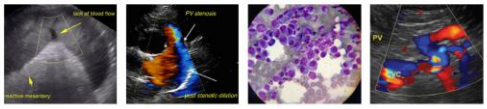

PATIENT

Puma DaSilva

SPECIES

Feline

BREED

DMH

SEX

MN

AGE

12 years

WEIGHT

13.4 lbs.

INTERPRETED BY
R. McKenzie Daniel, DVM, DABVP (Canine and Feline)

IMAGING PERFORMED BY
Pamela Harrigan, RDCS

HOSPITAL NAME

Norfolk County Veterinary Service

REFERRING VET

Aurora Richards, DVM

INVOICE

14799

DATE

8/3/23

The small intestine presented generalized intact, mildly prominent wall layering owing to a propensity for mildly prominent intestinal mucosa. The duodenum wall measured 0.34 cm width. The jejunum wall measured 0.27 cm width. The ileocolic wall measured 0.35 cm width.

Overtly normal visible colon wall layers and normal size were present without evidence of colonic distention with formed fecal matter.

Pancreas

The pancreas was mildly prominent in size exhibiting symmetrical capsule contour and uniform mildly hypoechoic parenchyma with minor pancreatic duct dilation.

Free Abdomen

Intermittent scant pocket of peritoneal free fluid was present. There was no overt or significant omental lymphadenopathy or evidence of omental masses.

ULTRASONOGRAPHIC FINDINGS

- Hepatomegaly exhibiting uniform parenchyma hyperechogenicity and subjective hepatic vascular congestion - nonspecific hepatitis / cholangiohepatitis, lipidosis, vacuolar hepatic changes, round cell neoplasia, possible
- Mild gallbladder sediment
- Mild splenomegaly - incidental hyperplasia, hematopoiesis, splenitis, early round cell neoplasia, possible
- Bilateral mild renomegaly
- Subjective borderline prominent bilateral adrenal glands
- Intact borderline thickened small bowel wall
- Sonographically unremarkable colon
- Possible low-grade pancreatitis
- Intermittent scant peritoneal free fluid

INTERPRETATION OF THE FINDINGS & FURTHER RECOMMENDATIONS

Assuming normal clotting status and using a 25-gauge needle, vitamin K pretreatment and screening hepatosplenic FNA cytology is warranted for further clarification, given the patient's weight loss. A GI panel to include PLI/TLI/Cobalamin/Folate is recommended. Three-view chest radiographs are recommended if not done to rule out occult intrathoracic pathology as a contributing factor. Full urinalysis +/- screening C/S or baseline UPC level, if clinically indicated, may be considered.

Although no reported hyperglycemia, fructosamine level and monitoring for clinical signs suggestive of diabetes going forward may be considered. Likewise, Triaditis could be possible in this patient if evidence of hepatic inflammatory criteria on recommended cytology, which is required for further clarification.

PAUS
Pet Animal Ultrasound Service

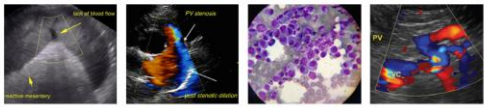

SonoPath
Clinical Sonography & Telecytology
EDUCATIONAL TELECONSULTATION SERVICES™
1-800-838-4268 info@sonopath.com SonoPath.com

PATIENT

Puma DaSilva

SPECIES

Feline

BREED

DMH

SEX

MN

AGE

12 years

WEIGHT

13.4 lbs.

INTERPRETED BY
R. McKenzie Daniel, DVM, DABVP (Canine and Feline)

IMAGING PERFORMED BY
Pamela Harrigan, RDCS

HOSPITAL NAME

Norfolk County Veterinary Service

REFERRING VET

Aurora Richards, DVM

INVOICE

14799

DATE

8/3/23

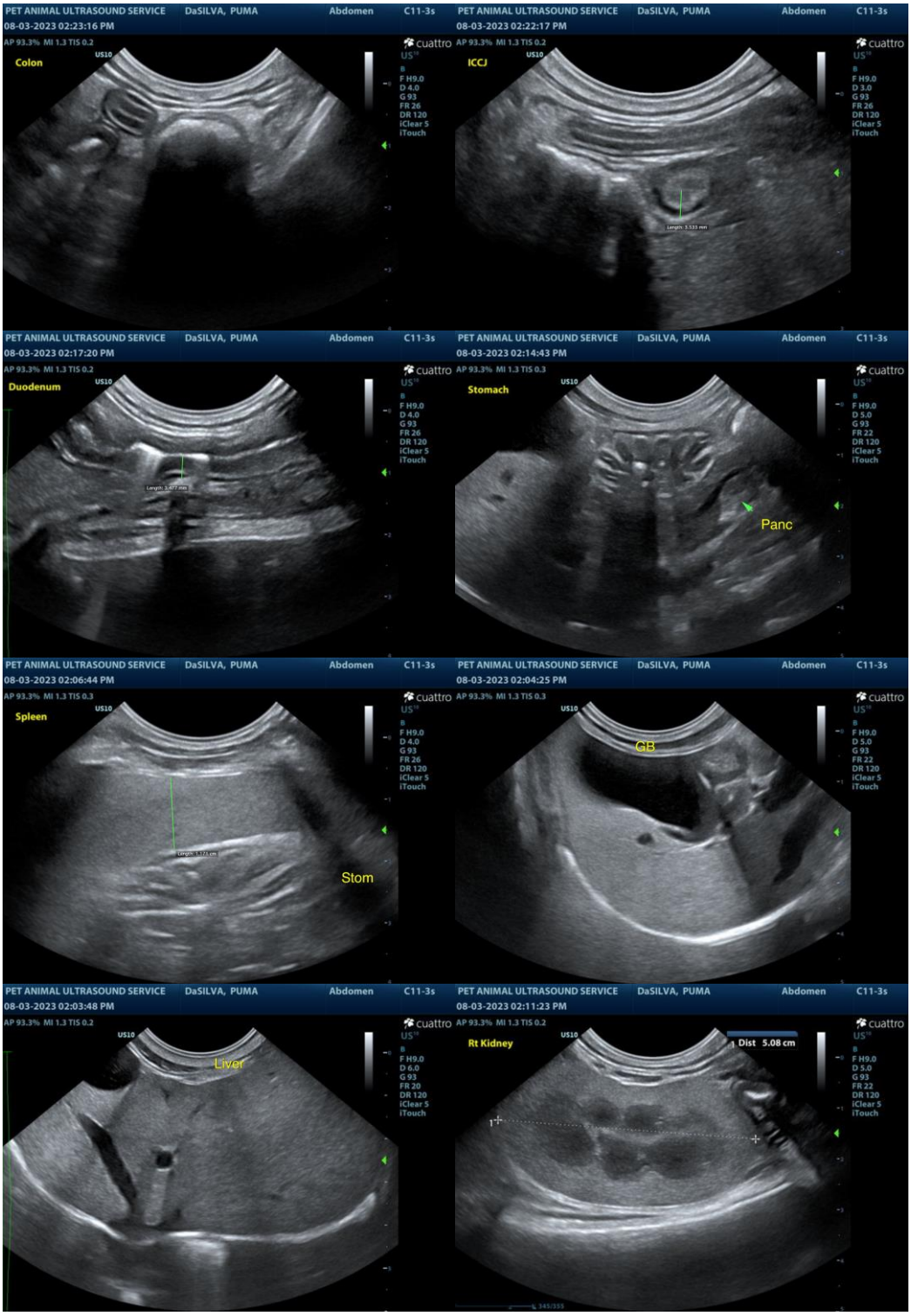

PAUS
Pet Animal Ultrasound Service

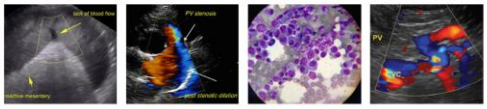

SonoPath
Clinical Sonography & Telecytology
EDUCATIONAL TELECONSULTATION SERVICES™
1-800-838-4268 info@sonopath.com SonoPath.com

PATIENT

Puma DaSilva

SPECIES

Feline

BREED

DMH

SEX

MN

AGE

12 years

WEIGHT

13.4 lbs.

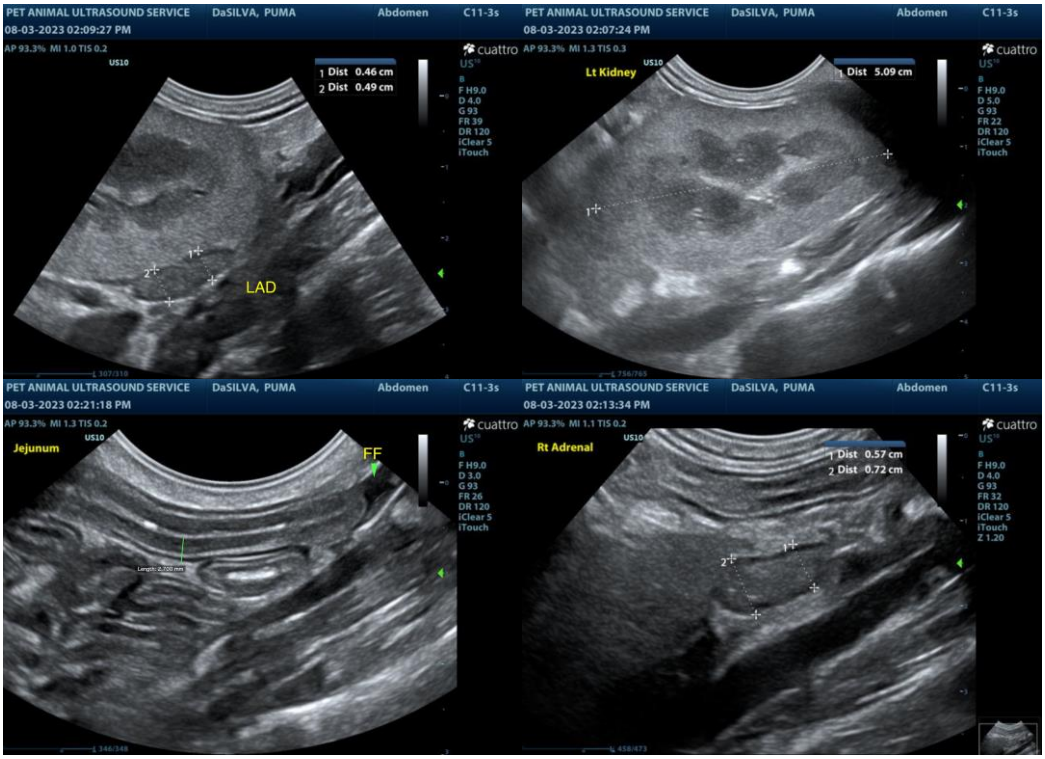

INTERPRETED BY
R. McKenzie Daniel, DVM, DABVP (Canine and Feline)

IMAGING PERFORMED BY
Pamela Harrigan, RDCS

HOSPITAL NAME

Norfolk County Veterinary Service

REFERRING VET

Aurora Richards, DVM

INVOICE

14799

DATE

8/3/23

The information and recommendations provided are based on the images presented by the referring veterinarian/sonographer. No evaluation can be communicated regarding pathology that was not visible in the image/video clips provided.

Thank you for this referral. If the clinical or image interpretation does not parallel your findings or if I can be of any further assistance please contact me.

R. McKenzie Daniel, DVM, DABVP (Canine / Feline Practice)
info@SonoPath.com