



PATIENT PRESENTING CLINICAL SIGNS

Mabel Biggie Inappropriate urination; PD.
 Abnormal PE/Chem/CBC/UA Results: ALT 328; ALP 235; GGTP 89; Chol 1111, Trig 1495

SPECIES ULTRASONOGRAPHIC EXAMINATION OF THE ABDOMEN

Canine *Urinary System*

The urinary bladder, trigone, cystourethral junction, and visible pelvic urethra to a depth of 3.0 cm exhibited normal thickness and tone. Anechoic urine was present in the lumen with no uroliths or sediment. The ureteral papillae were normal. The ureters were not visible which is normal. No evidence of inflammatory or neoplastic changes were noted.

BREED

Boston Terrier

No evidence of pathology in the area of the aortic trifurcation.

SEX

FS

Normal size and margination was present in the kidneys. A normal 1:3 cortex / medulla ratio was maintained. The medulla and cortices were uniform in texture with some increased echogenicity and mild to moderate loss of corticomedullary symmetry and definition expected for the age of the patient. No evidence of pyelectasia or overt pyelonephritis was present. Pinpoint medullary mineralization was present. The left kidney measured 5.4 cm in length. The right kidney measured 5.9 cm in length.

AGE

13 Years

Adrenal Glands

WEIGHT

26 lbs

The bilateral adrenal glands exhibited subjective prominent size. Mild parenchyma heterogeneity and mild capsule asymmetry was present without suspicion for overt neoplasia. The left adrenal gland measured 0.81 cm width in the cranial pole and 0.80 cm width in the caudal pole. The right adrenal gland measured 0.84 cm width mid adrenal x 0.59 cm width in the caudal pole. No evidence of adrenal masses.

INTERPRETED BY

Spleen

R. McKenzie Daniel, DVM,
 DABVP (Canine and
 Feline)

The spleen exhibited primarily finely textured parenchyma which was hyperechoic to the liver and renal cortical parenchyma. Pinpoint hyperechoic splenic foci, which although nonspecific, may indicate pinpoint areas of microinfarction, mineralization, or fibrosis; this is a benign finding. Mild generalized parenchyma heterogeneity was present without evidence of nodular changes. The capsule was smooth and regular without apparent expansion. The splenic vasculature at the hilus was normal in volume with no evidence of congestion or thrombosis. The parenchymal heterogeneity is likely consistent with benign changes such as extramedullary hematopoiesis or age related remodeling with minor potential for inflammatory or neoplastic disease.

IMAGING PERFORMED BY

Pamela Harrigan, RDCS

HOSPITAL NAME

Liver

Pine Banks Animal
 Hospital

The liver exhibited subjective mild generalized enlargement. The liver parenchyma was mildly nonuniform and hypoechoic to the spleen with a moderate coarse echotexture and subjective mild to benign parenchymal remodeling. The hepatic and portal vasculature were normal in appearance without signs of congestion.

REFERRING VET

Hasan Syed, DVM

The gallbladder was non distended in size with moderate mildly congealed yet nonorganized gallbladder debris primarily in the mid to caudal lumen and cystic biliary duct. The debris was nonmineralized. The common bile duct was normal without evidence of dilation.

INVOICE

Gastrointestinal

47175

The stomach presented intact wall layering with a normal wall layer ratio. The lumen of the stomach was empty with no signs of ileus, obstruction or foreign material.

DATE

8-29-21



PATIENT

Mabel Biggie

The small intestine presented intact wall layering with 1:3 muscularis/mucosa ratio. The lumen of the small intestine was empty with no signs of ileus, obstruction, or foreign material.

Normal visible colon wall layers were present with apparent formed feces in lumen.

SPECIES

Canine

Pancreas

The parenchyma of the left limb, body and right limb of the pancreas presented isoechoic to the adjacent omental fat. A normal curvilinear capsule contour of the pancreas was present. The visible pancreatic duct was normal. No signs of active inflammation or neoplastic disease was evident.

BREED

Boston Terrier

Free Abdomen

No overt lymphadenopathy or peritoneal effusion was present.

SEX

FS

ULTRASONOGRAPHIC FINDINGS

- Mild to moderate chronic renal changes with pinpoint medullary mineralization.
- Hepatopathy - subjectively chronic.
- Moderate gallbladder debris (non-mucocele).
- Heterogeneous subjectively prominent bilateral adrenal glands.

AGE

13 Years

WEIGHT

26 lbs

INTERPRETATION OF THE FINDINGS & FURTHER RECOMMENDATIONS

Full adrenal workup which may include LDDST suggested if clinically indicated in light of the patient's clinical signs and hyperlipidemia. Alternatively, screening UCCR may be considered and if elevated followed by LDDST. Additional diagnostics may include urine culture and sensitivity +/- baseline UPC level and leptospirosis titers/pcr.

INTERPRETED BY

R. McKenzie Daniel, DVM,
DABVP (Canine and
Feline)

Hepatosupportive medications including denamarin and ursodiol may prove beneficial. Fasting triglyceride and cholesterol levels may be indicated if persistent.

**IMAGING
PERFORMED BY**

Pamela Harrigan, RDMS

HOSPITAL NAME

Pine Banks Animal
Hospital

REFERRING VET

Hasan Syed, DVM

INVOICE

47175

DATE

8-29-21



PATIENT

Mabel Biggie

SPECIES

Canine

BREED

Boston Terrier

SEX

FS

AGE

13 Years

WEIGHT

26 lbs

INTERPRETED BY

R. McKenzie Daniel, DVM,
 DABVP (Canine and Feline)

IMAGING PERFORMED BY

Pamela Harrigan, RDCS

HOSPITAL NAME

Pine Banks Animal Hospital

REFERRING VET

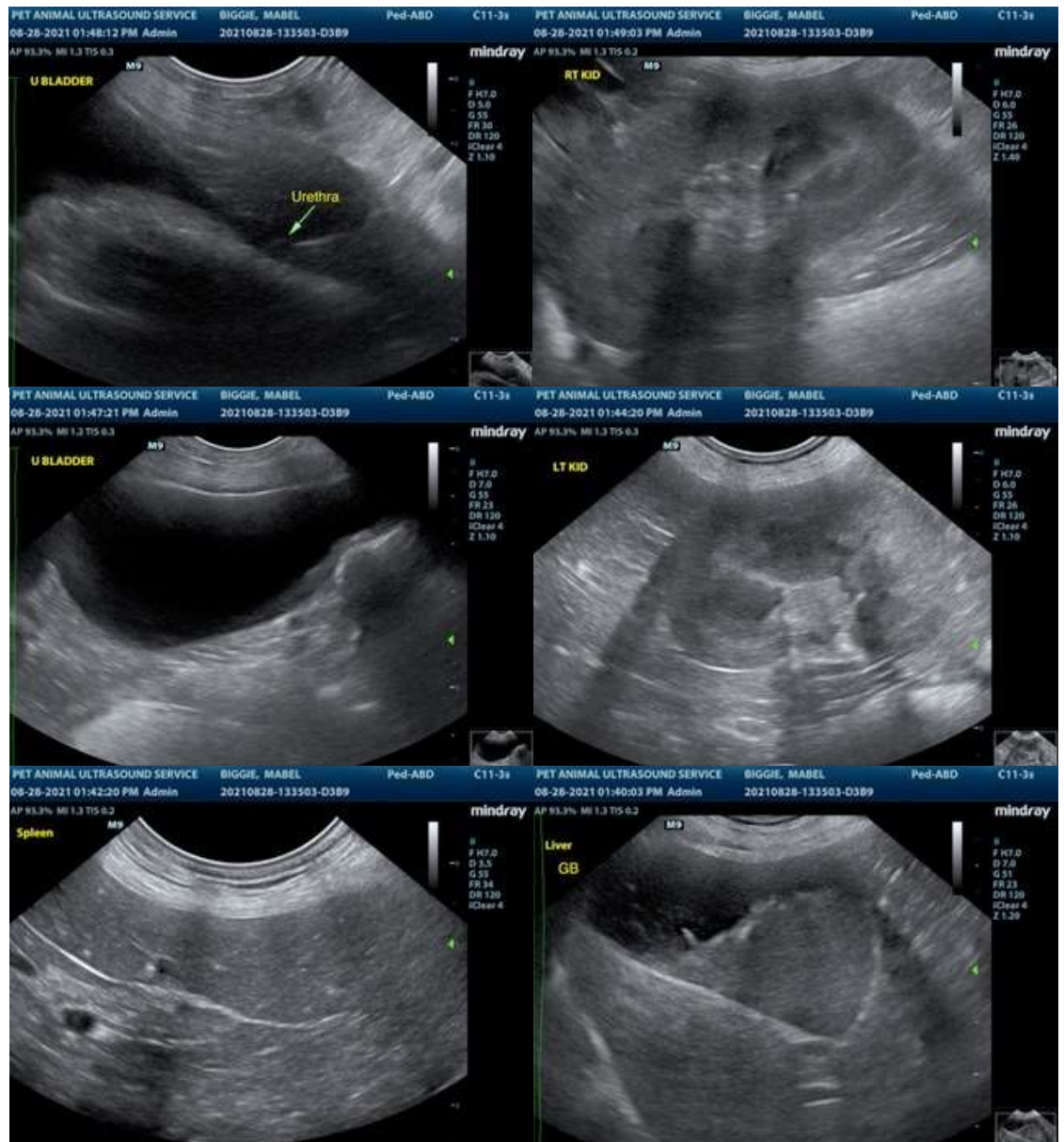
Hasan Syed, DVM

INVOICE

47175

DATE

8-29-21





PATIENT

Mabel Biggie

SPECIES

Canine

BREED

Boston Terrier

SEX

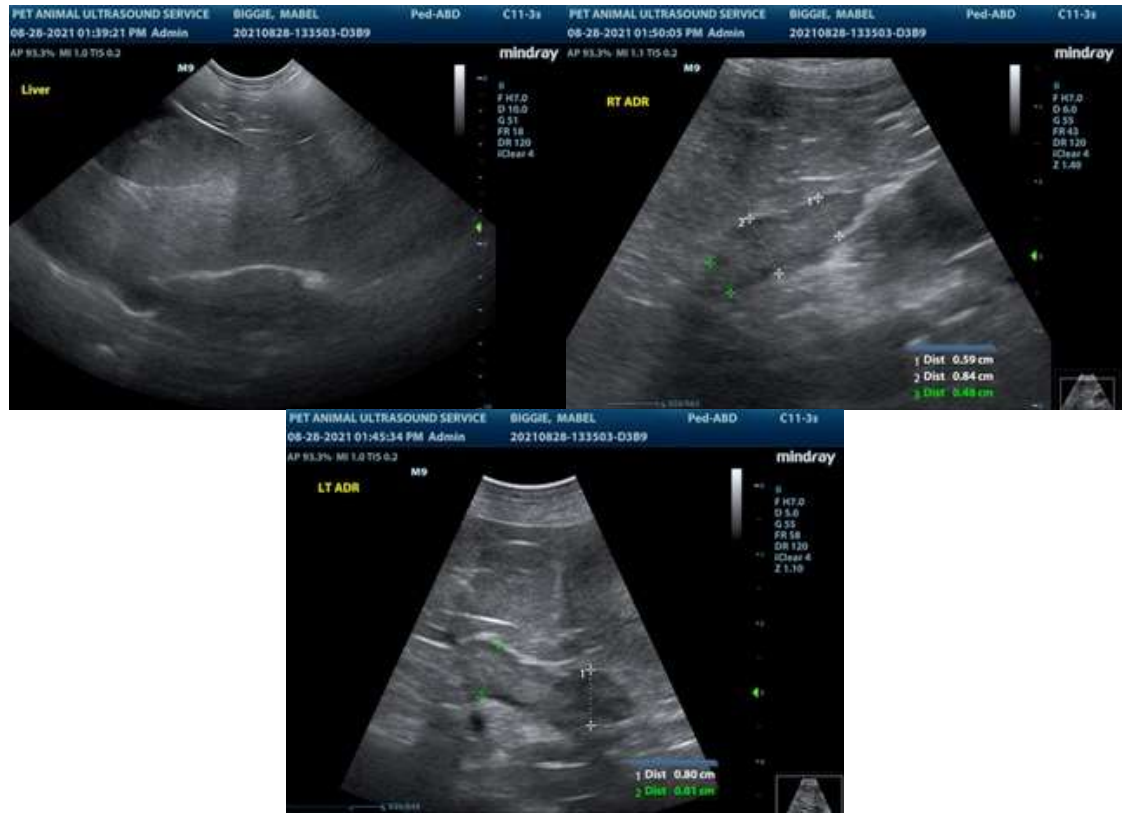FS

AGE

13 Years

WEIGHT

26 lbs



INTERPRETED BY

R. McKenzie Daniel, DVM,
 DABVP (Canine and Feline)

IMAGING PERFORMED BY

Pamela Harrigan, RDCS

HOSPITAL NAME

Pine Banks Animal Hospital

REFERRING VET

Hasan Syed, DVM

INVOICE

47175

DATE

8-29-21

The information and recommendations provided are based on the images presented by the referring veterinarian. No evaluation can be communicated regarding pathology that was not visible in the image/video clips provided.

Thank you for this referral. If the clinical or image interpretation does not parallel your findings or if I can be of any further assistance please contact me.

R. McKenzie Daniel, DVM, DABVP (Canine / Feline Practice)
 info@SonoPath.com