Pennsylvania Mobile
VETERINARY ULTRASOUND SERVICES

IMAGING PERFORMED BY
PAMobileVet.com 443-794-4700

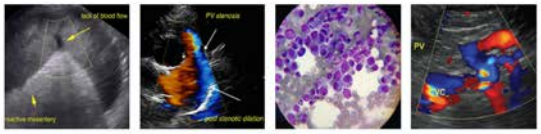

SonoPath
Clinical Sonography & Telecytology
EDUCATIONAL TELECONSULTATION SERVICES™
1-800-838-4268 info@sonopath.com SonoPath.com

PATIENT
Isabelle Cousins

SPECIES
Feline

BREED
Domestic Shorthair

SEX
FS

AGE
9 years

WEIGHT
12.2 Pounds

INTERPRETED BY
R. McKenzie Daniel, DVM, DABVP (Canine and Feline)

IMAGING PERFORMED BY
Rebekah Jakum, CVT ARDMS/RVT

HOSPITAL NAME
Lehigh Valley AH (Bath)

REFERRING VET
Dr. Tan

INVOICE
24923

DATE
8.25.2021

PRESENTING CLINICAL SIGNS

History: Chronic intermittent vomiting, elevated fPL

Medication: Cerenia, B12

Unremarkable CBC, BUN 40, Spec fPL 5.3, USG 1.044, 2+ protein, negative glucose.

ULTRASONOGRAPHIC EXAMINATION OF THE ABDOMEN

Urinary System

The urinary bladder, trigone, cystourethral junction, and visible pelvic urethra to a depth of 2.0 cm exhibited normal thickness and tone. Primarily anechoic urine was present in the lumen. Mild particulate, echogenic sediment was present without evidence of calculus formation. The ureteral papillae were normal. The ureters were not visible which is normal. No evidence of inflammatory or neoplastic mural changes were noted.

Normal size and margination were present in the left kidney. A normal 1:3 cortex / medulla ratio and normal corticomedullary definition were maintained. The echogenicity of the cortex was similar to or slightly less than normal liver parenchyma while the medulla echogenicity was hypoechoic to the cortex with no evidence of pelvic dilation. The left kidney measured 4.1 cm.

The right kidney was subnormal in size with moderate loss of corticomedullary demarcation. Maintained symmetrical renal margination. Minor pyelectasia noted. The right kidney measured 2.3 cm.

Adrenal Glands

The adrenal glands were uniform in size and contour with a uniformly hypoechoic parenchyma. The left adrenal gland measured 0.45 cm in width. The right adrenal gland measured 0.48 cm.

Spleen

The spleen exhibited a finely textured and homogenous parenchyma which was hyperechoic to the liver and renal cortical parenchyma. The capsule was smooth and regular without apparent expansion. The splenic vasculature at the hilus was normal in volume with no evidence of congestion or thrombosis. Acute to chronic inflammatory, neoplastic, or benign parenchyma changes were not noted.

Liver

The liver was subjectively normal in size, structure, and contour. The liver parenchyma was uniform and hypoechoic to the spleen with a mild coarse echotexture. The hepatic and portal vasculature were normal in appearance without signs of congestion. The gallbladder was non-distended in size with thin walls and primarily anechoic luminal content. The cystic and common bile ducts were normal.

Gastrointestinal

The stomach presented intact wall layering with a normal wall layer ratio. The lumen of the stomach was empty with no signs of ileus, obstruction or foreign material. Gastric body wall measured 0.26 cm. Pylorus wall measured 0.21 cm.

The small intestine presented intact wall layering with 1:3 muscularis/mucosa ratio. The lumen of the small intestine was empty with no signs of ileus, obstruction or foreign material. Duodenum wall measured 0.26 cm. Jejunum wall measured 0.24 cm.

Ileocolic wall measured 0.34 cm. Normal visible colon wall layers were present with apparent formed feces in lumen.

Pennsylvania Mobile
VETERINARY ULTRASOUND SERVICES
IMAGING PERFORMED BY
PAMobileVet.com 443-794-4700

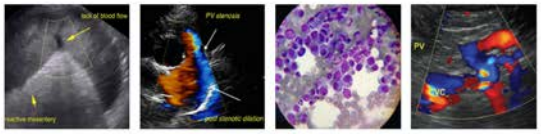

SonoPath
Clinical Sonography & Telecytology
EDUCATIONAL TELECONSULTATION SERVICES™
1-800-838-4268 info@sonopath.com SonoPath.com

PATIENT

Isabelle Cousins

SPECIES

Feline

BREED

Domestic Shorthair

SEX

FS

AGE

9 years

WEIGHT

12.2 Pounds

INTERPRETED BY

R. McKenzie Daniel, DVM, DABVP (Canine and Feline)

IMAGING PERFORMED BY

Rebekah Jakum, CVT ARDMS/RVT

HOSPITAL NAME

Lehigh Valley AH (Bath)

REFERRING VET

Dr. Tan

INVOICE

24923

DATE

8.25.2021

Pancreas

The pancreas was normal in size and contour with isoechoic to subtle heterogeneous parenchyma.

Free Abdomen

Minor colic lymphadenopathy adjacent to the ileocolic junction was present. These lymph nodes were subjectively reactive without evidence of inflammatory or neoplastic criteria.

ULTRASONOGRAPHIC FINDINGS

- Minor urinary bladder sediment
- Subnormal right kidney size with moderate chronic changes and mild pyelectasia
- Sonographically unremarkable gastrointestinal tract
- Subtly heterogeneous pancreas

INTERPRETATION OF THE FINDINGS & FURTHER RECOMMENDATIONS

The pyelectasia in the right kidney is likely owing to chronic renal changes or potential pelvic scarring. No overt indication of pyelonephritis. The urinary bladder sediment suggests mild cellular or crystalline debris. Further renal staging to include urine C/S and protein: creatinine ratio on sterile urine sample may be considered. Dietary intolerance/food hypersensitivity, occult parasitism (if the patient is indoor/outdoor), or underlying inflammatory gastroenteropathy without evidence of mural changes possible.

No sonographic evidence of active pancreatitis, although potential for low-grade chronic to chronic active pancreatitis (which may present sonographically normal) possible. In addition to current supportive care, as-needed gastroprotectants along with hydrolyzed diet trial may prove beneficial. Heartworm testing in this patient may be considered if not recently done, as cats with heartworm disease often exhibit chronic vomiting.

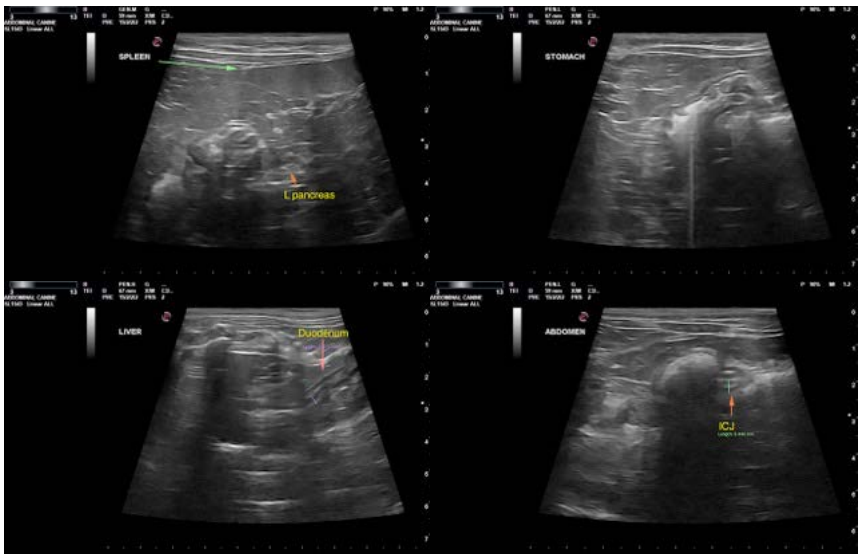

Pennsylvania Mobile
VETERINARY ULTRASOUND SERVICES

IMAGING PERFORMED BY
PAMobileVet.com 443-794-4700

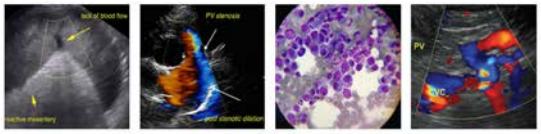

SonoPath
Clinical Sonography & Telecytology
EDUCATIONAL TELECONSULTATION SERVICES™
1-800-838-4268 info@sonopath.com SonoPath.com

PATIENT

Isabelle Cousins

SPECIES

Feline

BREED

Domestic Shorthair

SEX

FS

AGE

9 years

WEIGHT

12.2 Pounds

INTERPRETED BY

R. McKenzie Daniel, DVM, DABVP (Canine and Feline)

IMAGING PERFORMED BY

Rebekah Jakum, CVT ARDMS/RVT

HOSPITAL NAME

Lehigh Valley AH (Bath)

REFERRING VET

Dr. Tan

INVOICE

24923

DATE

8.25.2021

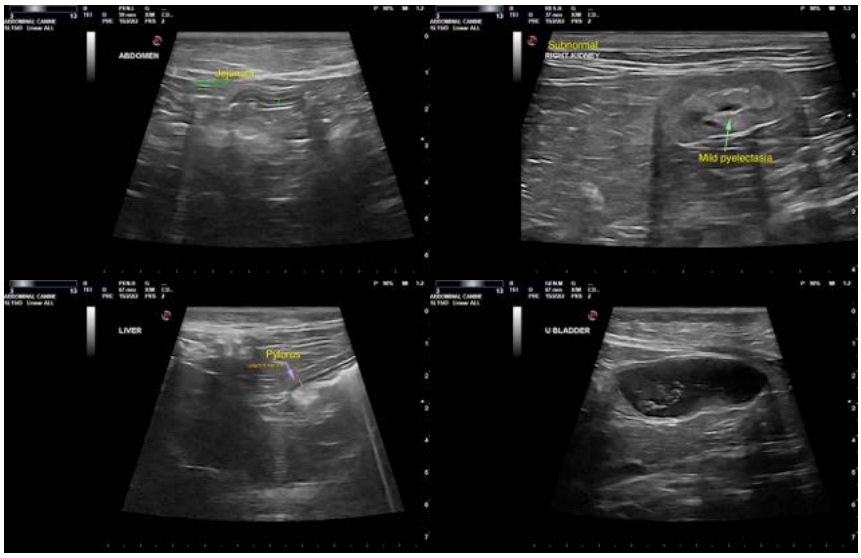

The information and recommendations provided are based on the images presented by the referring veterinarian. No evaluation can be communicated regarding pathology that was not visible in the image/video clips provided.

Thank you for this referral. If the clinical or image interpretation does not parallel your findings or if I can be of any further assistance please contact me.

R. McKenzie Daniel, DVM, DABVP (Canine/Feline Practice)
mac.daniel@sonopath.com